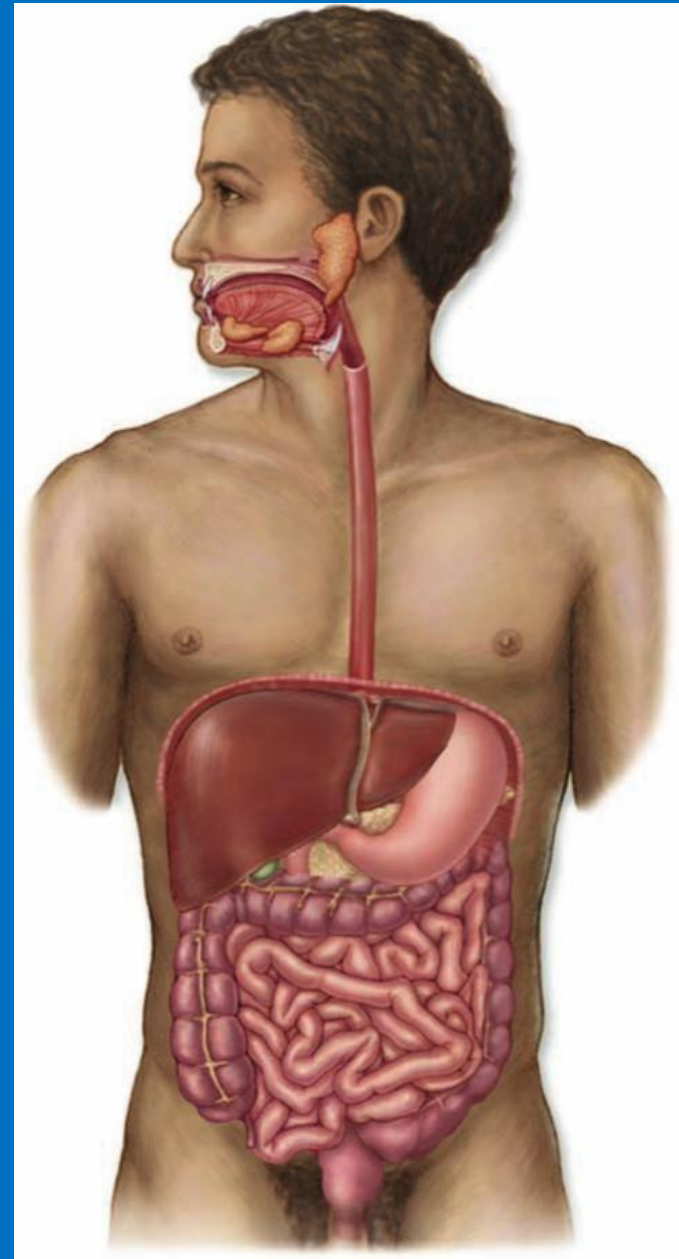


TRÁVICÍ SOUSTAVA

(Systema digestorium)



TRÁVICÍ SOUSTAVA

(Systema digestorium)

úvod

trávicí soustava (*systema digestorium*)

- ❑ ústní dutina (*cavum oris*)
- ❑ vlastní trávicí trubice (*canalis alimentarius*)
- ❑ velké žlázy

obecná stavba trávicí trubice

tunica mucosa

lamina epithelialis

lamina propria

lamina muscularis

tela submucosa

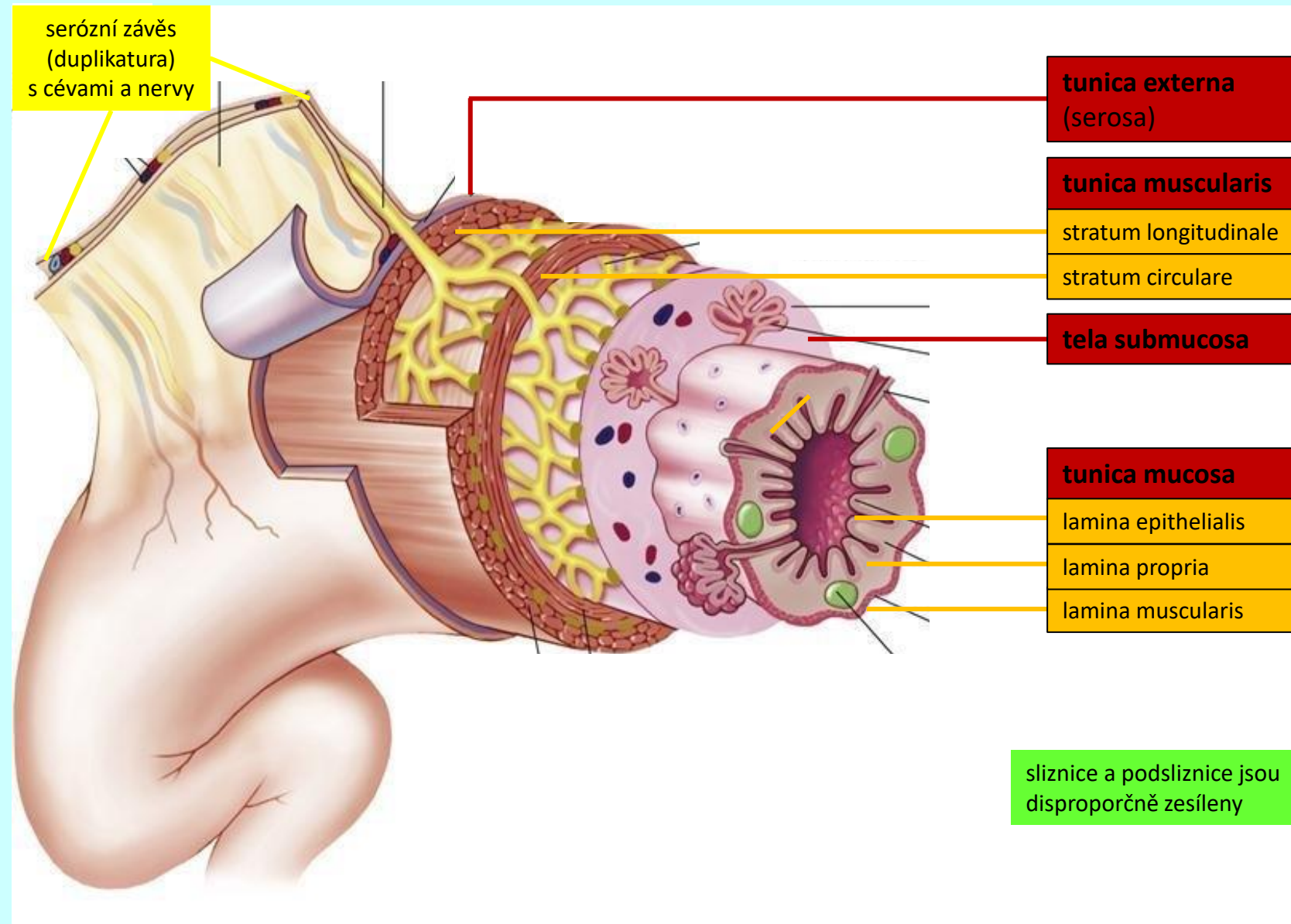
tunica muscularis

stratum circulare

stratum longitudinale

tunica externa

seróza × adventicie



obecná stavba trávicí trubice

tunica mucosa

lamina epithelialis

lamina propria

lamina muscularis

tela submucosa

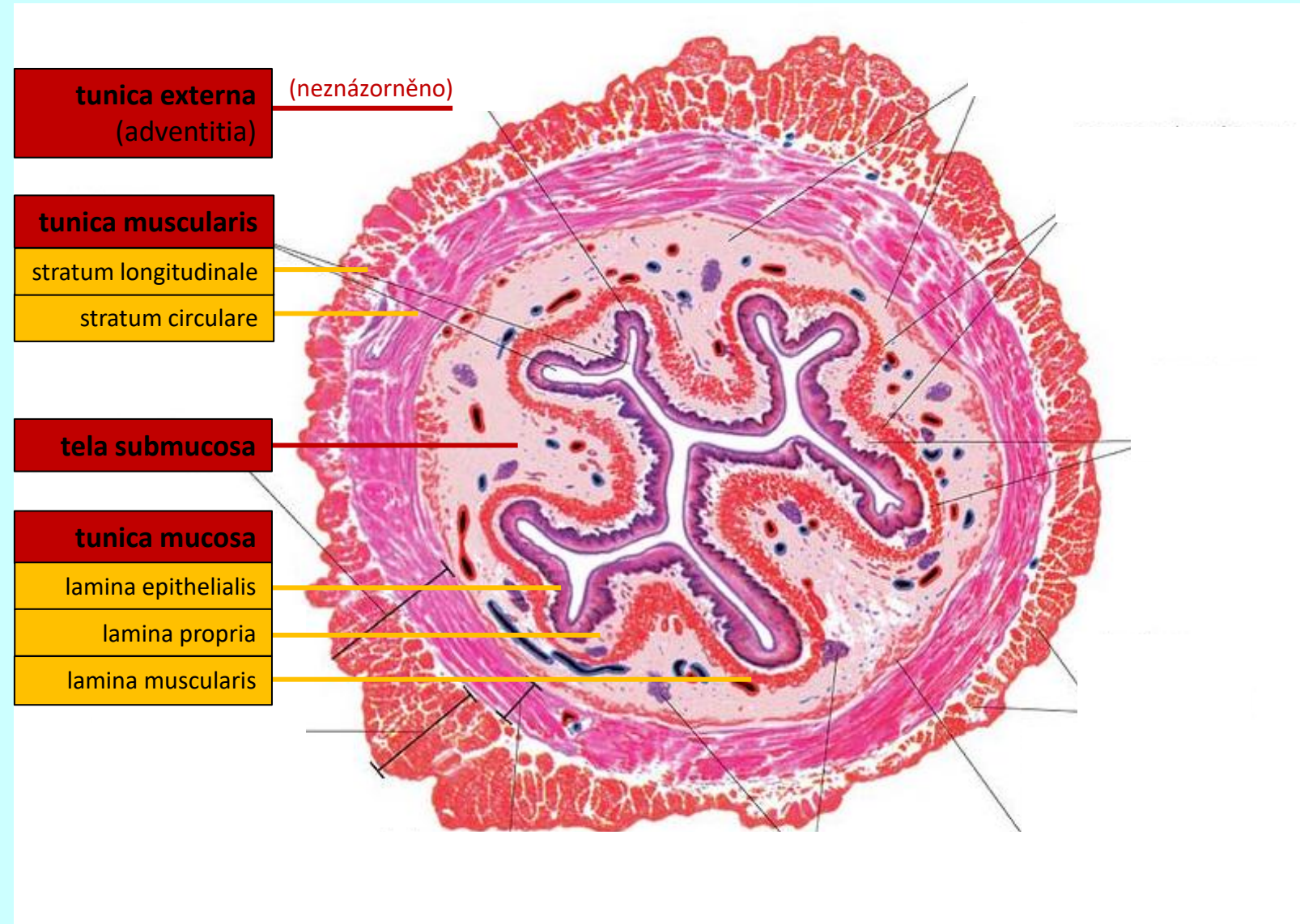
tunica muscularis

stratum circulare

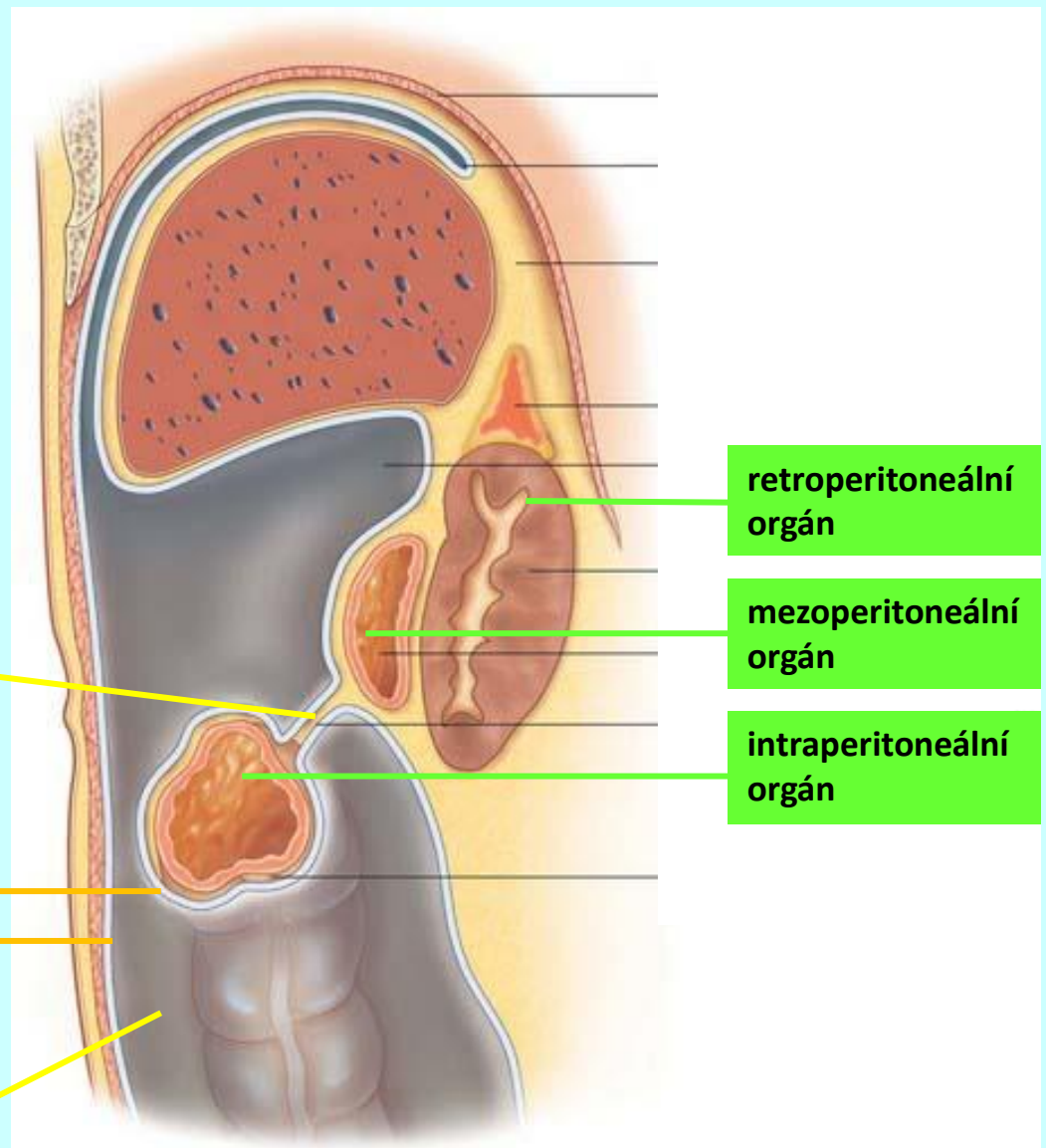
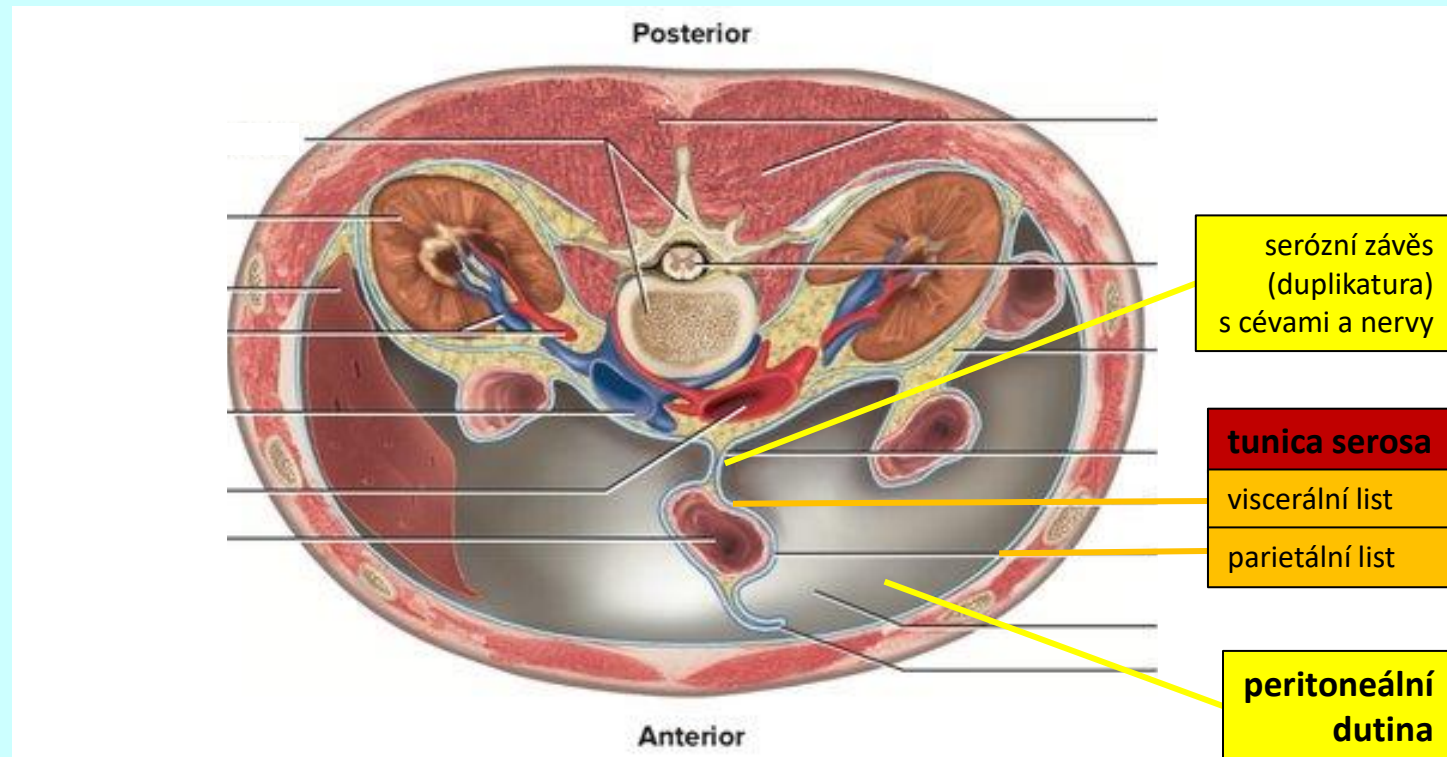
stratum longitudinale

tunica externa

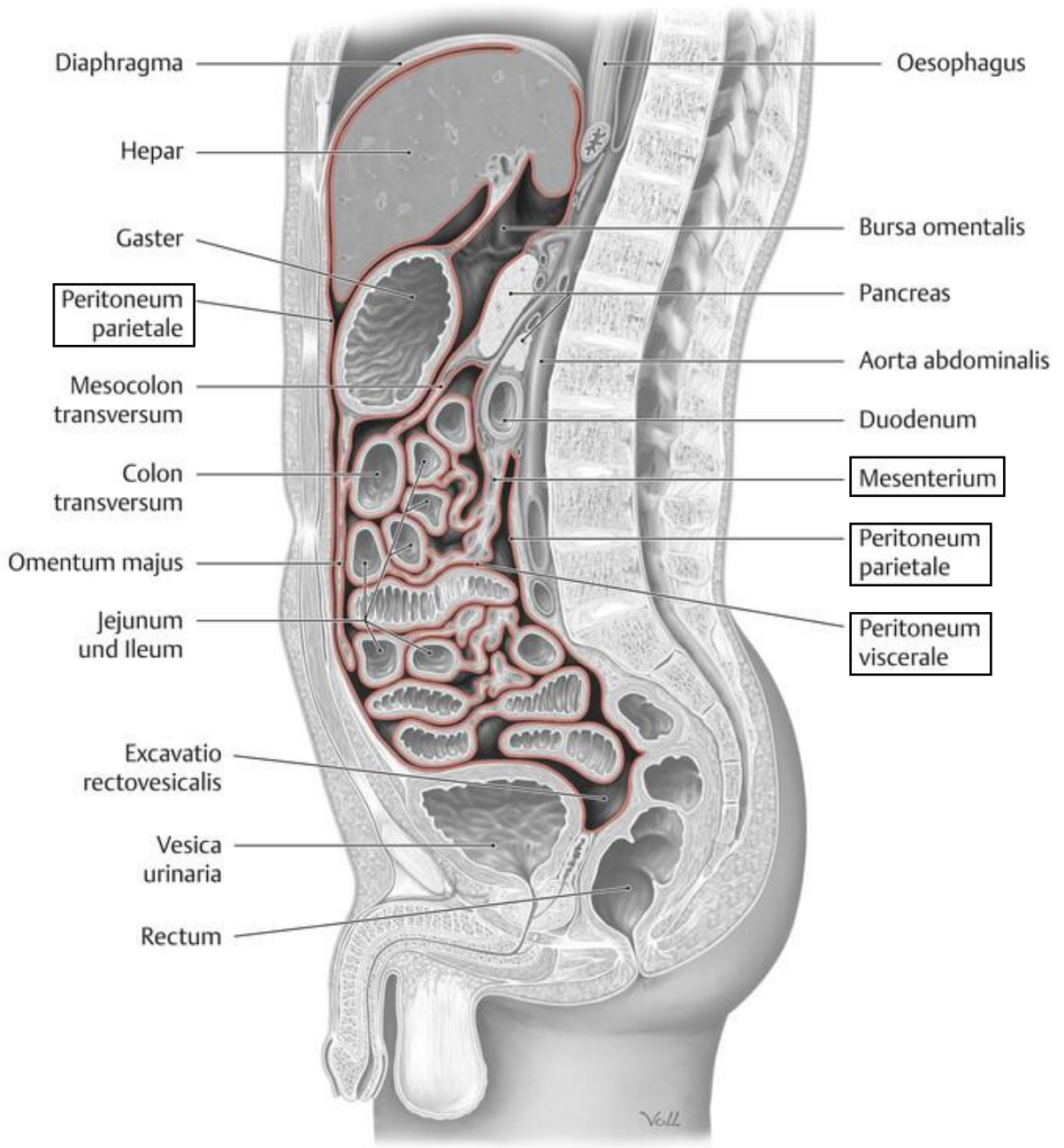
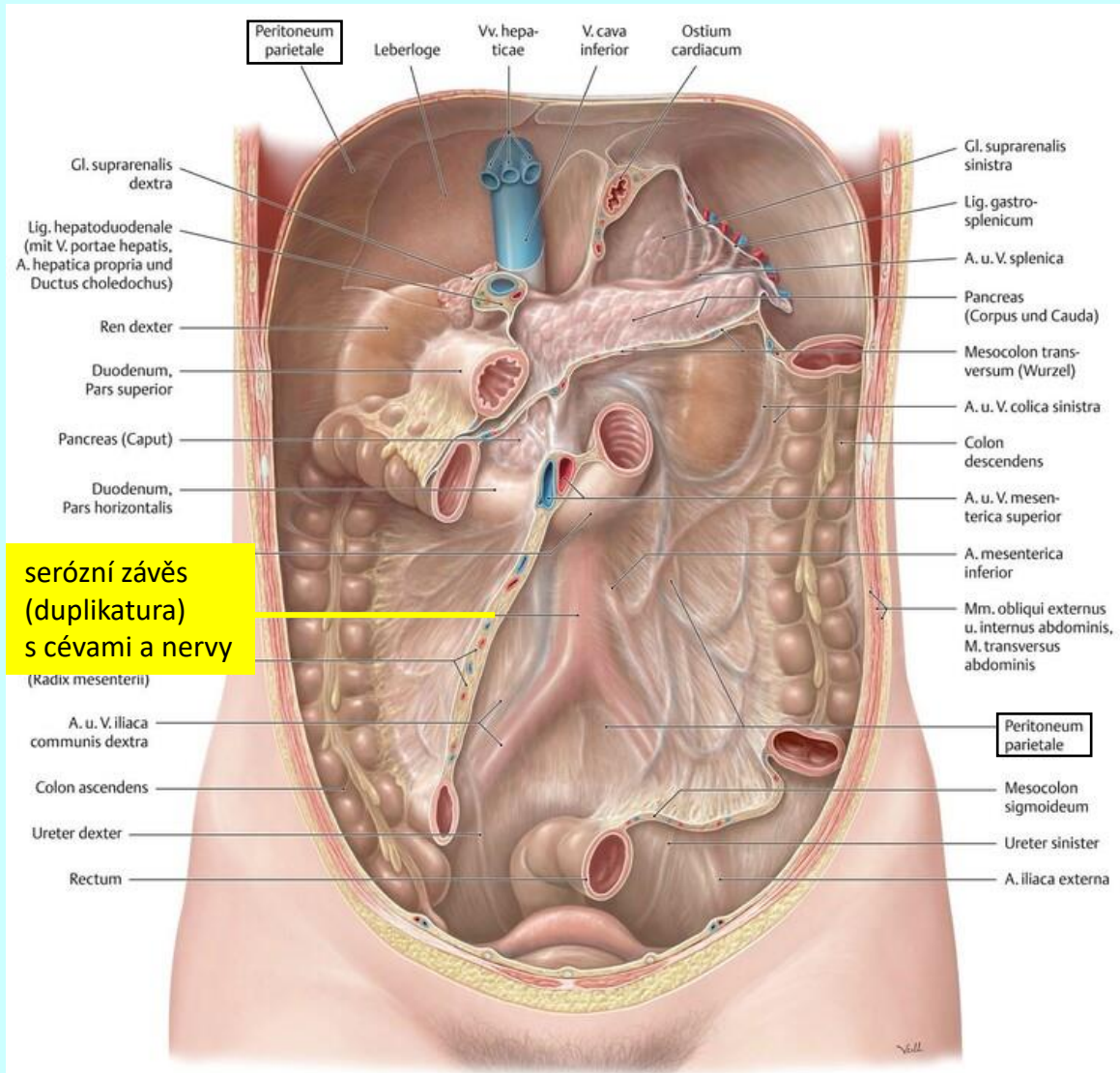
seróza × adventicie



obecná stavba trávicí trubice



obecná stavba trávicí trubice



TRÁVICÍ SOUSTAVA

(Systema digestorium)

ústní dutina
(cavum oris)

dutina ústní (*cavum oris*)

přední stěna

horní ret (*labium superius*)

dolní ret (*labium inferius*)

laterální stěna

tvář (*bucca*)

horní stěna

tvrdé patro (*palatum durum*)

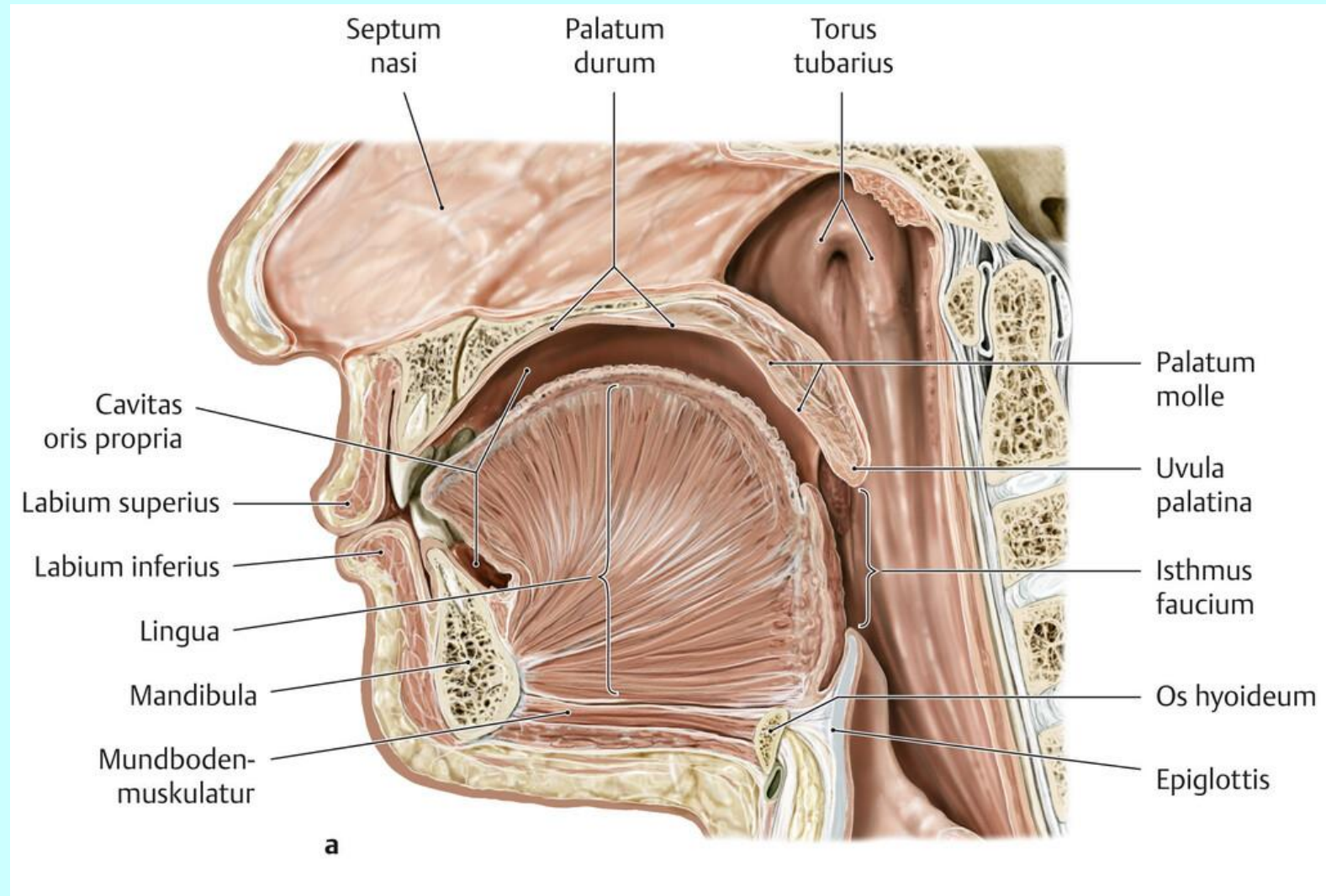
měkké patro (*palatum molle*)

dolní stěna

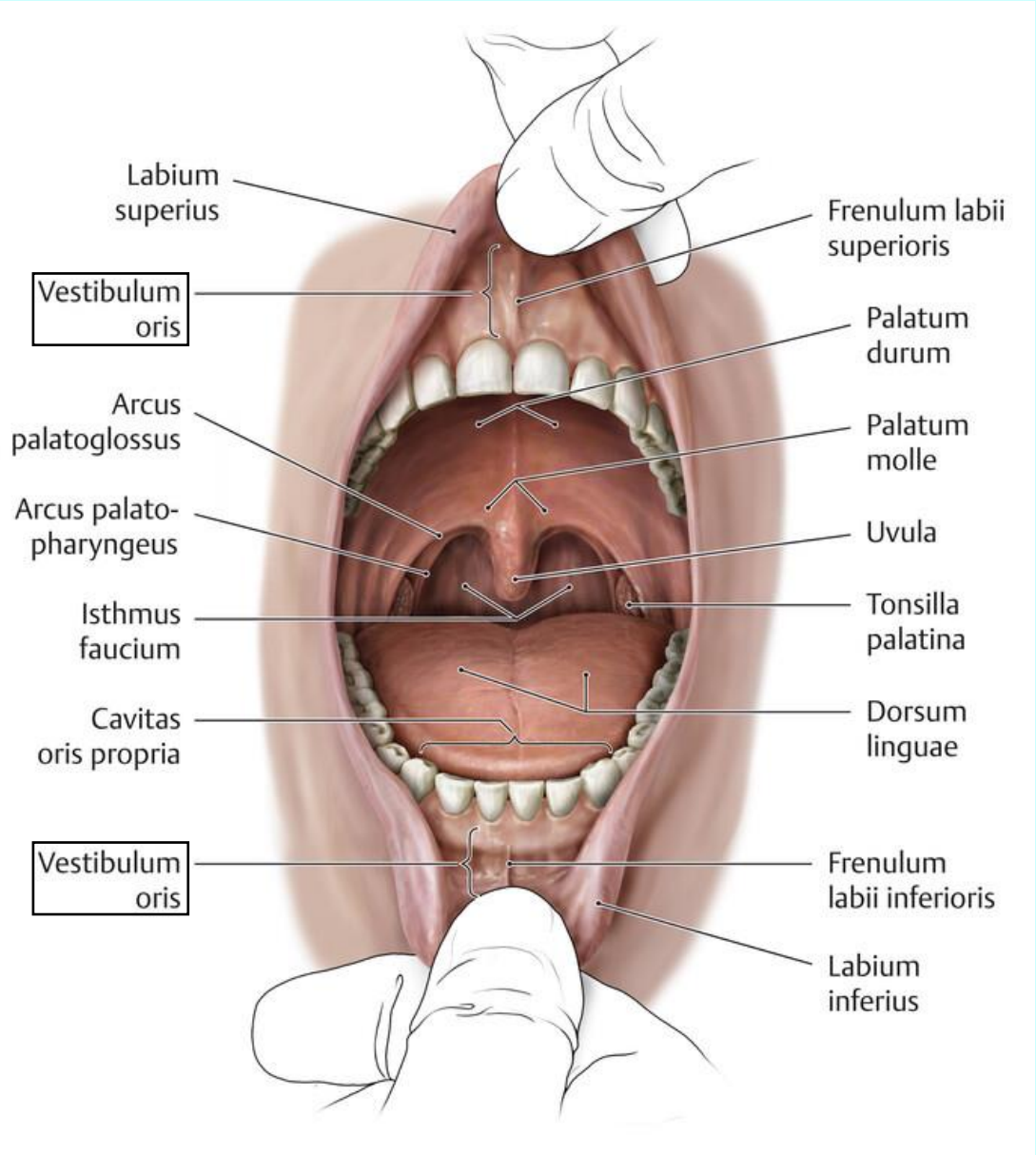
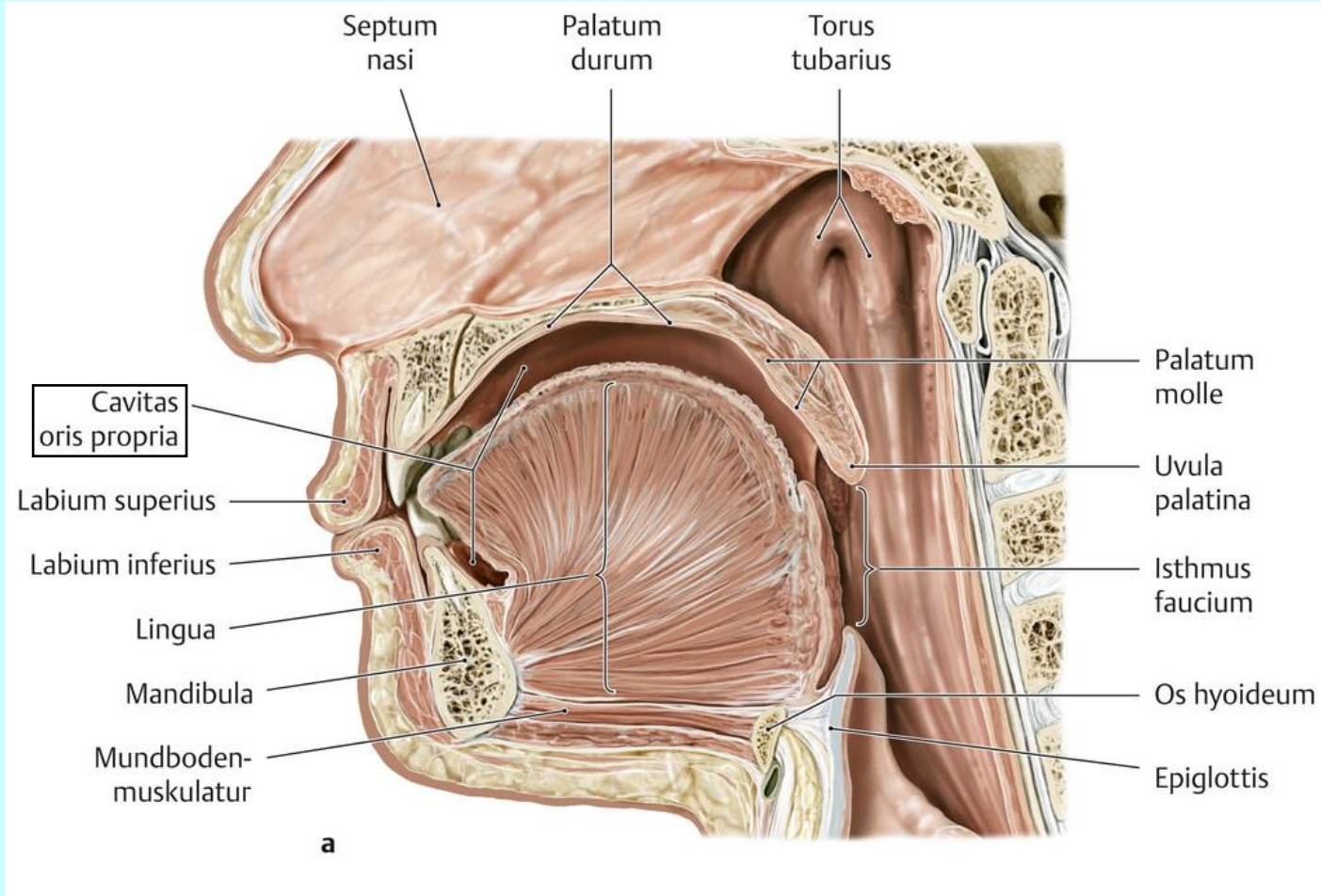
spodina (*diaphragma oris*)

zadní stěna

hltanová úžina (*isthmus faucium*)



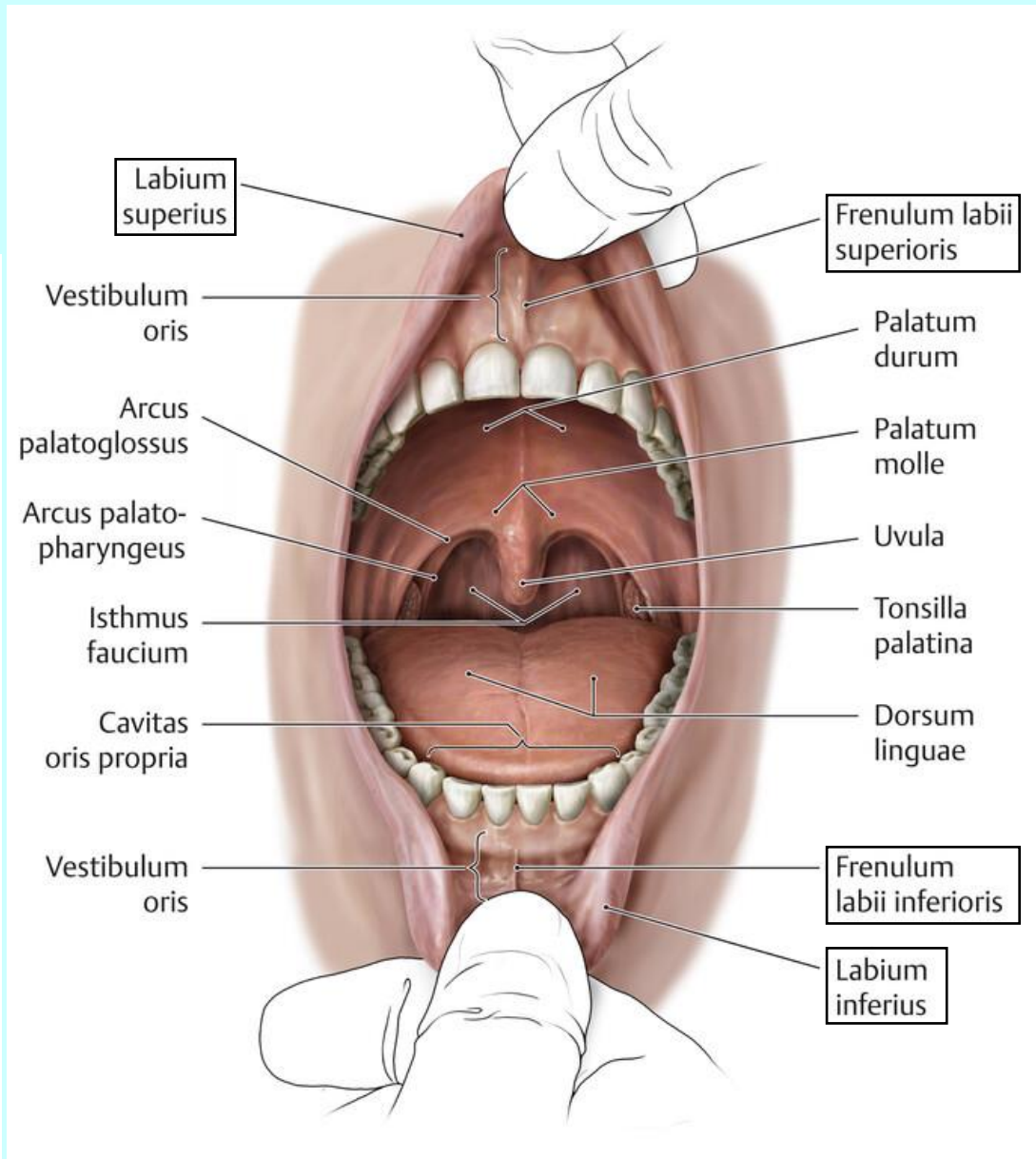
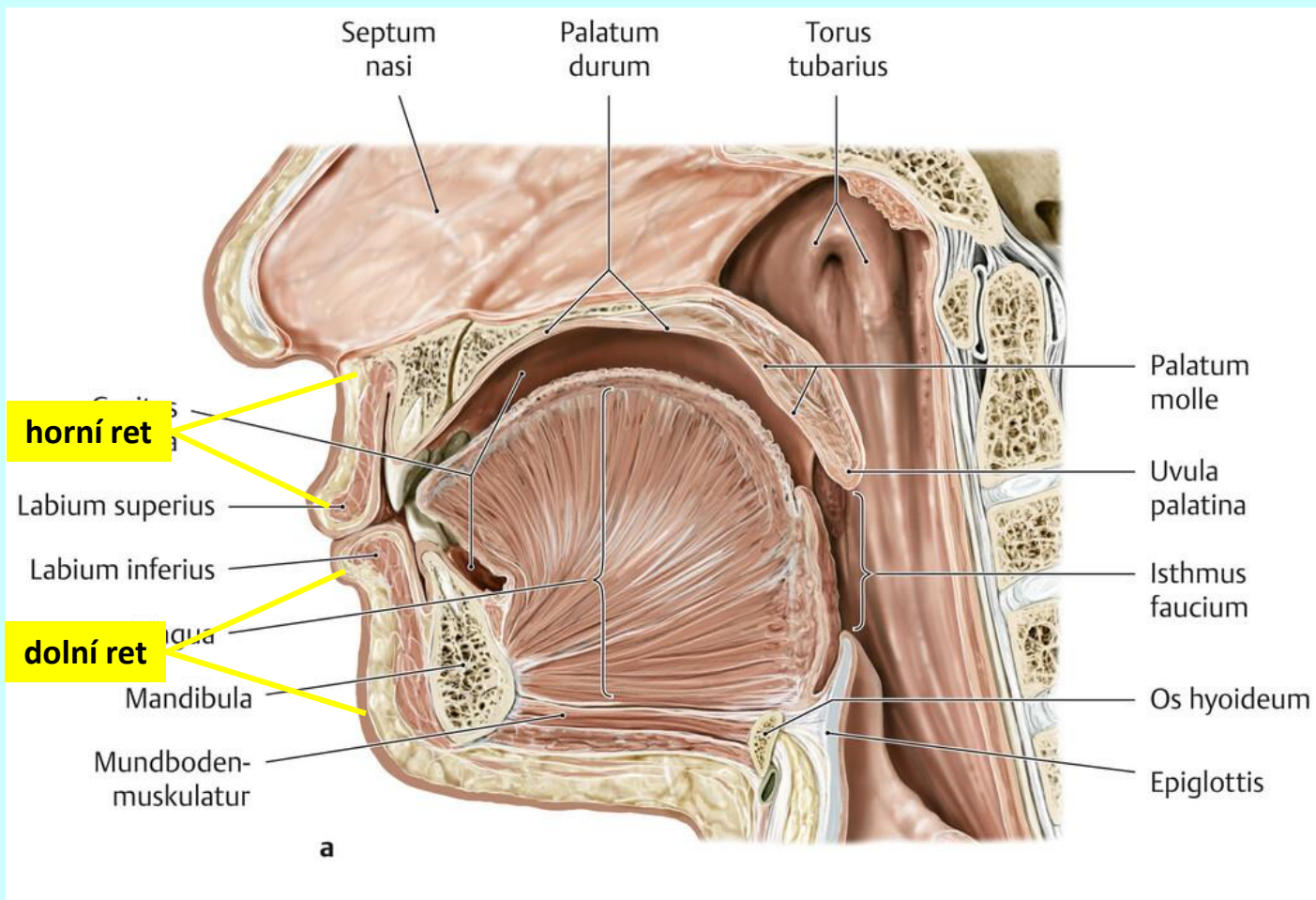
dutina ústní (*cavum oris*)



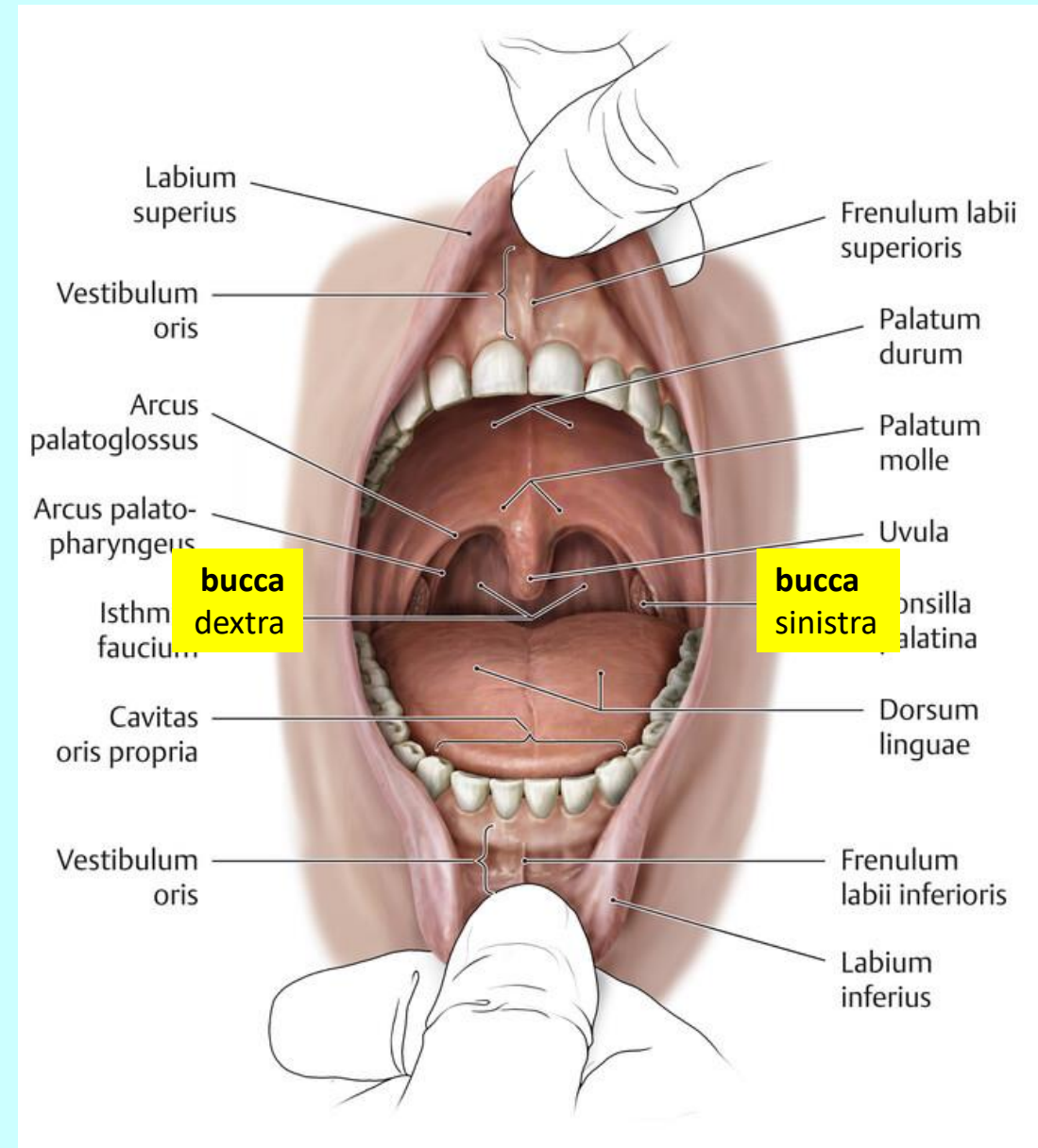
rtý (labia)

horní ret (labium superius)

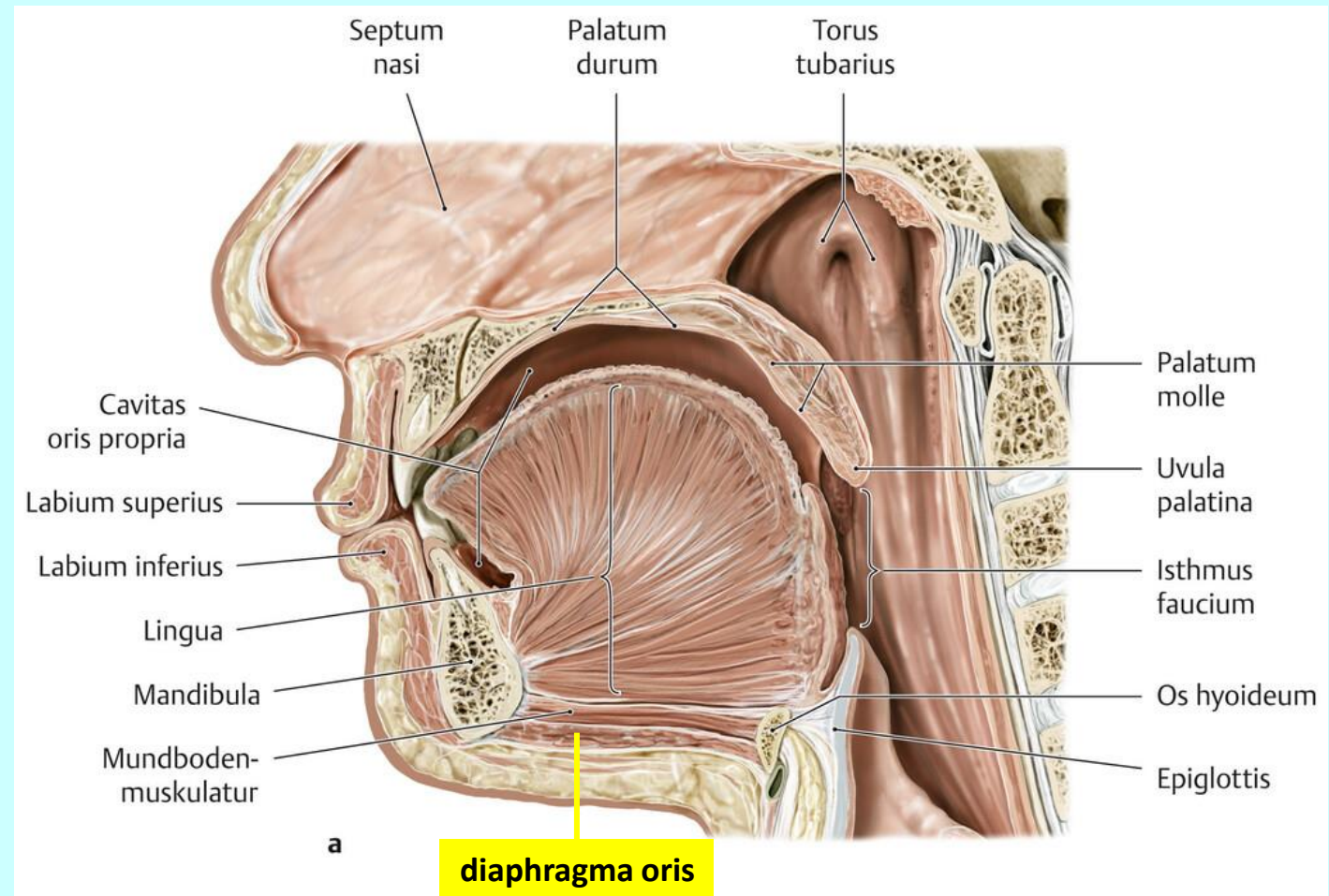
dolní ret (labium inferius)



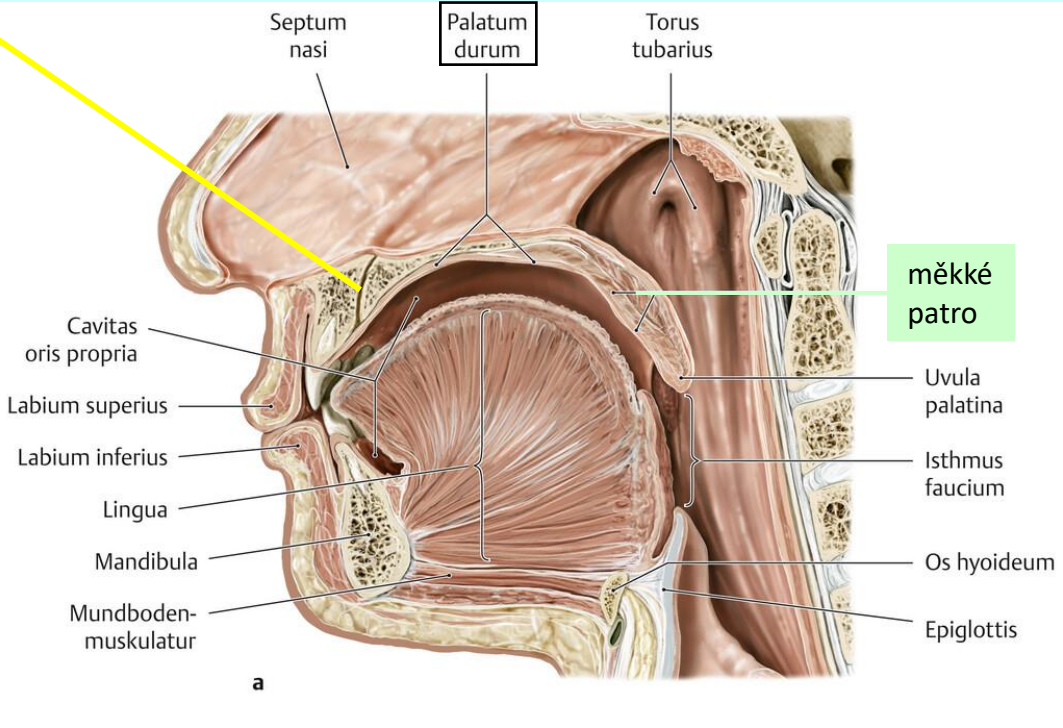
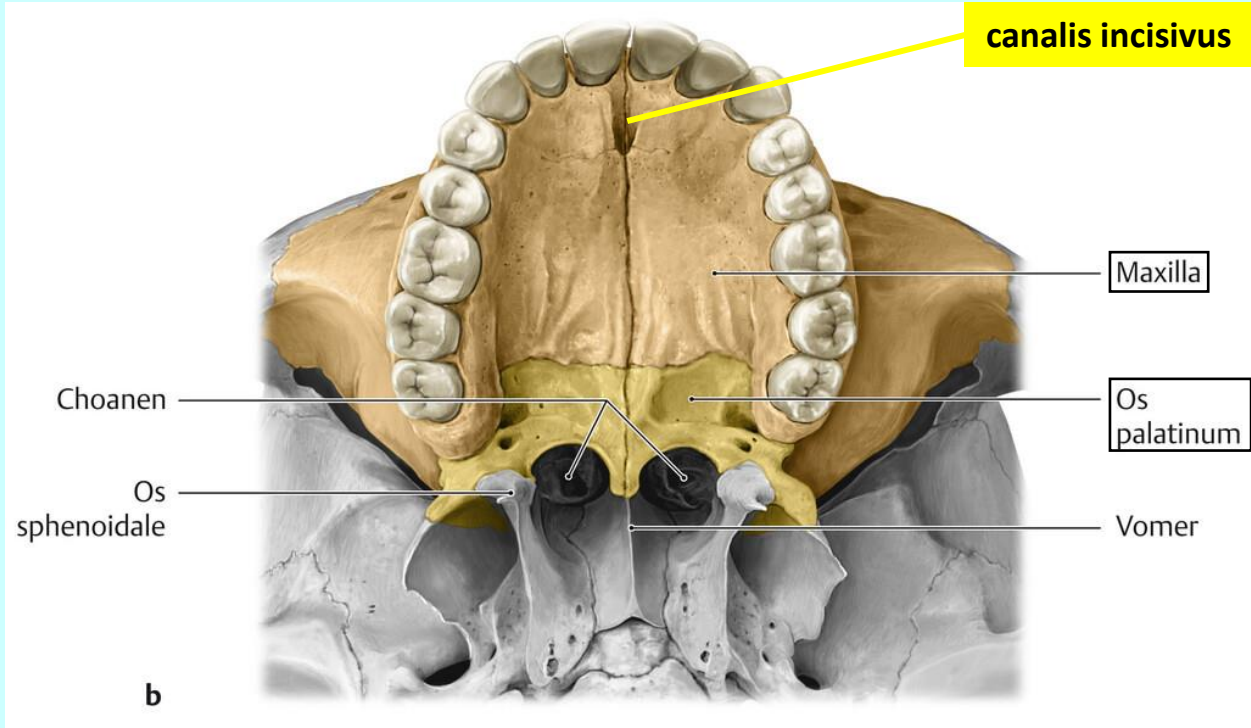
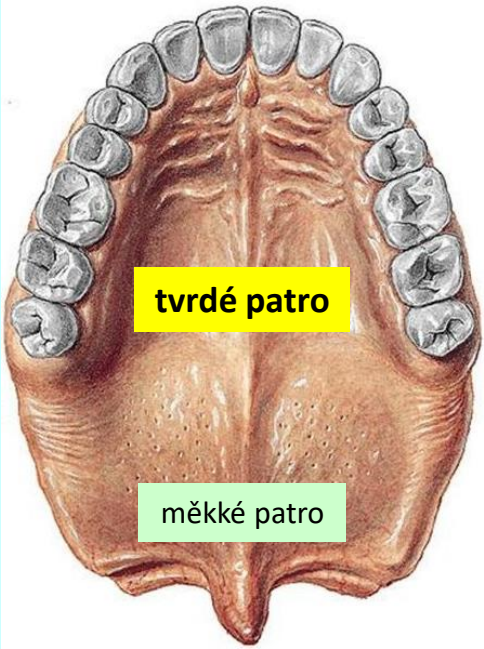
tvář (*bucca*)



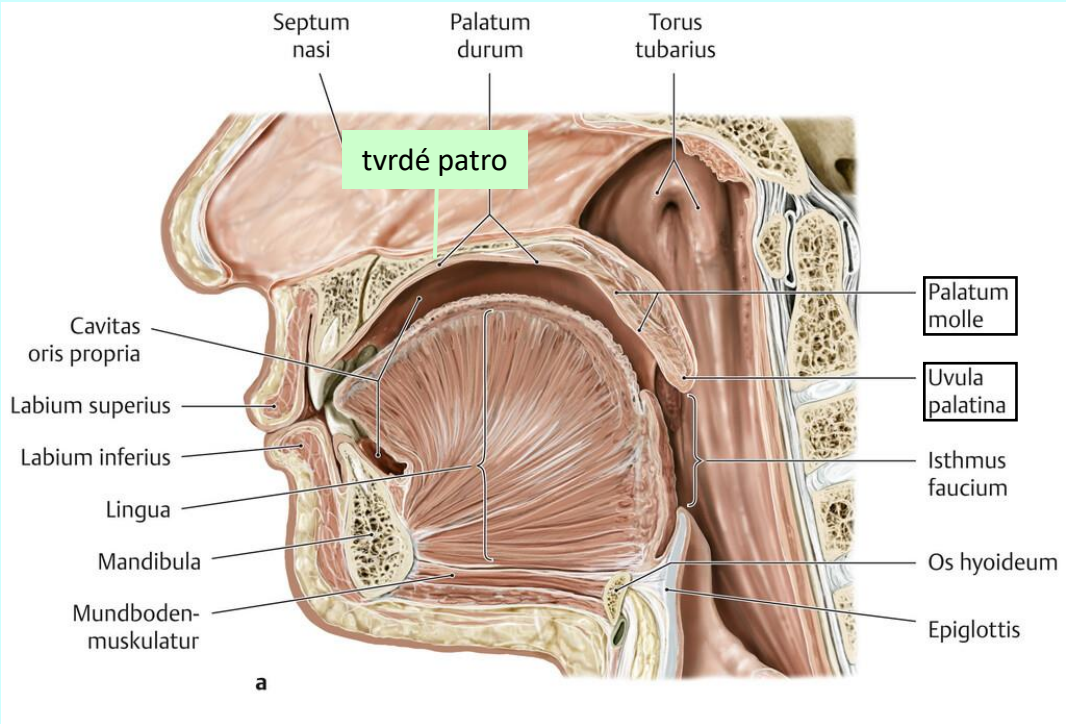
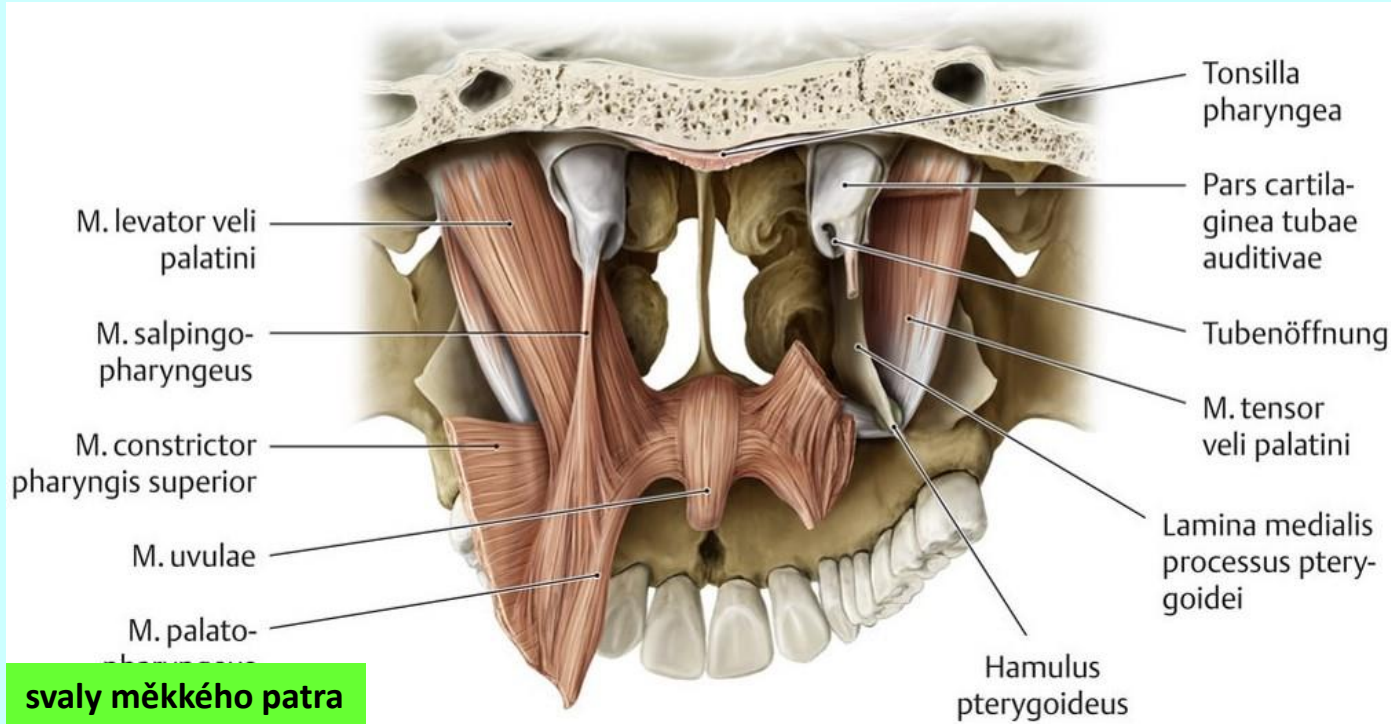
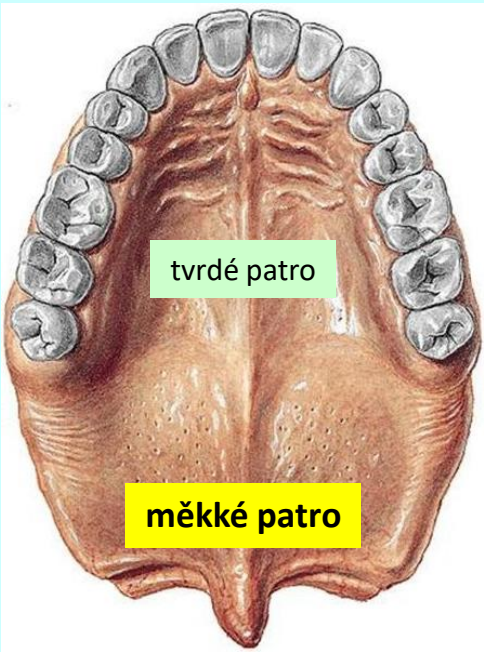
spodina (*diaphragma oris*)



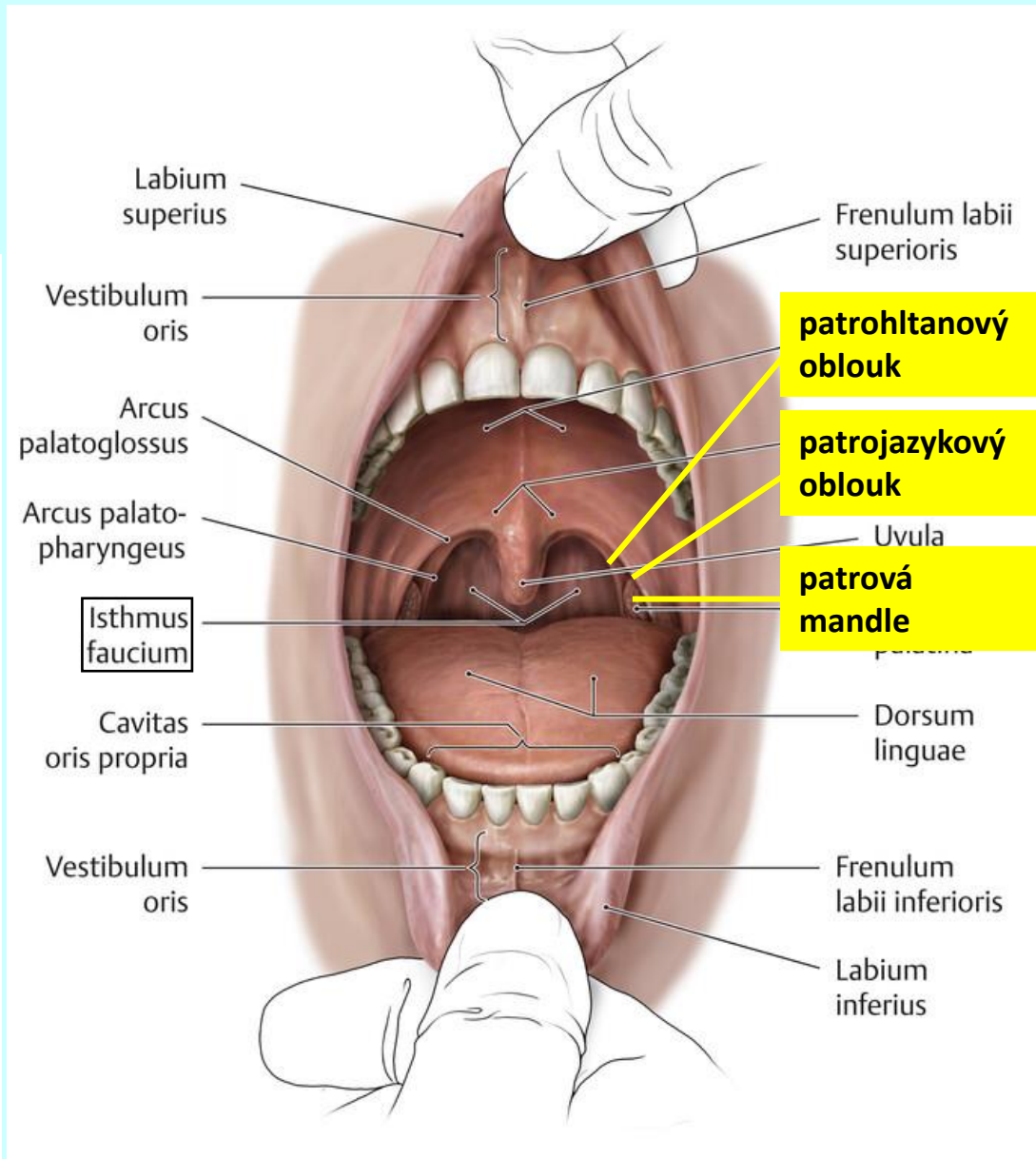
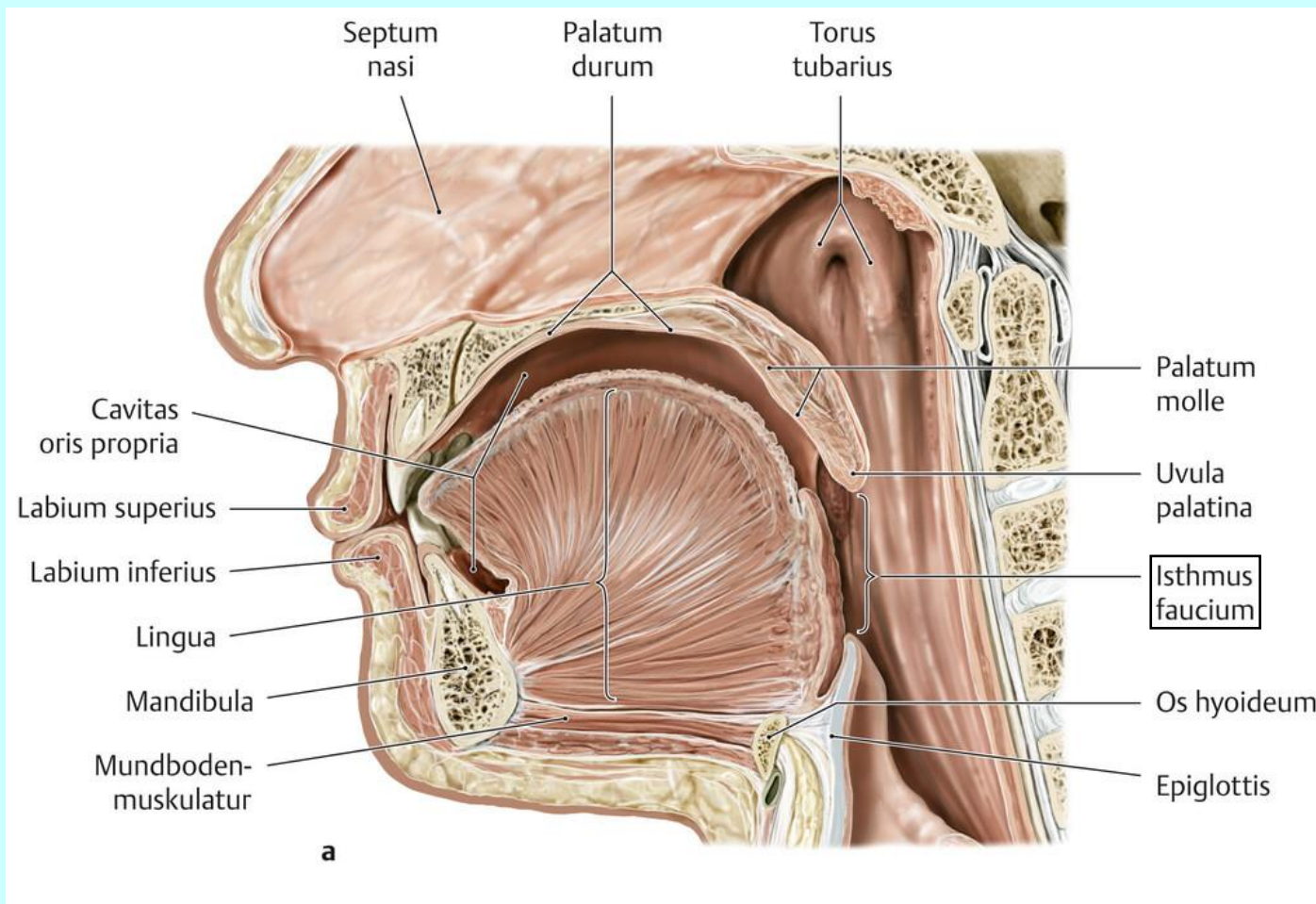
tvrdé patro (*palatum durum*)



měkké patro (*palatum molle*)

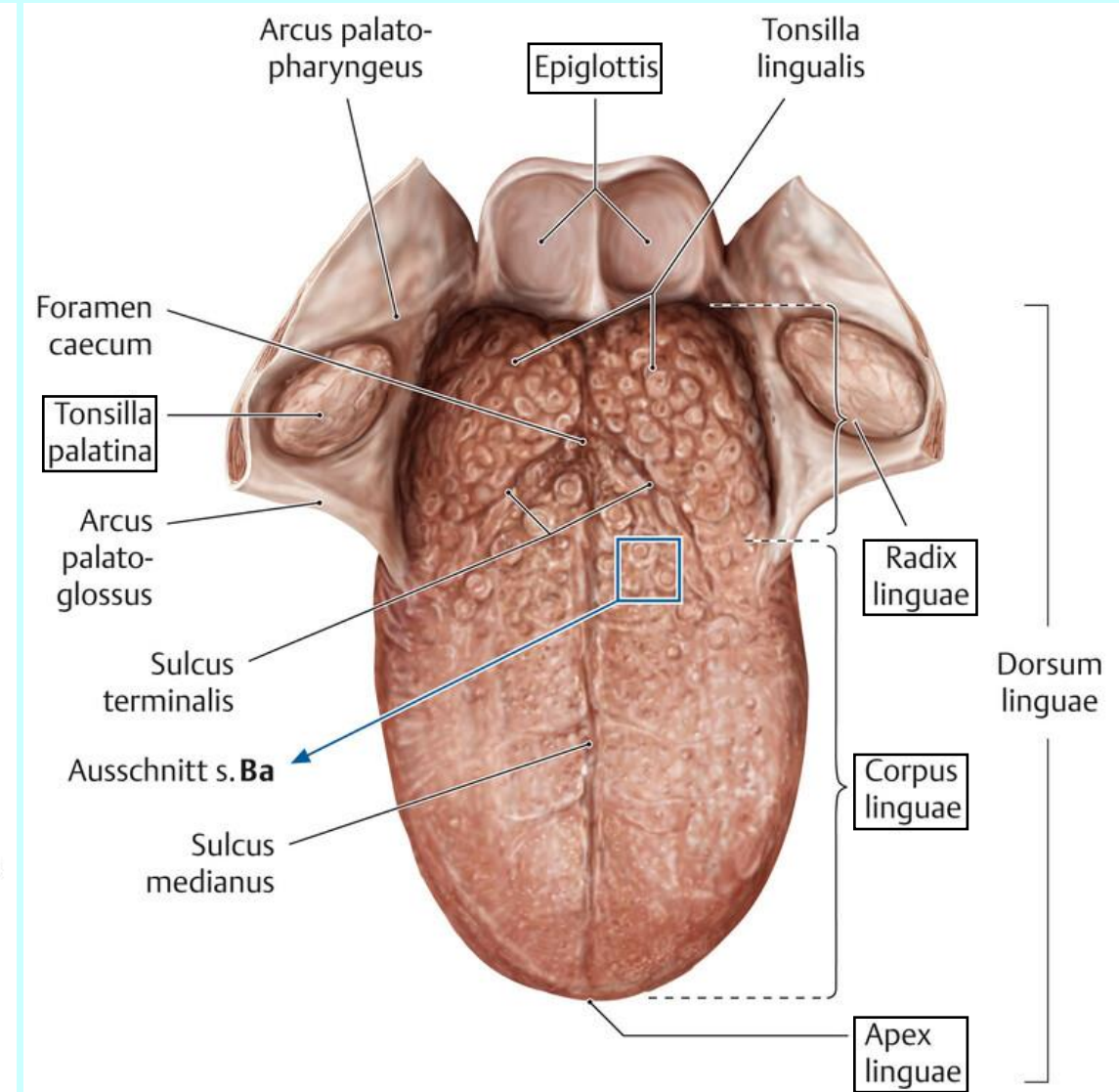
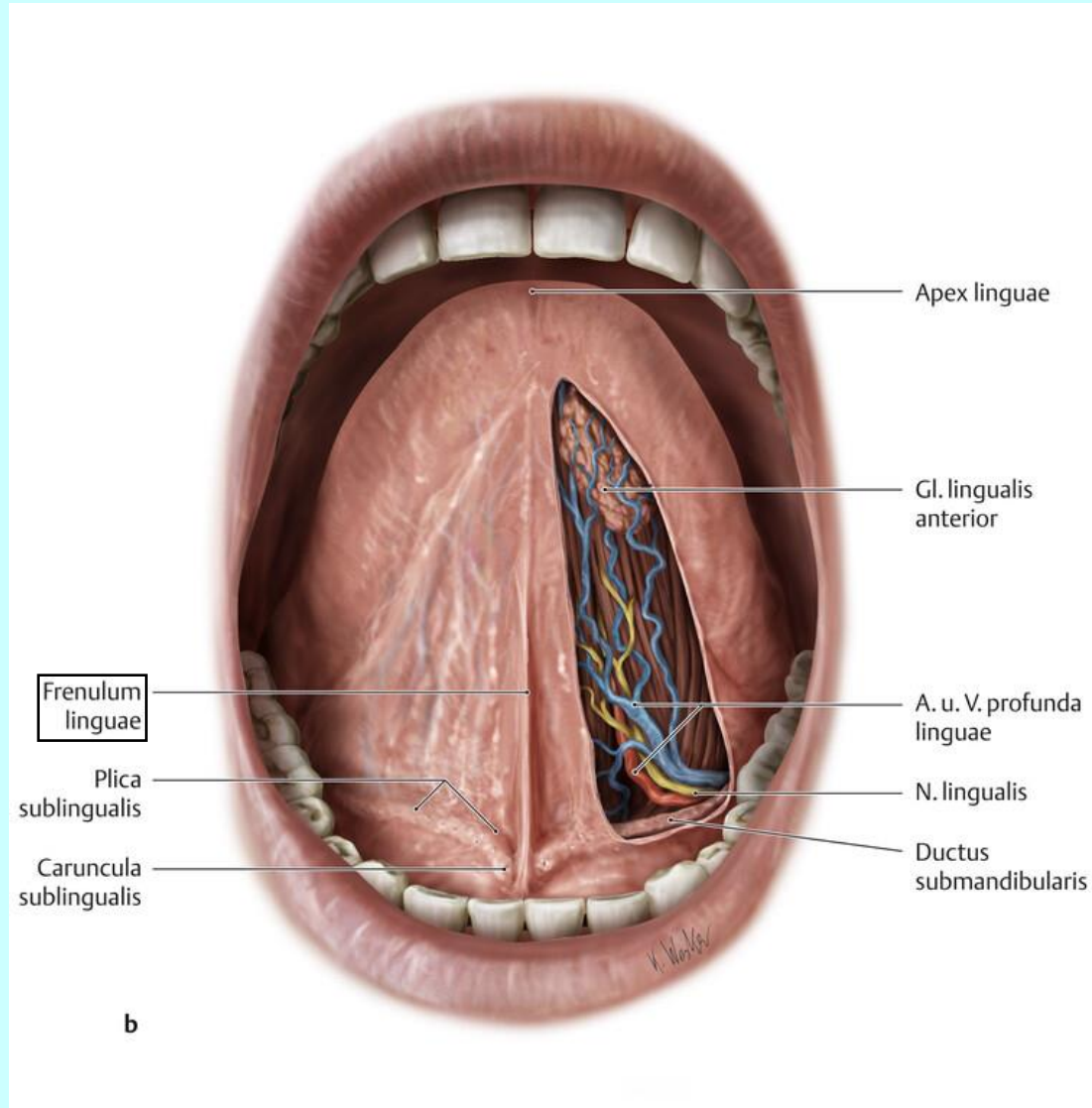


hltanová úžina (*isthmus faucium*)



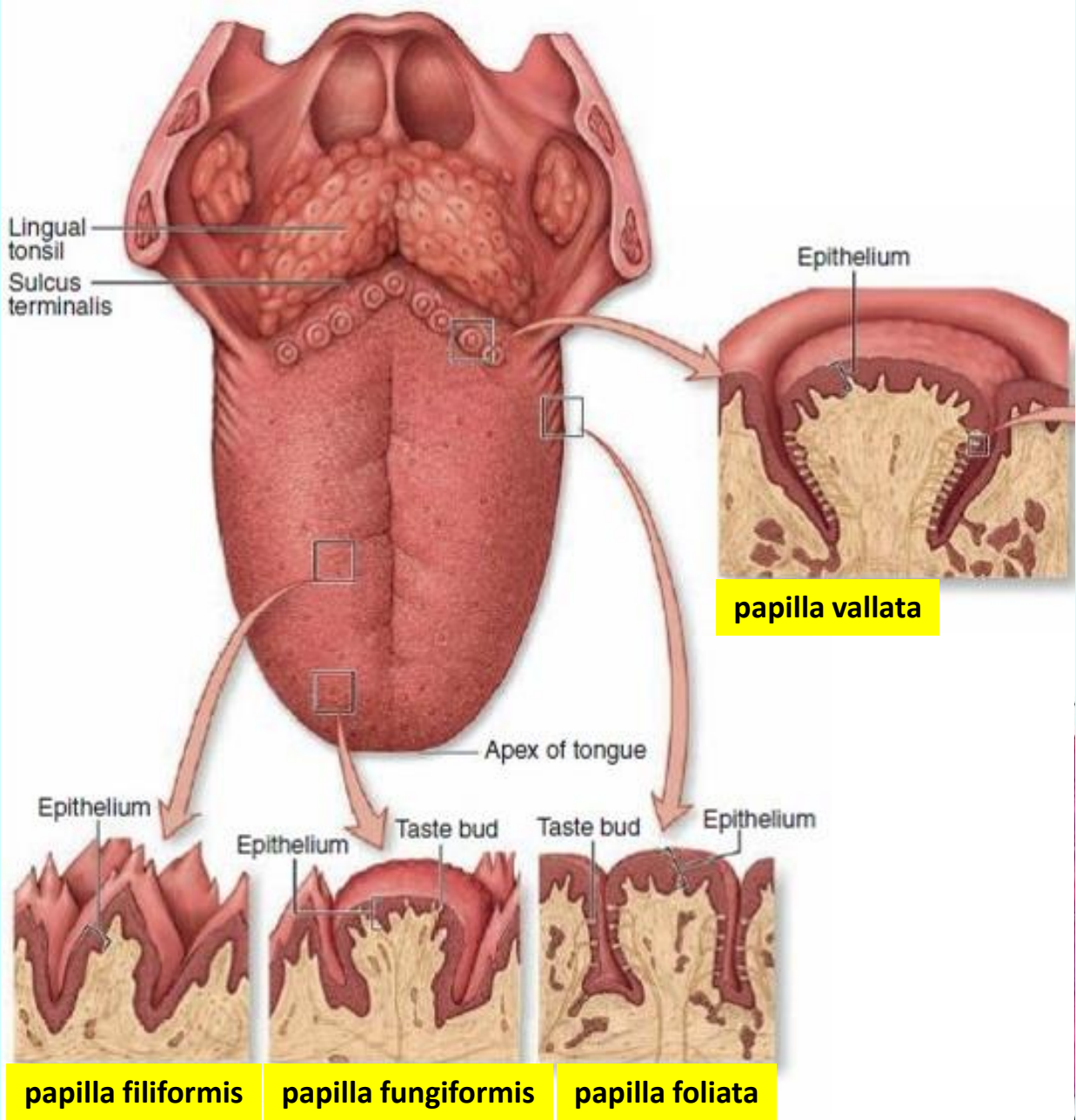
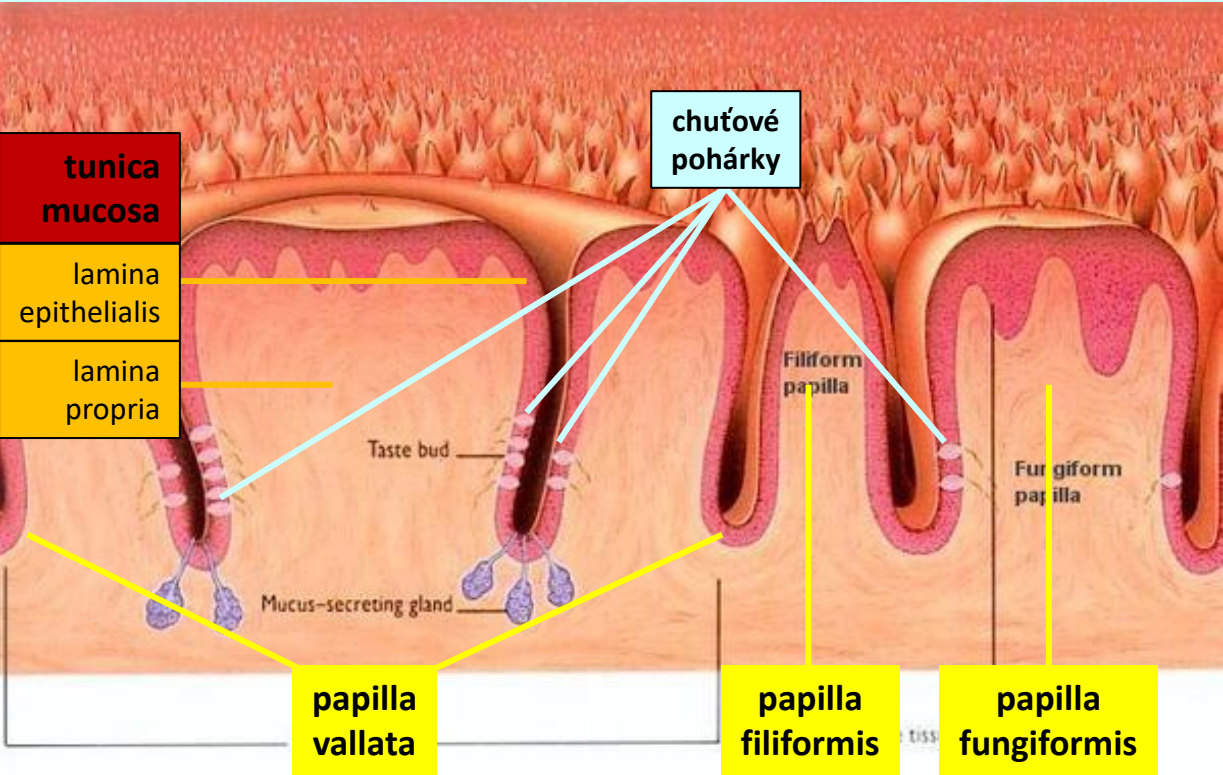
jazyk (*lingua*)

makroskopická stavba



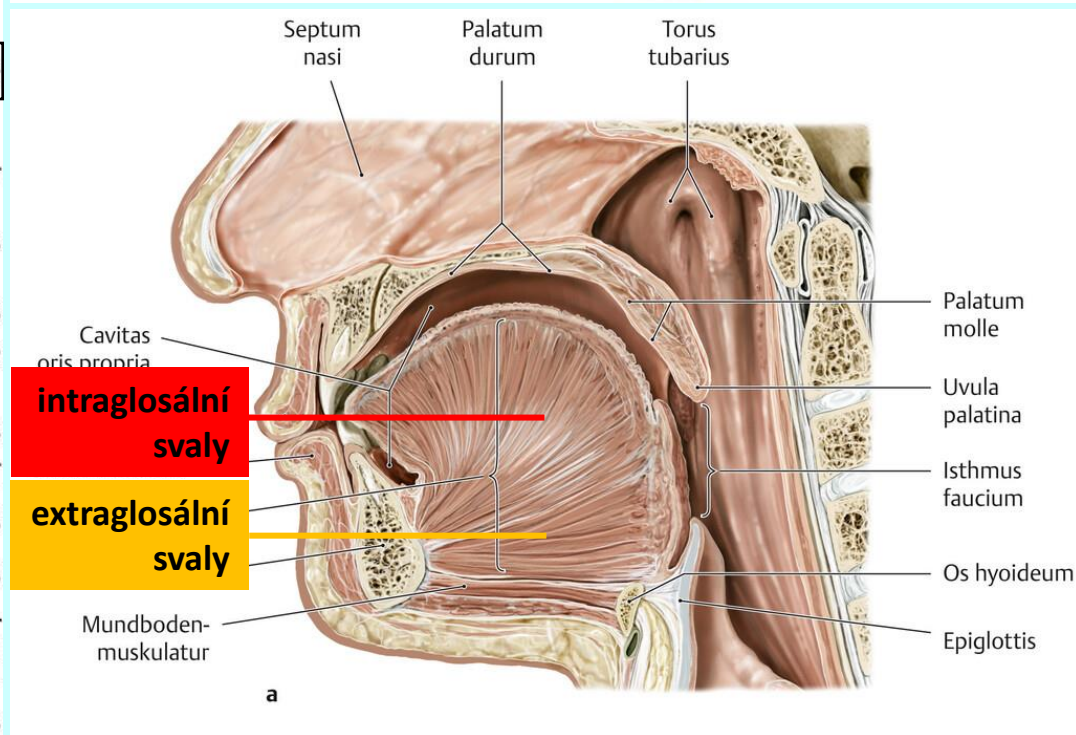
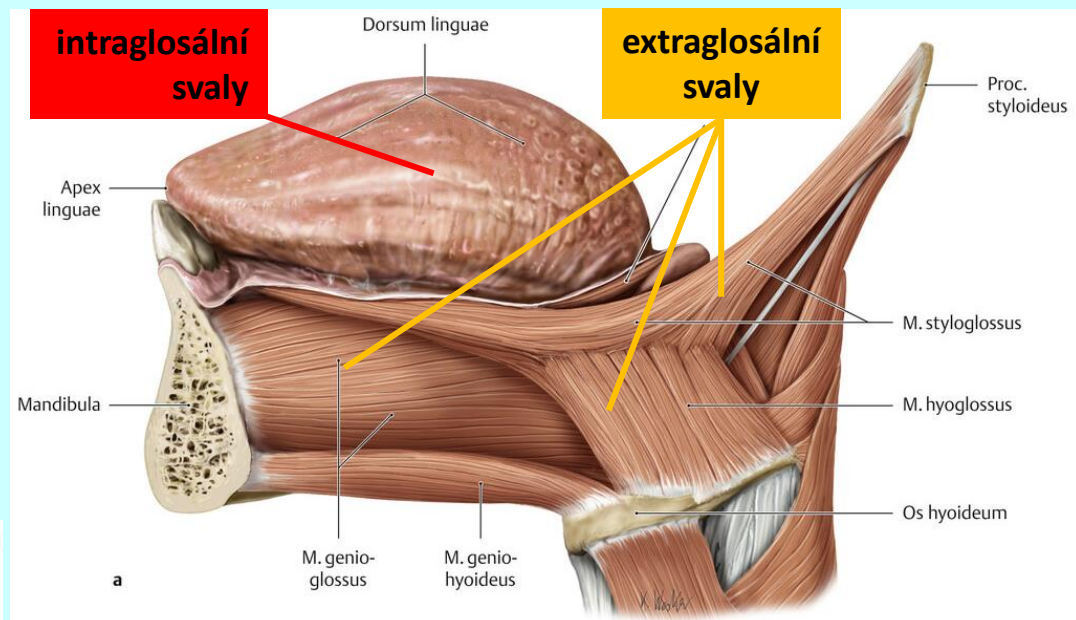
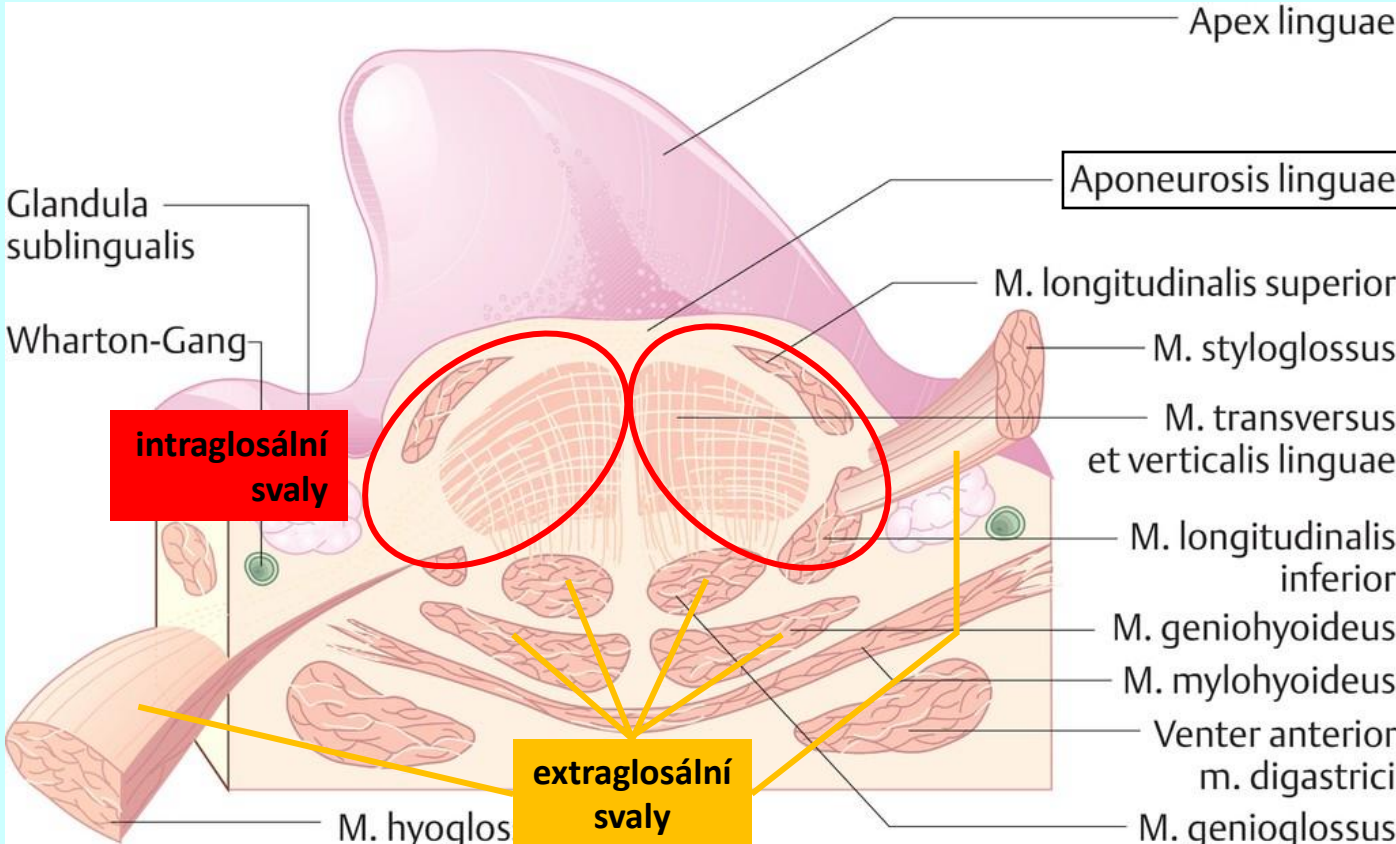
jazyk (*lingua*)

histologická stavba

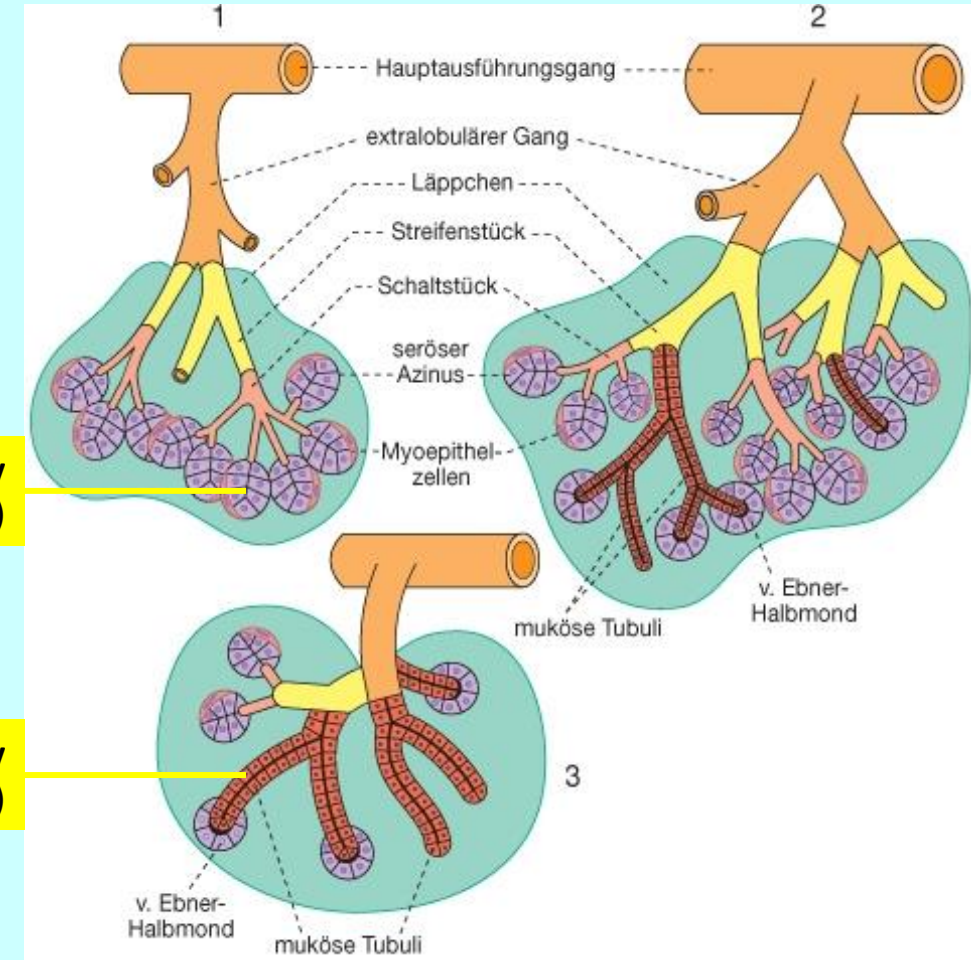
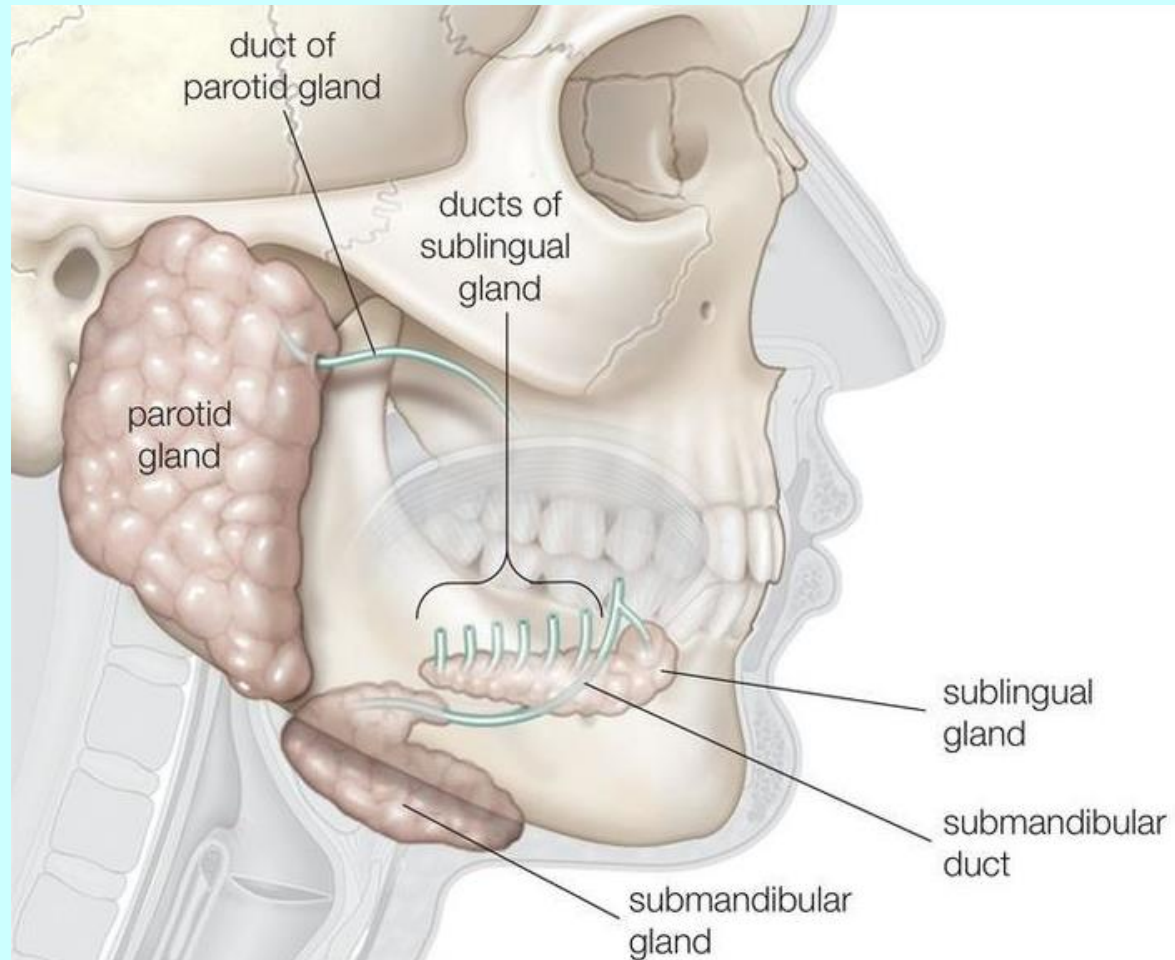


jazyk (*lingua*)

histologická stavba



slinné žlázy (*glandulae salivariae*)



serózní žlázký
(acinózní)

mucinózní žlázký
(tubulózní)

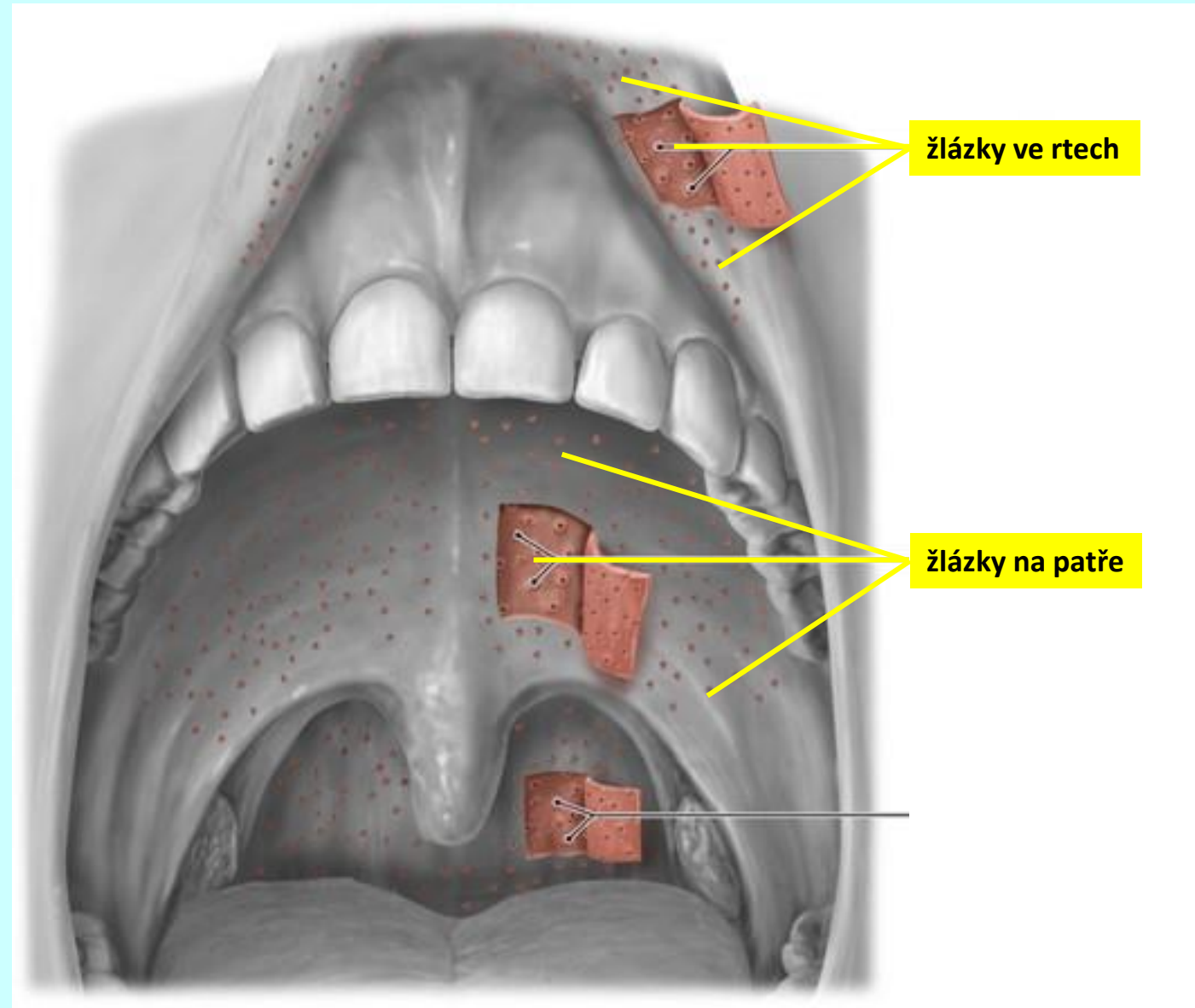
malé slinné žlázy (*glandulae salivariae minores*)

žlázky ve sliznici rtů

žlázky ve sliznici tváří

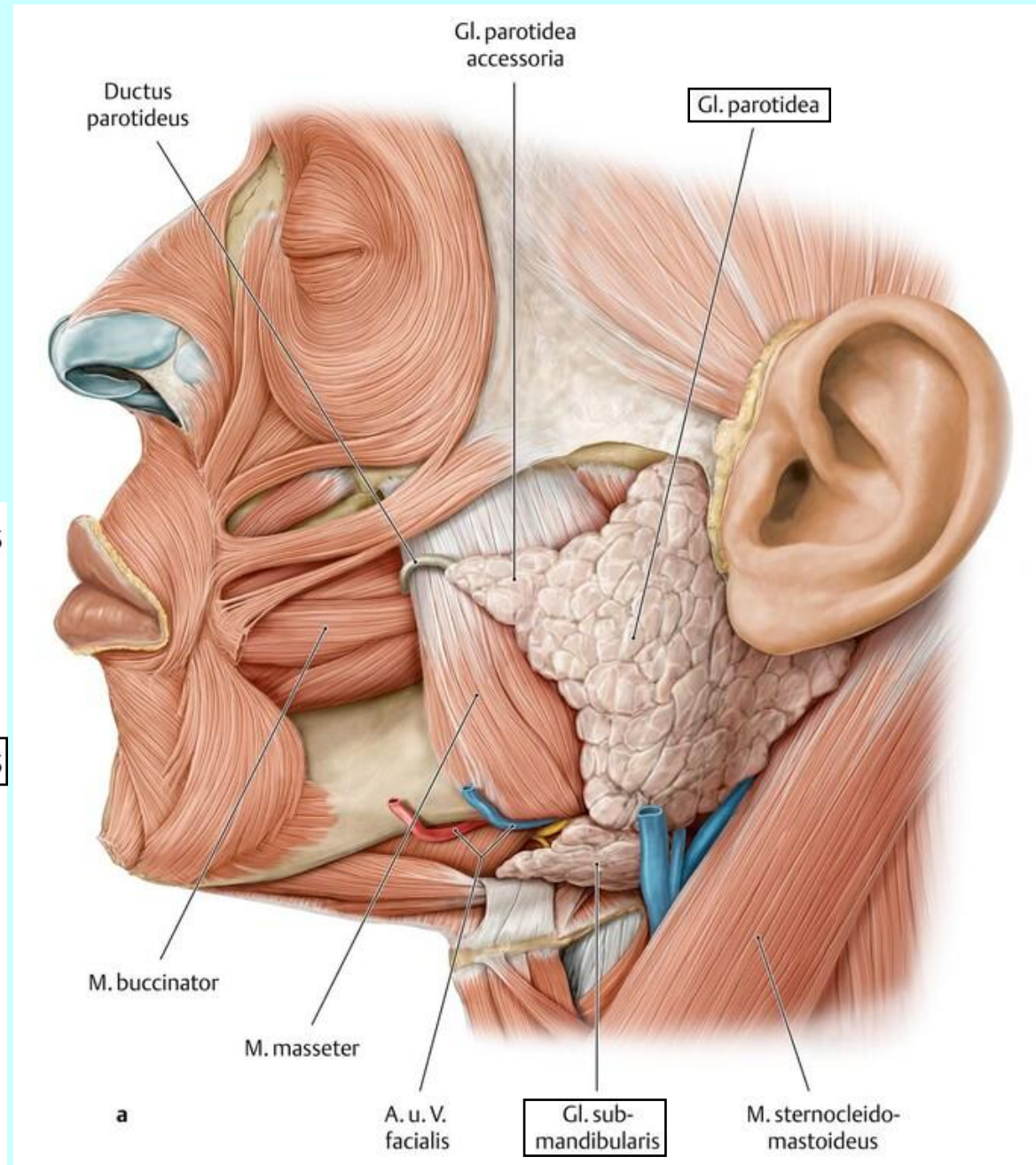
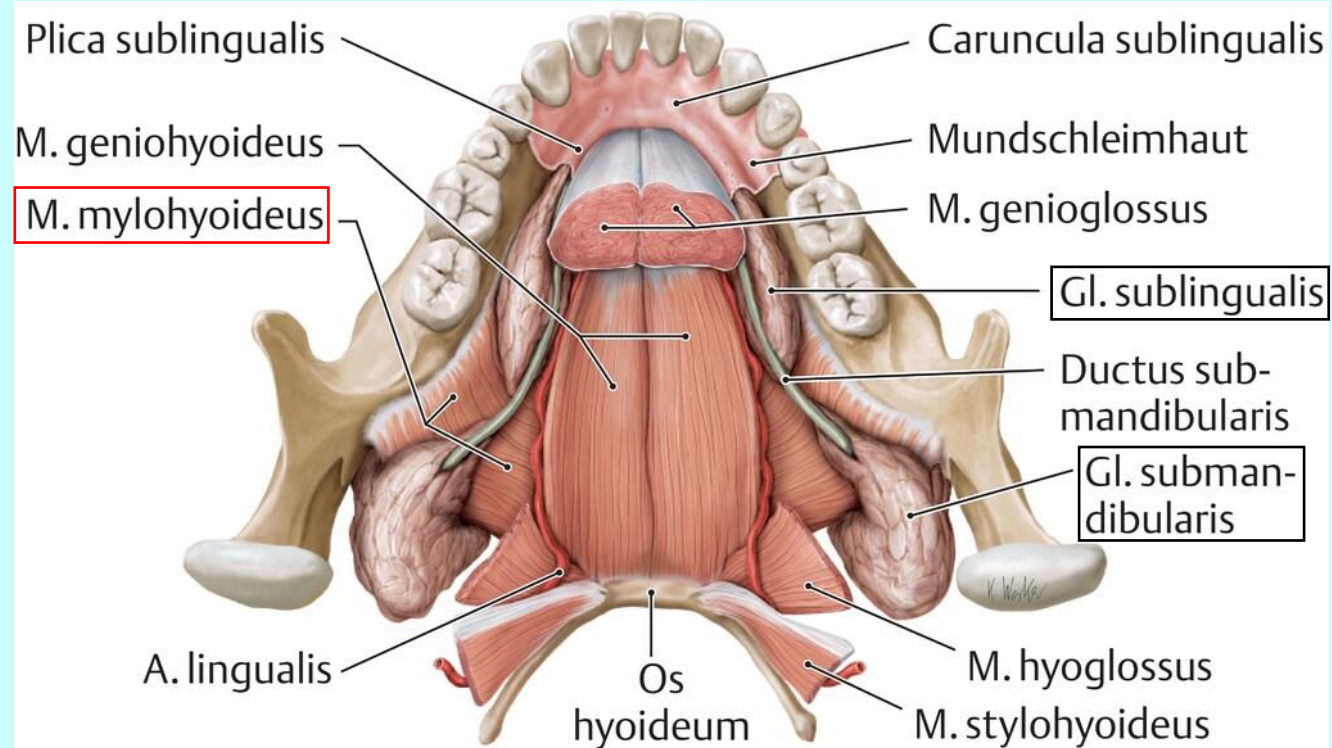
žlázky ve sliznici patra

žlázky ve sliznici jazyka



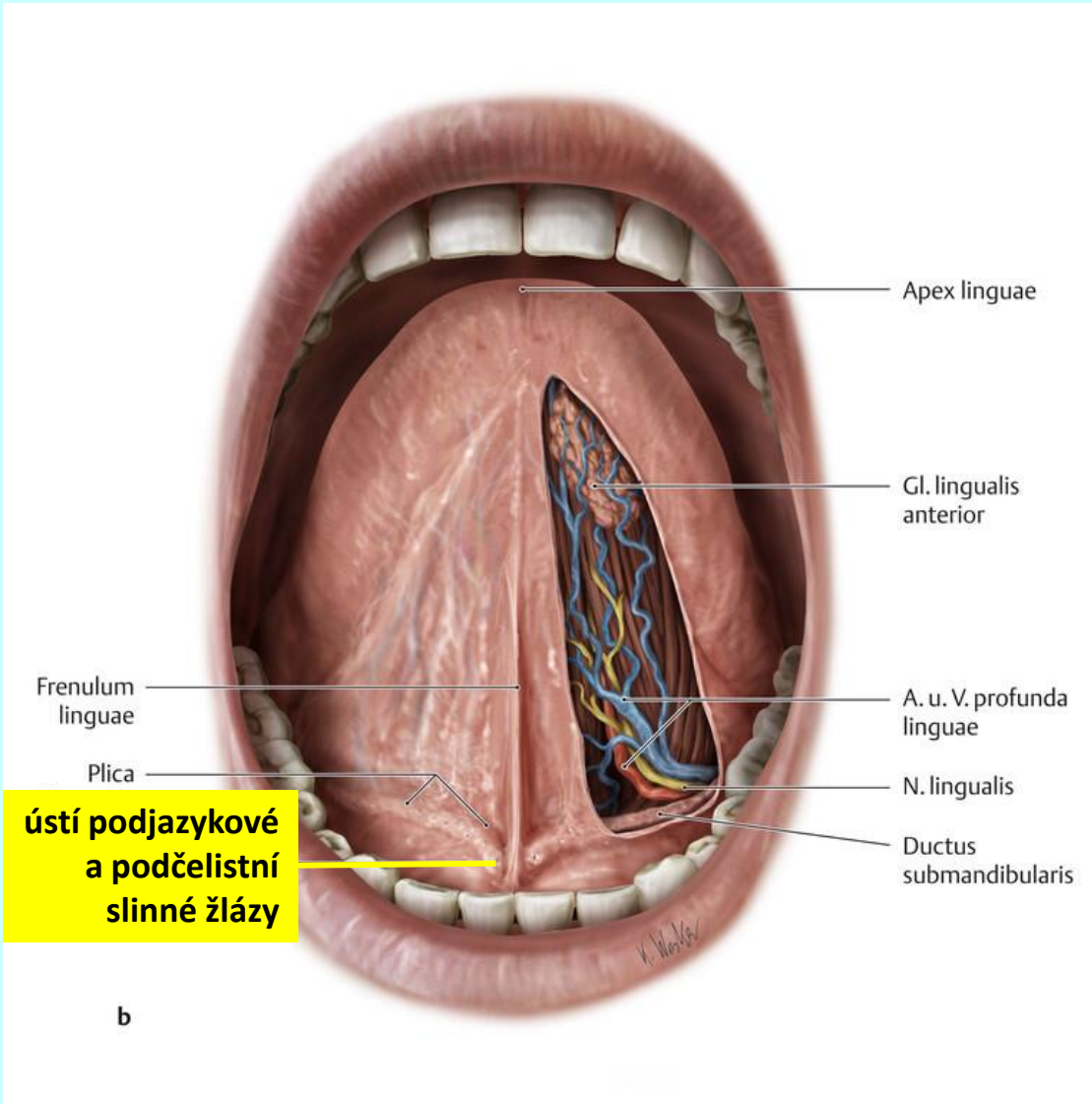
velké slinné žlázy

(*glandulae salivariae majores*)



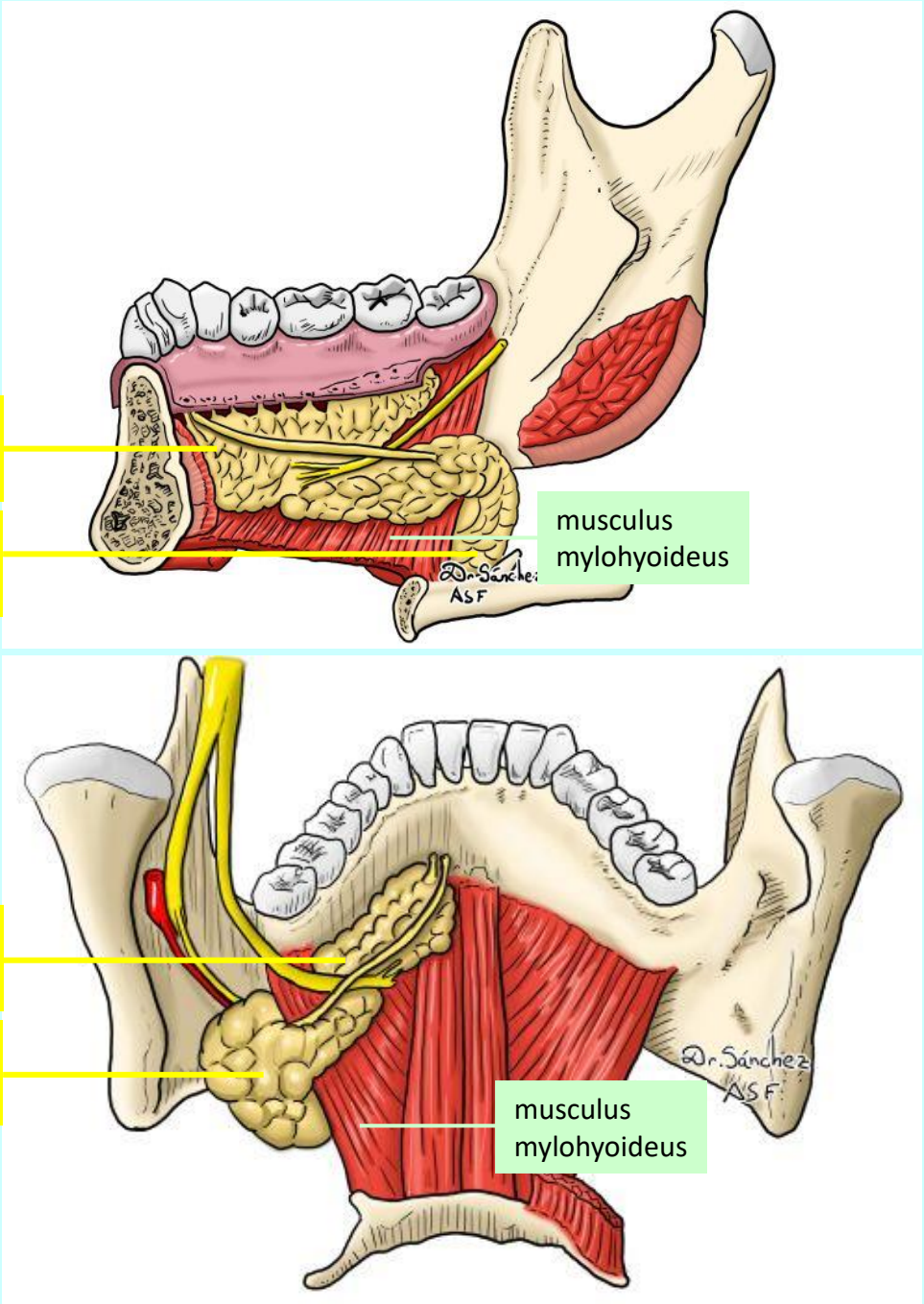
velké slinné žlázy

(glandulae salivariae majores)



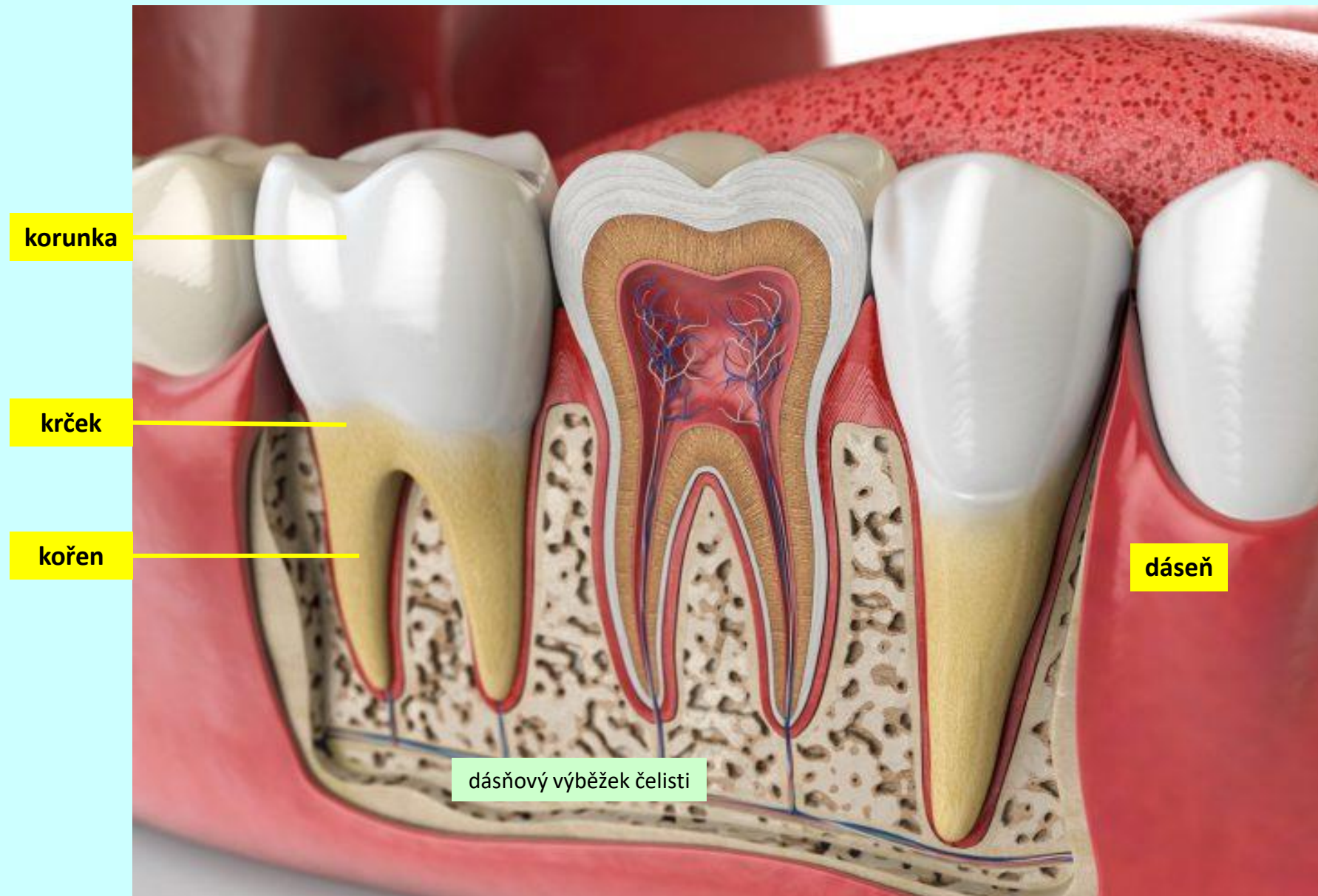
glandula sublingualis

glandula submandibularis



zuby (*dentes*)

makroskopická stavba

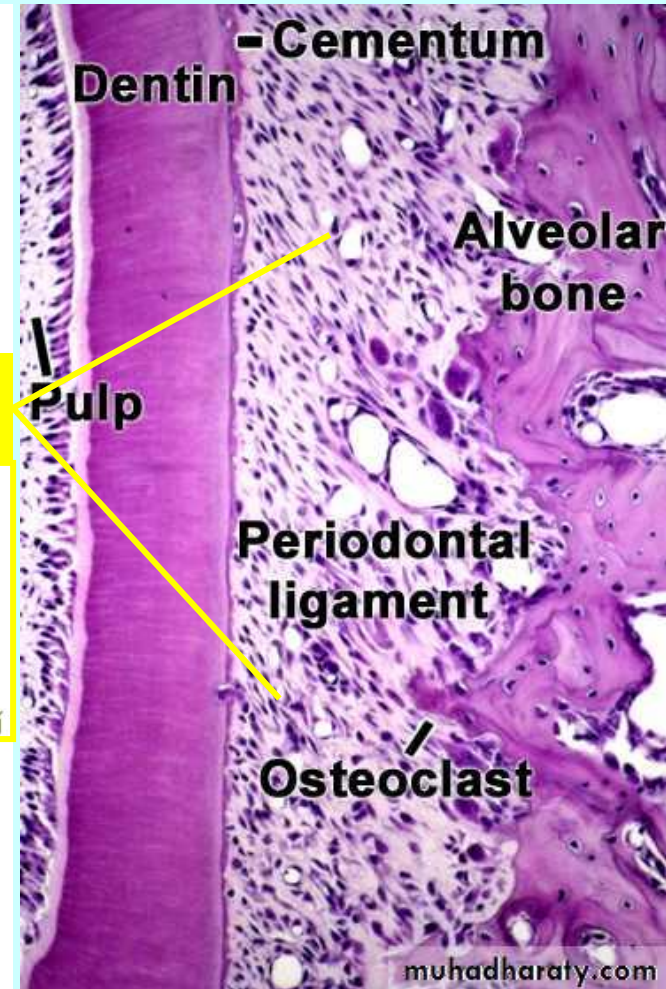
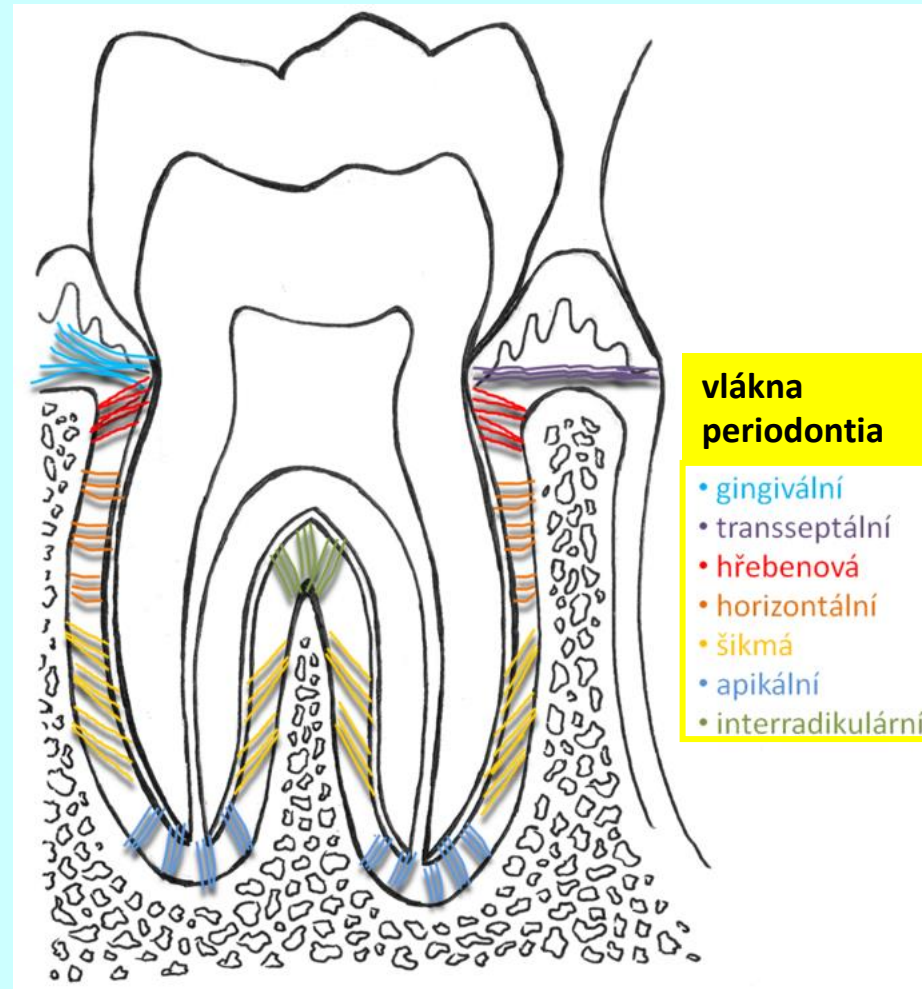
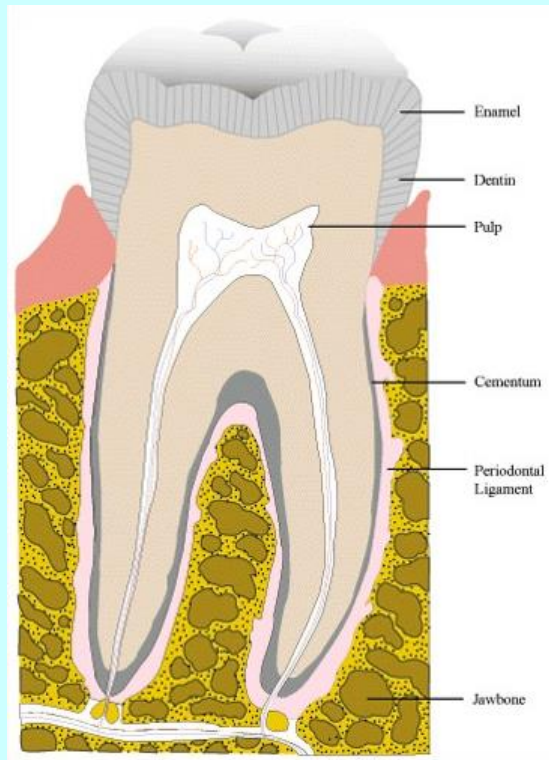


zuby (*dentes*)

makroskopická stavba

kořen

ozubice (periodontium)

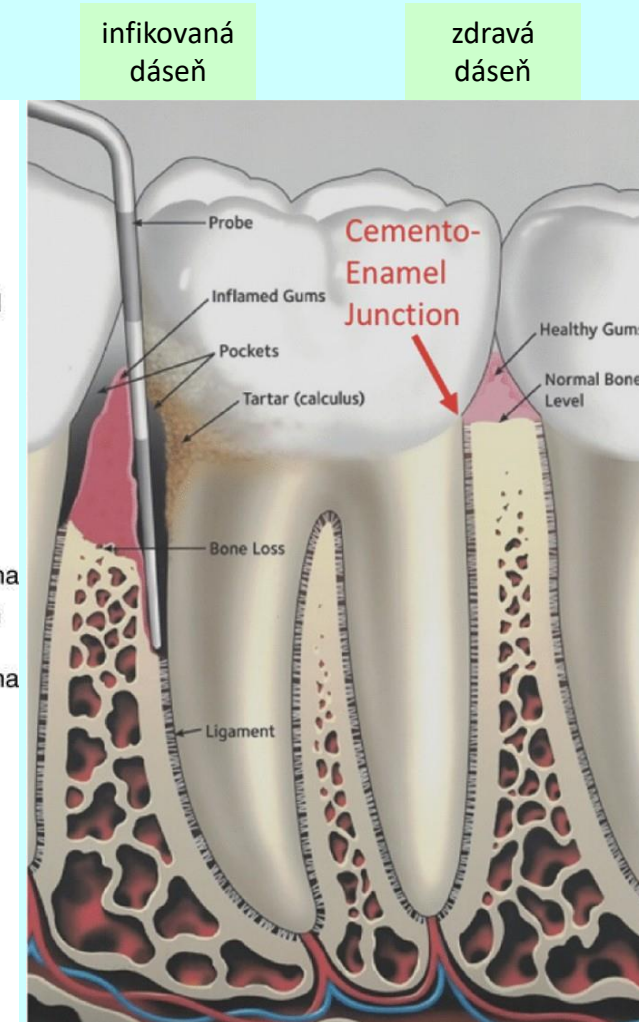
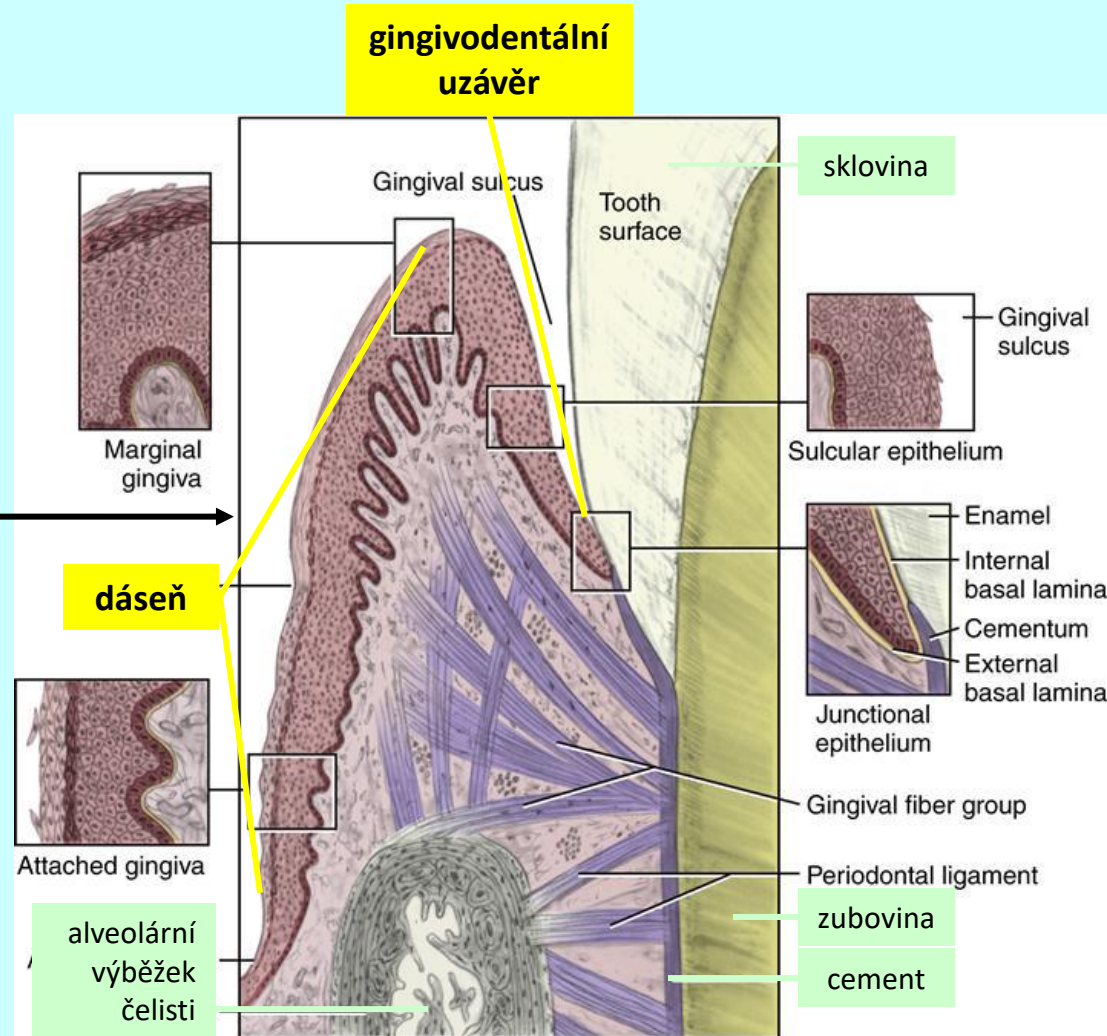
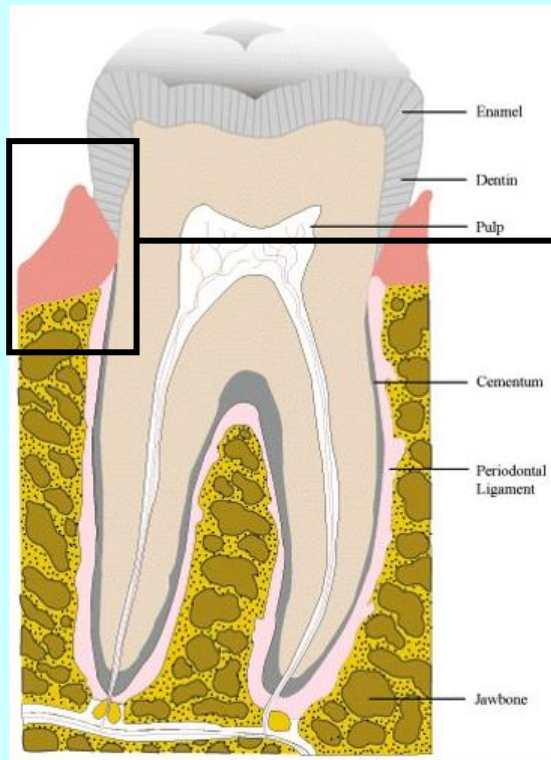


zuby (*dentes*)

makroskopická stavba

krček

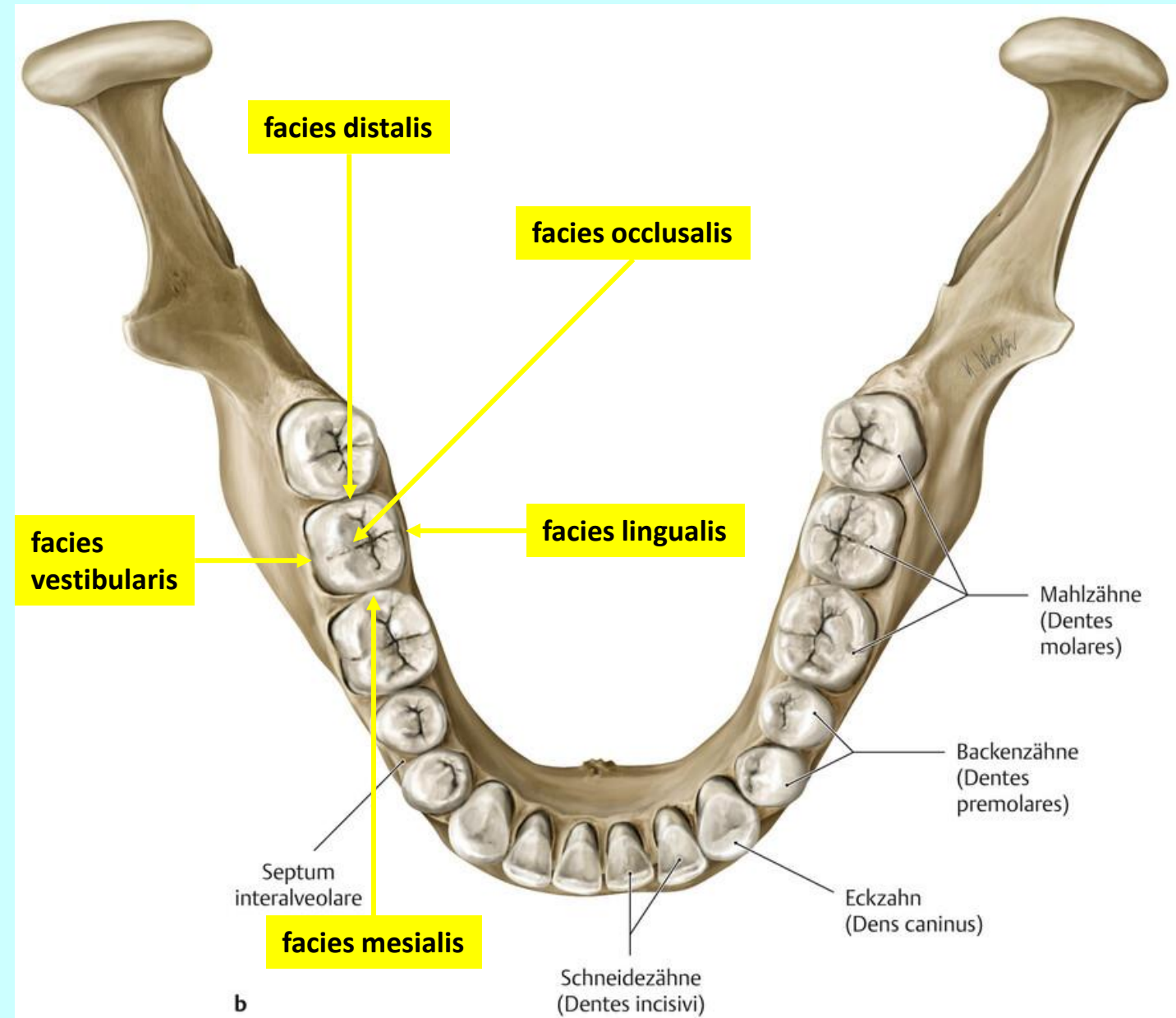
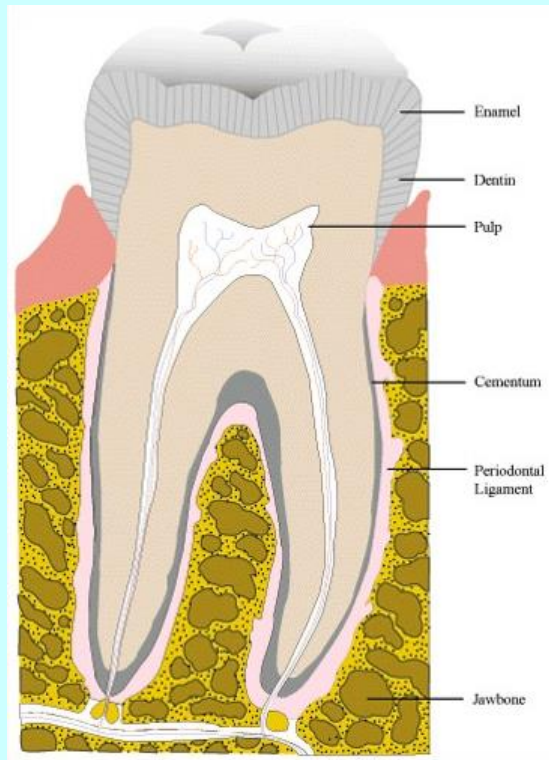
gingivodentální uzávěr



zuby (*dentes*)

makroskopická stavba

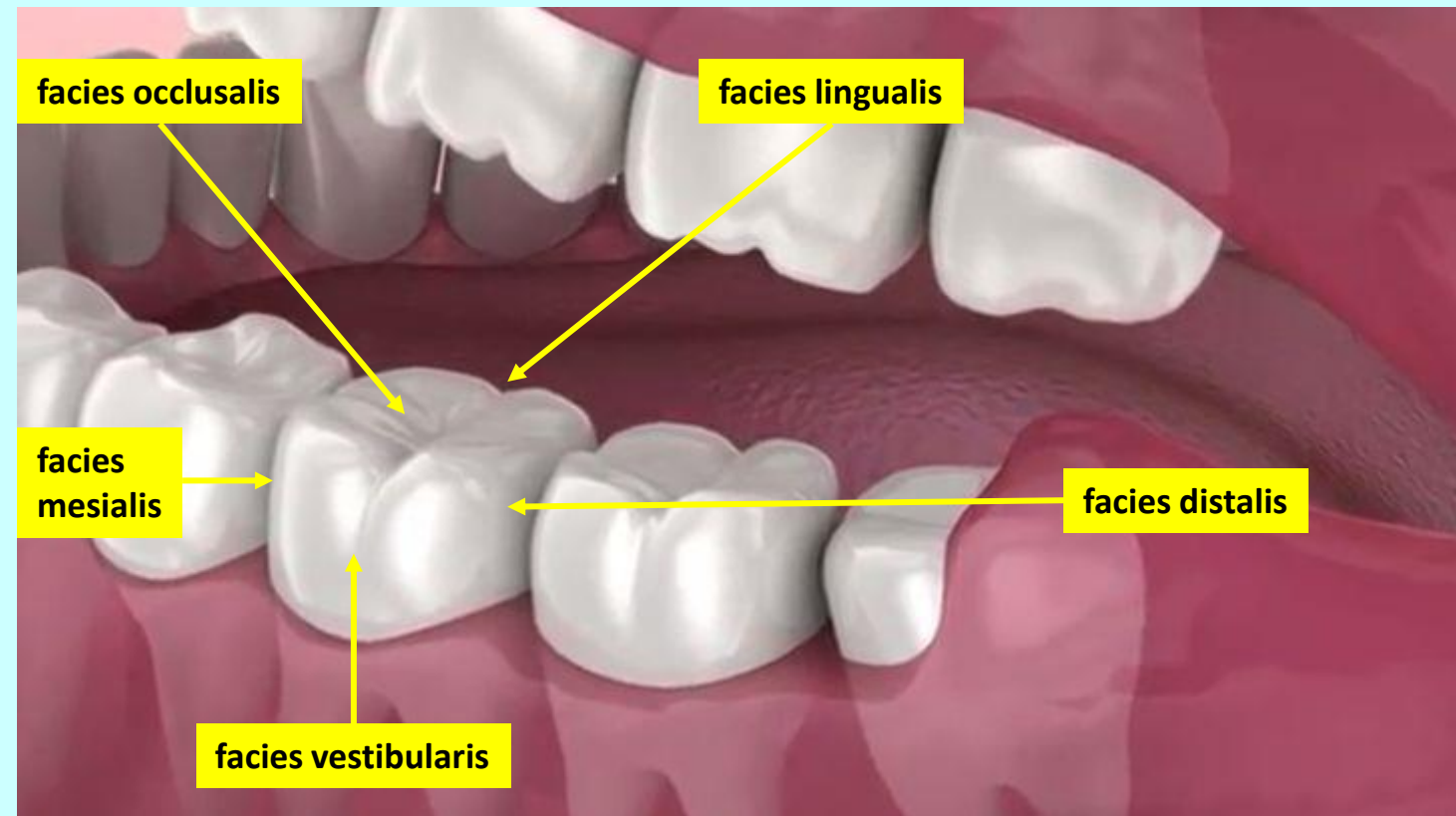
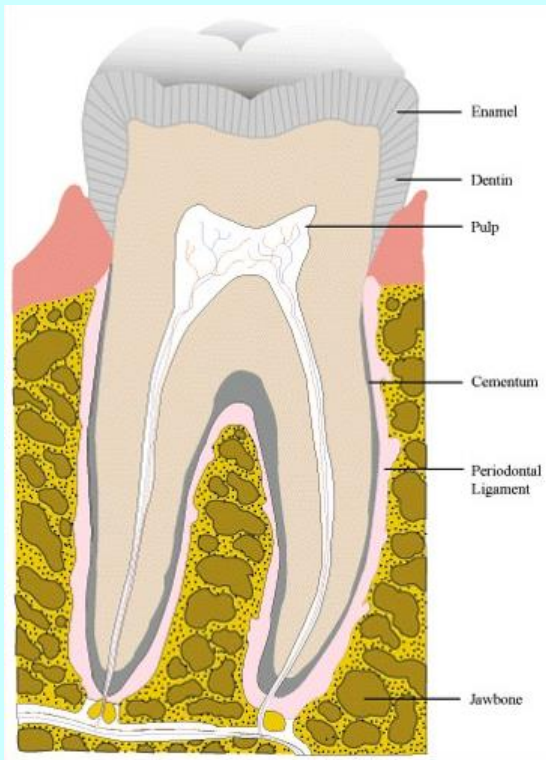
korunka



zuby (*dentes*)

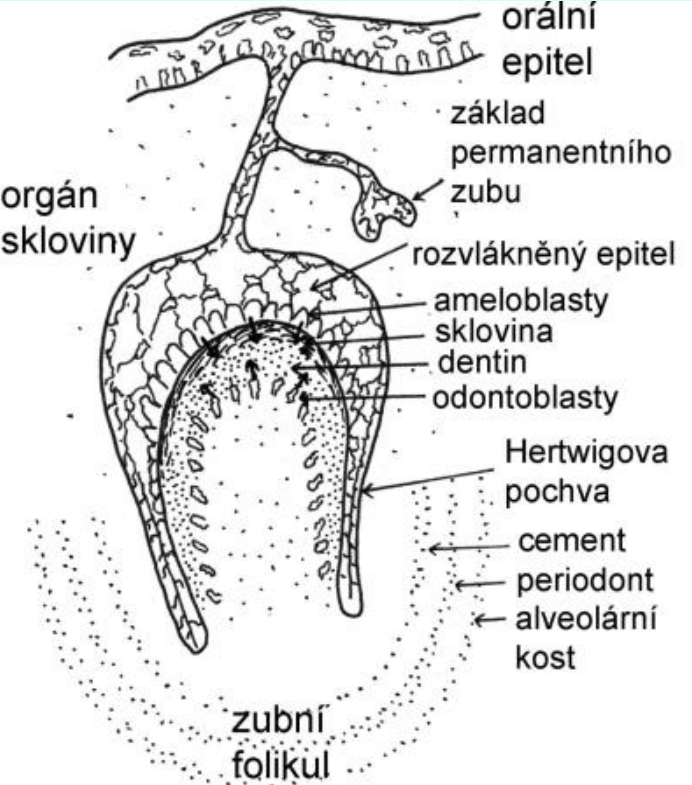
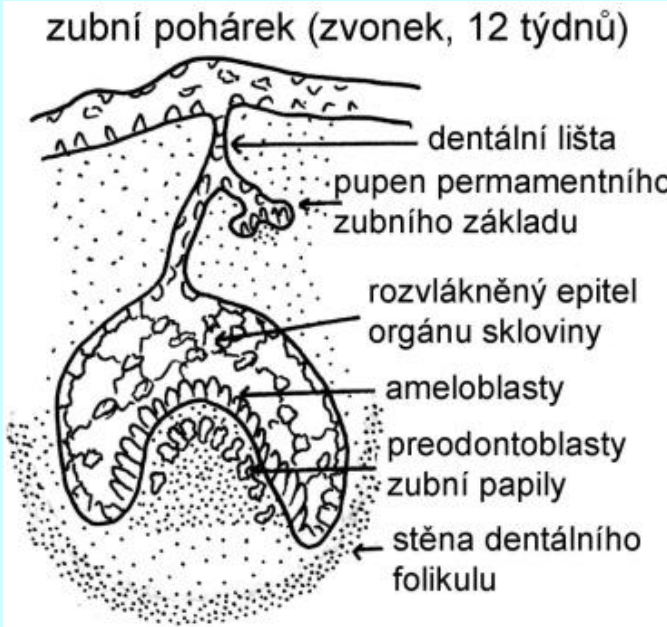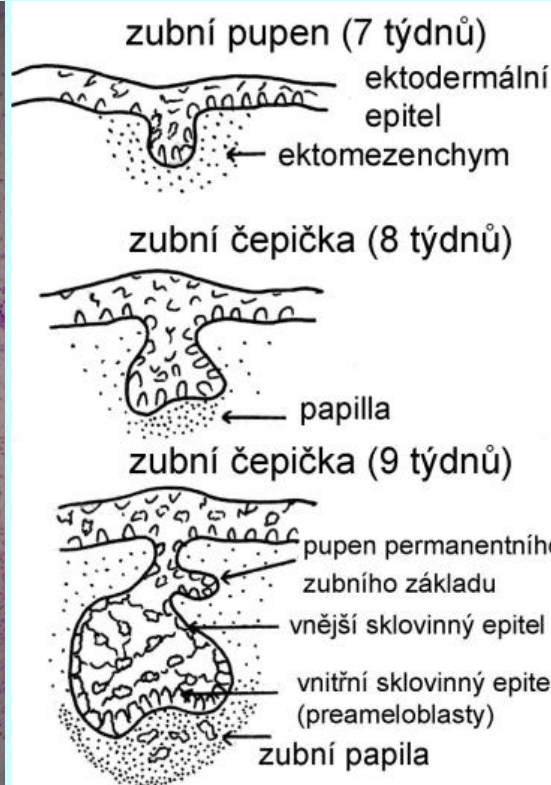
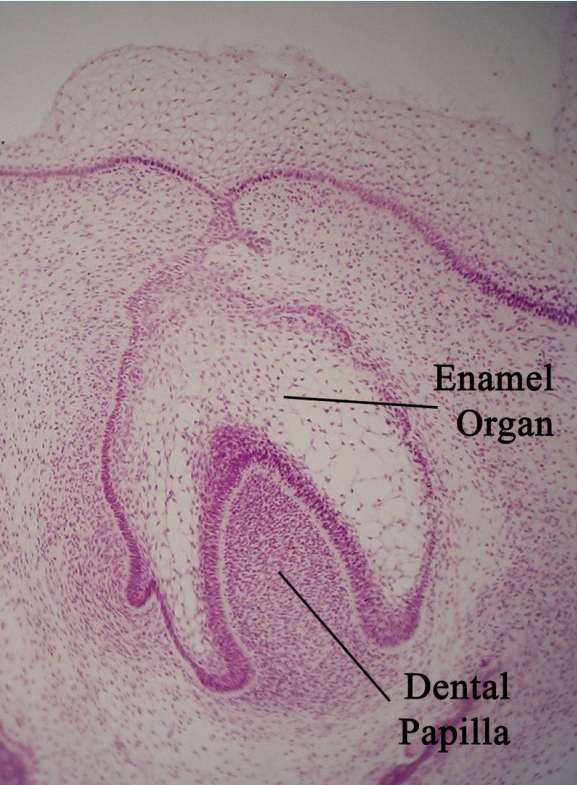
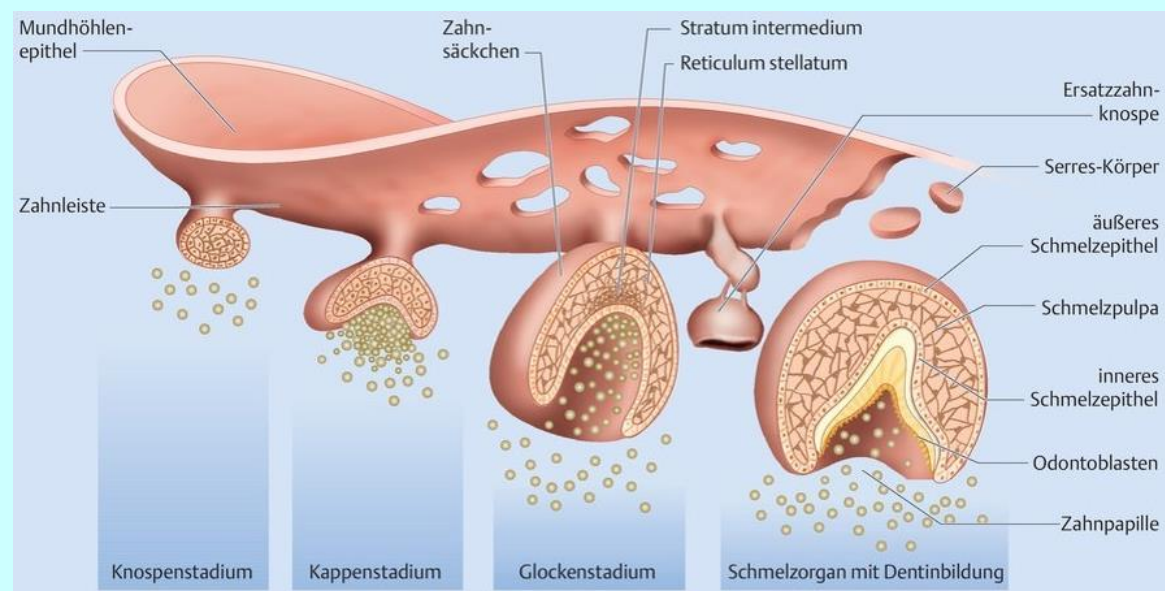
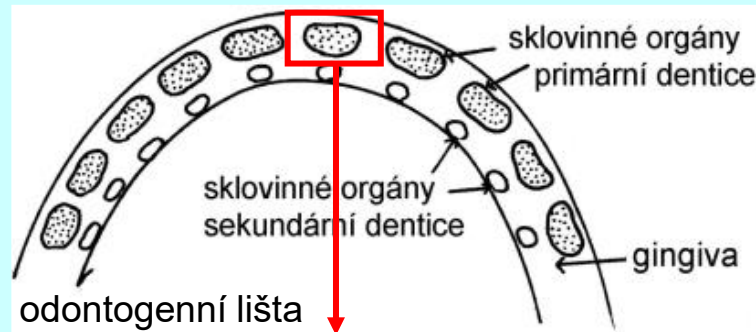makroskopická stavba

korunka



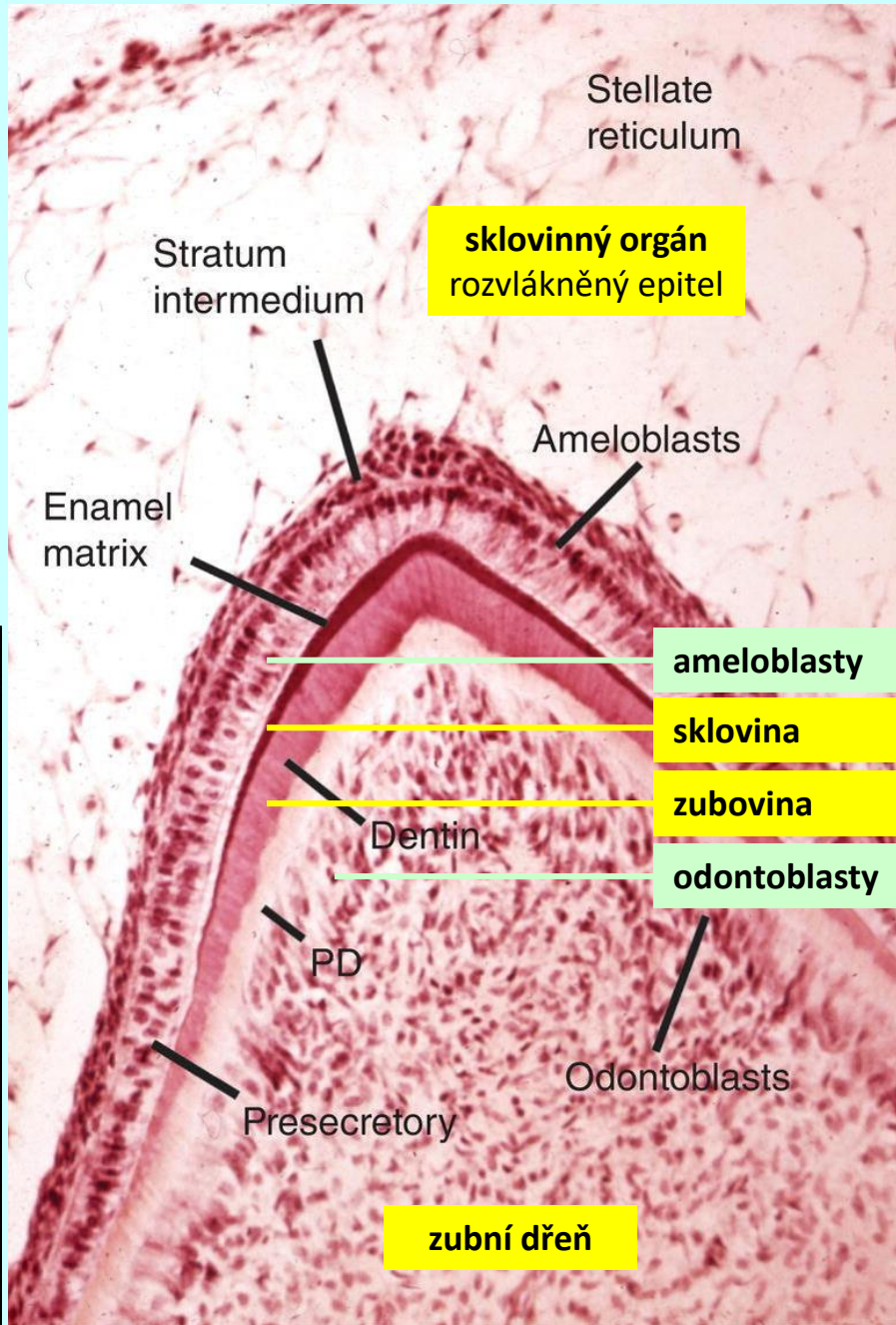
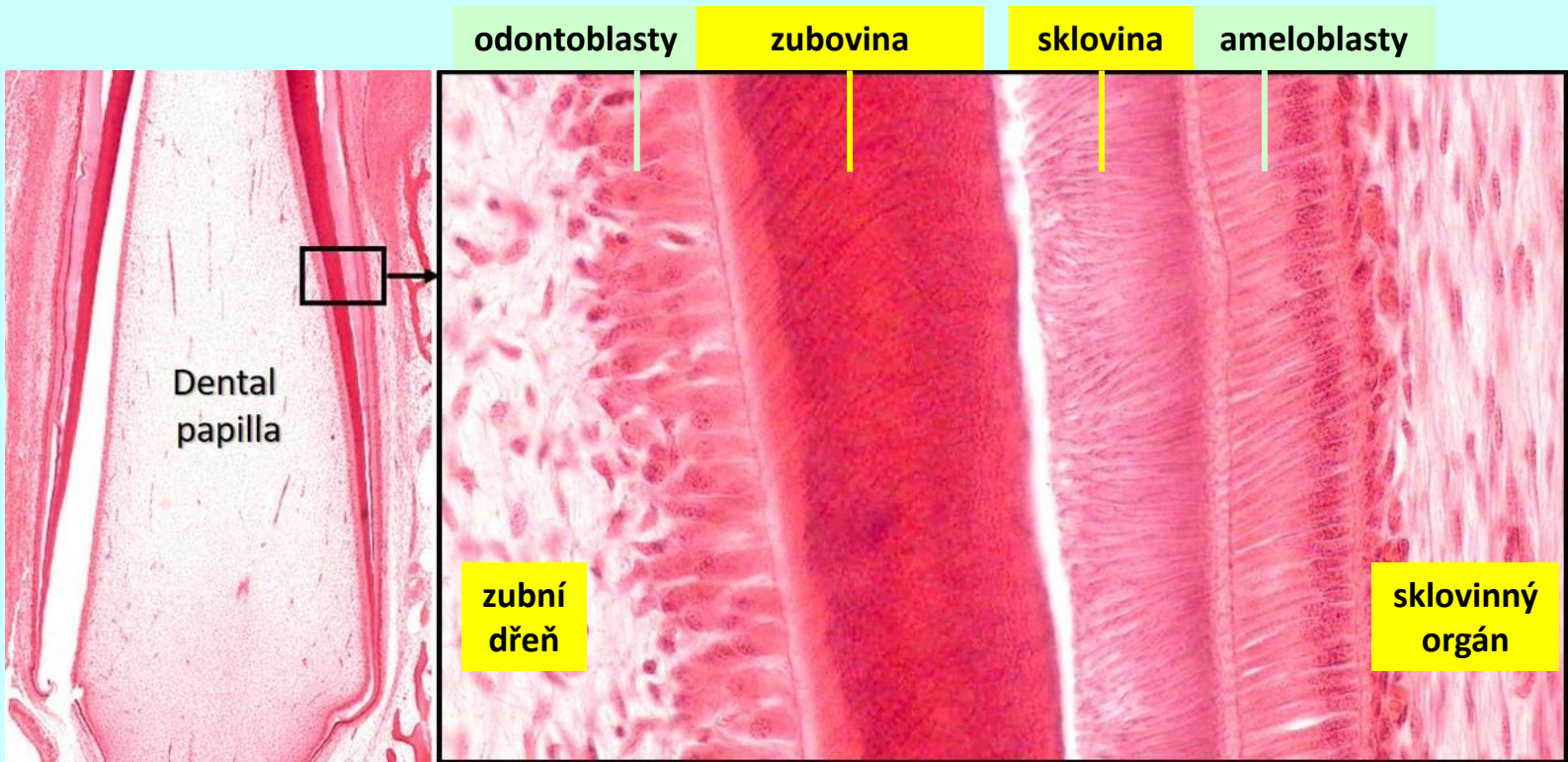
zuby (*dentes*)

histologie vývoj



zuby (dentes)

histologie
vývoj



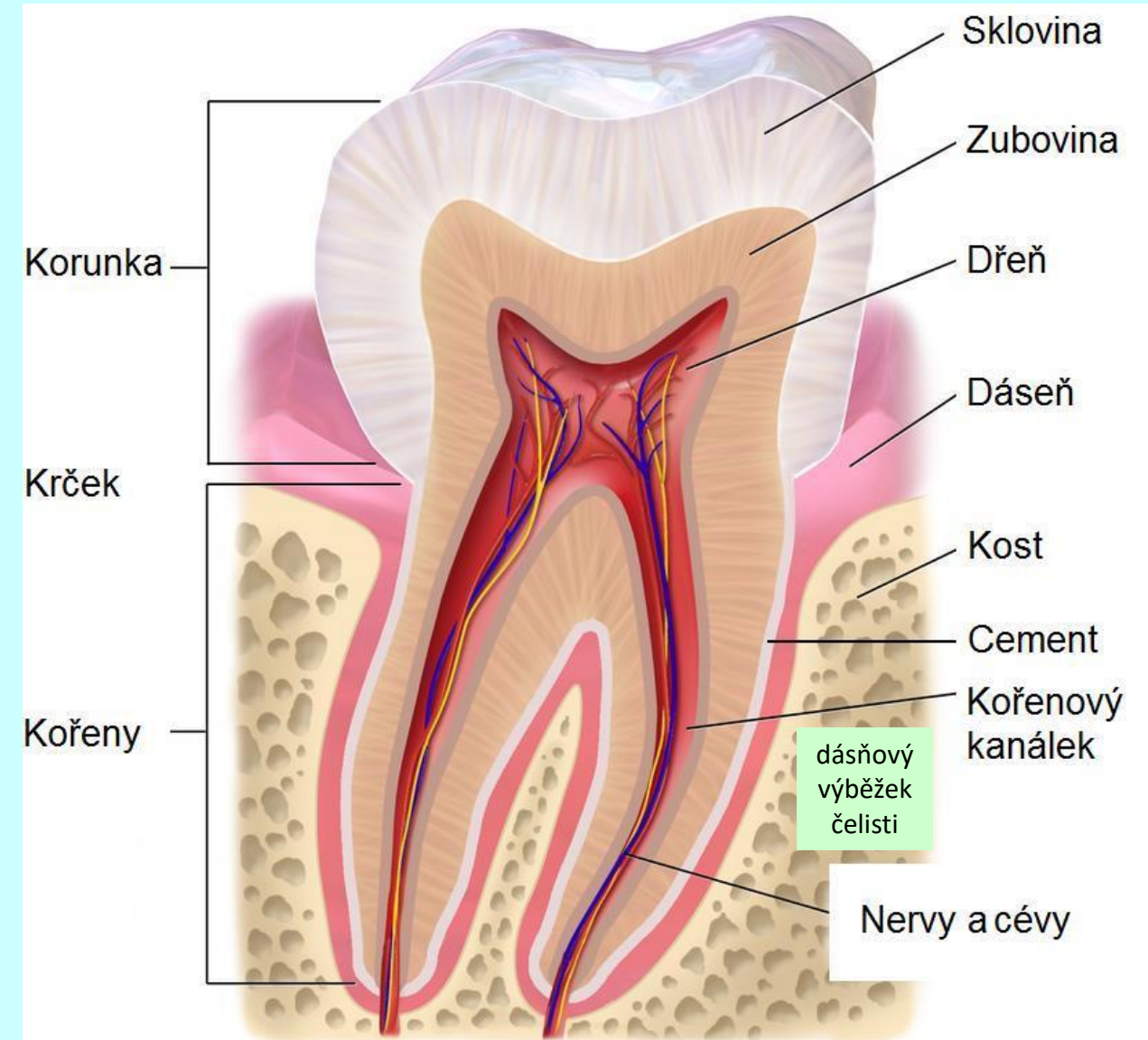
zuby (*dentes*)

histologická stavba

sklovina (*enamelum*)

cement (*cementum*)

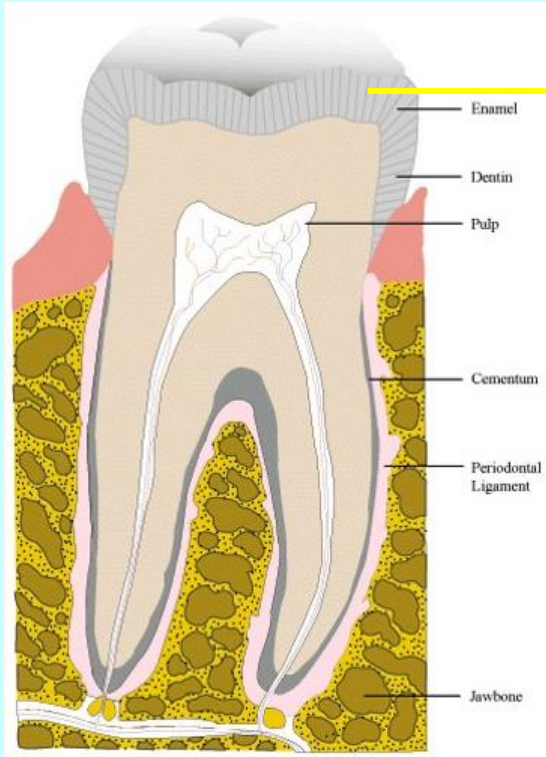
zubovina (*dentinum*)



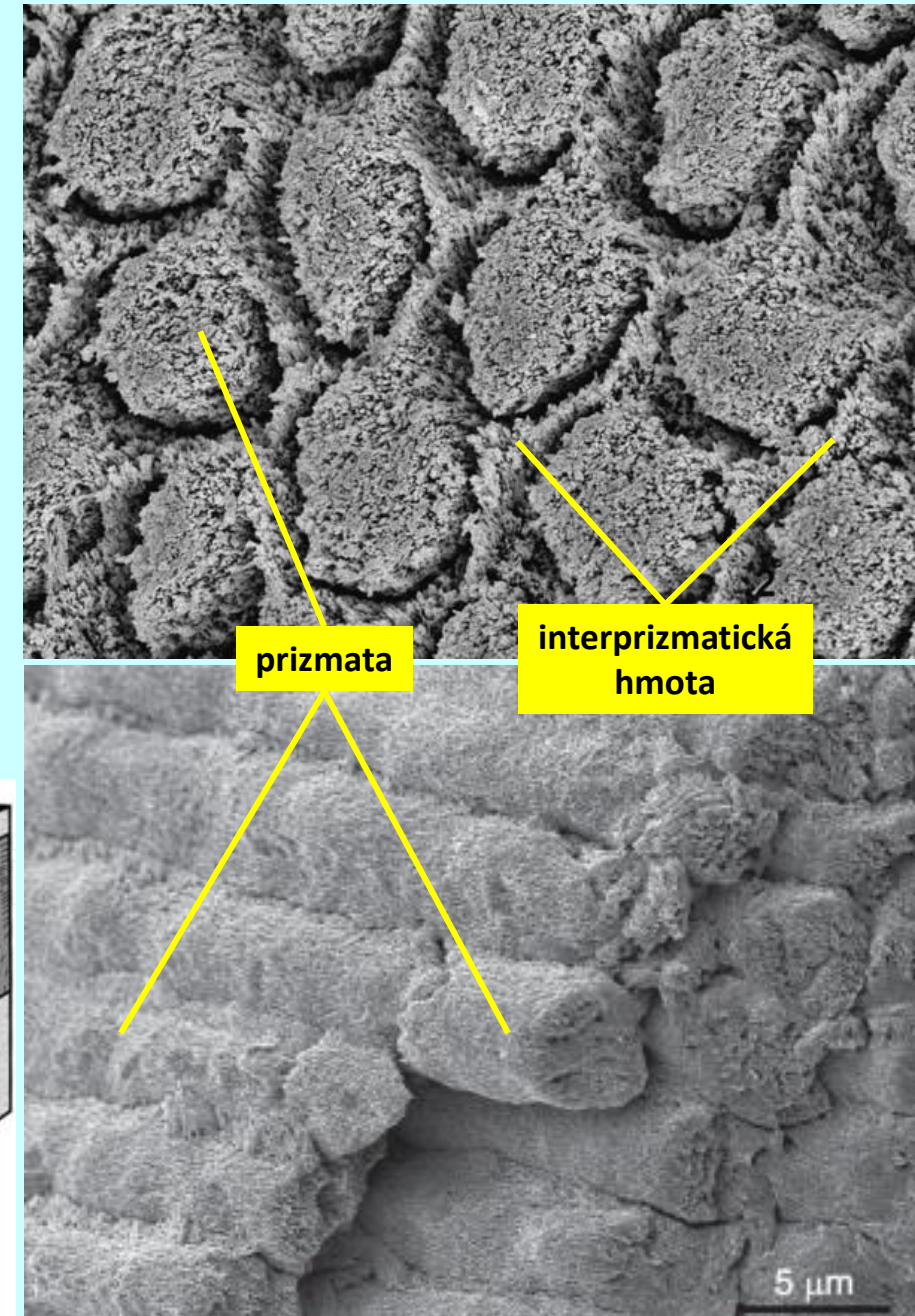
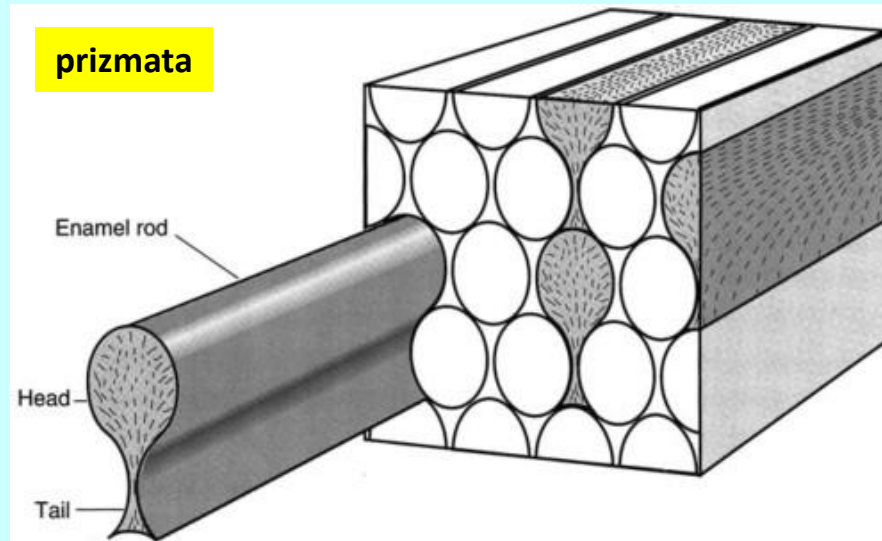
zuby (*dentes*)

histologická stavba

sklovina (*enamelum*)



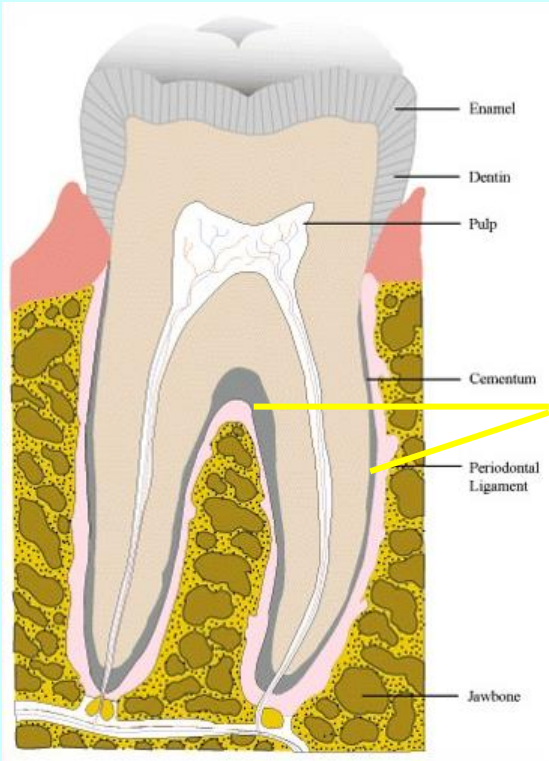
sklovina



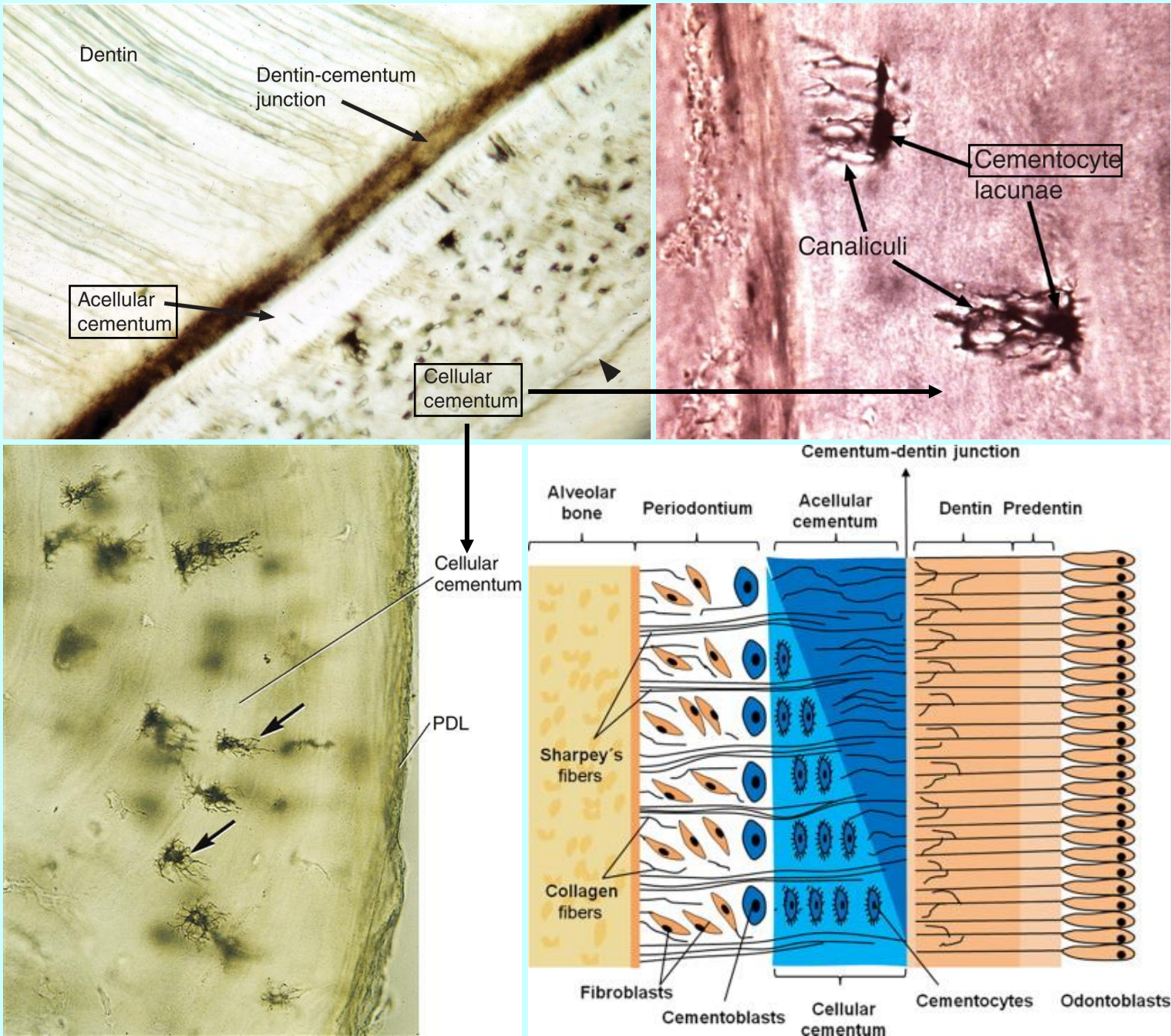
zuby (*dentes*)

histologická stavba

cement (*cementum*)

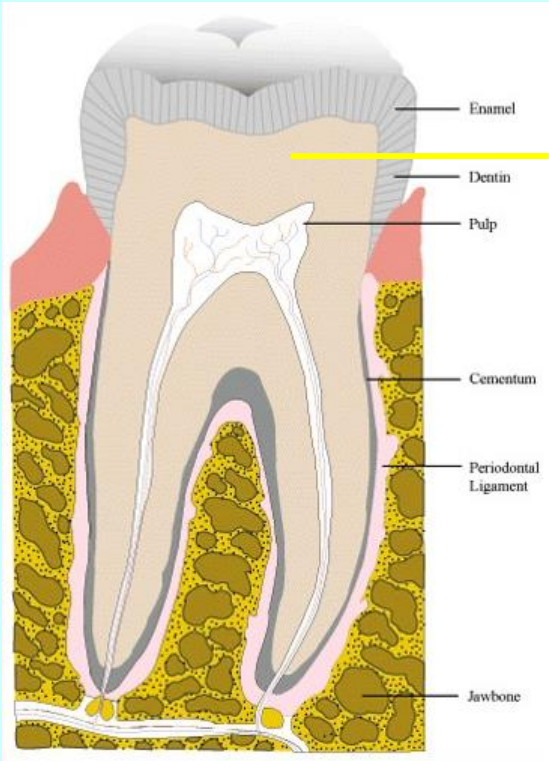


cement




zuby (*dentes*)

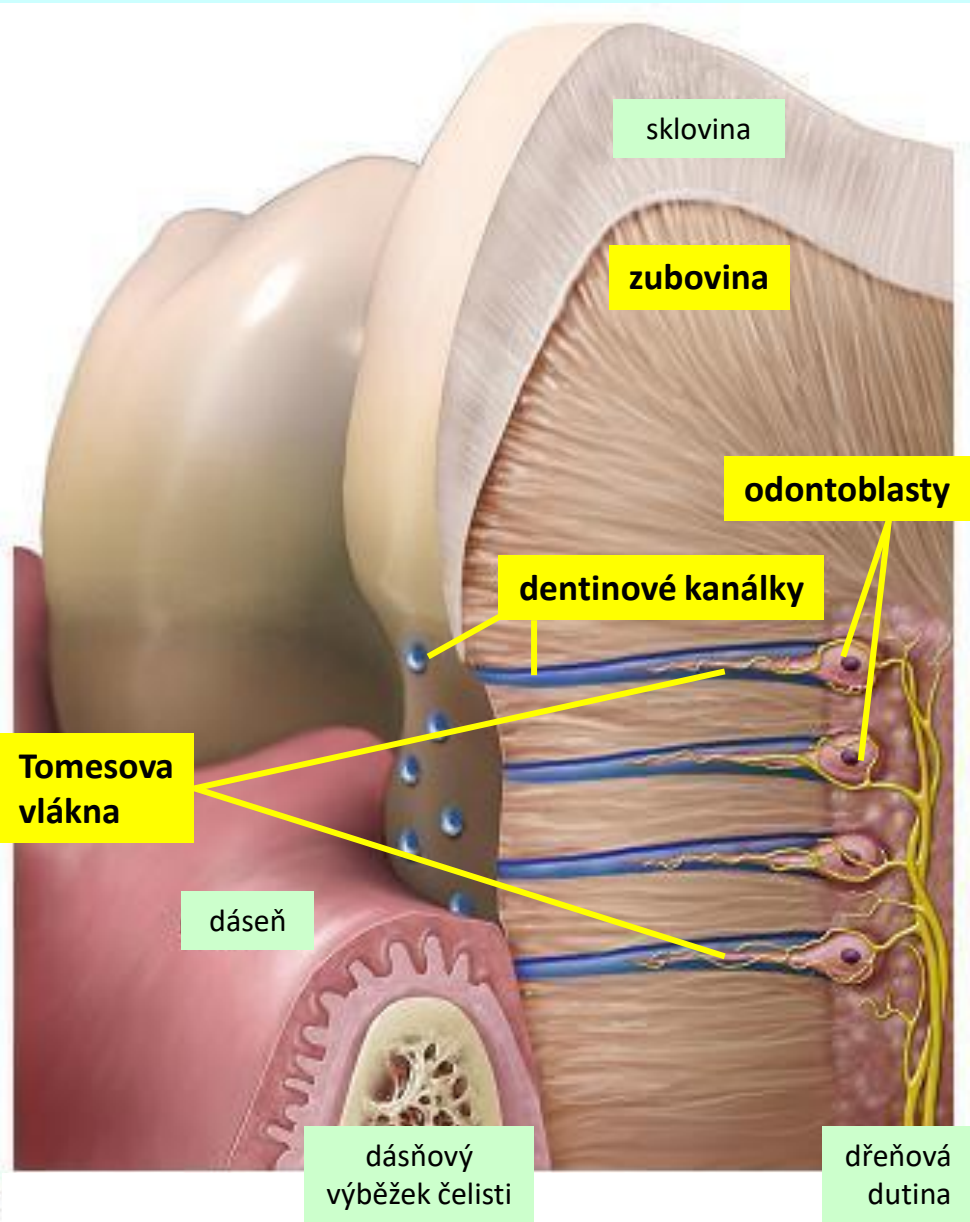
histologická stavba zubovina (*dentinum*)



zubovina



dentínové kanálky



sklovina

zubovina

odontoblasty

dentínové kanálky

Tomesova vlákna

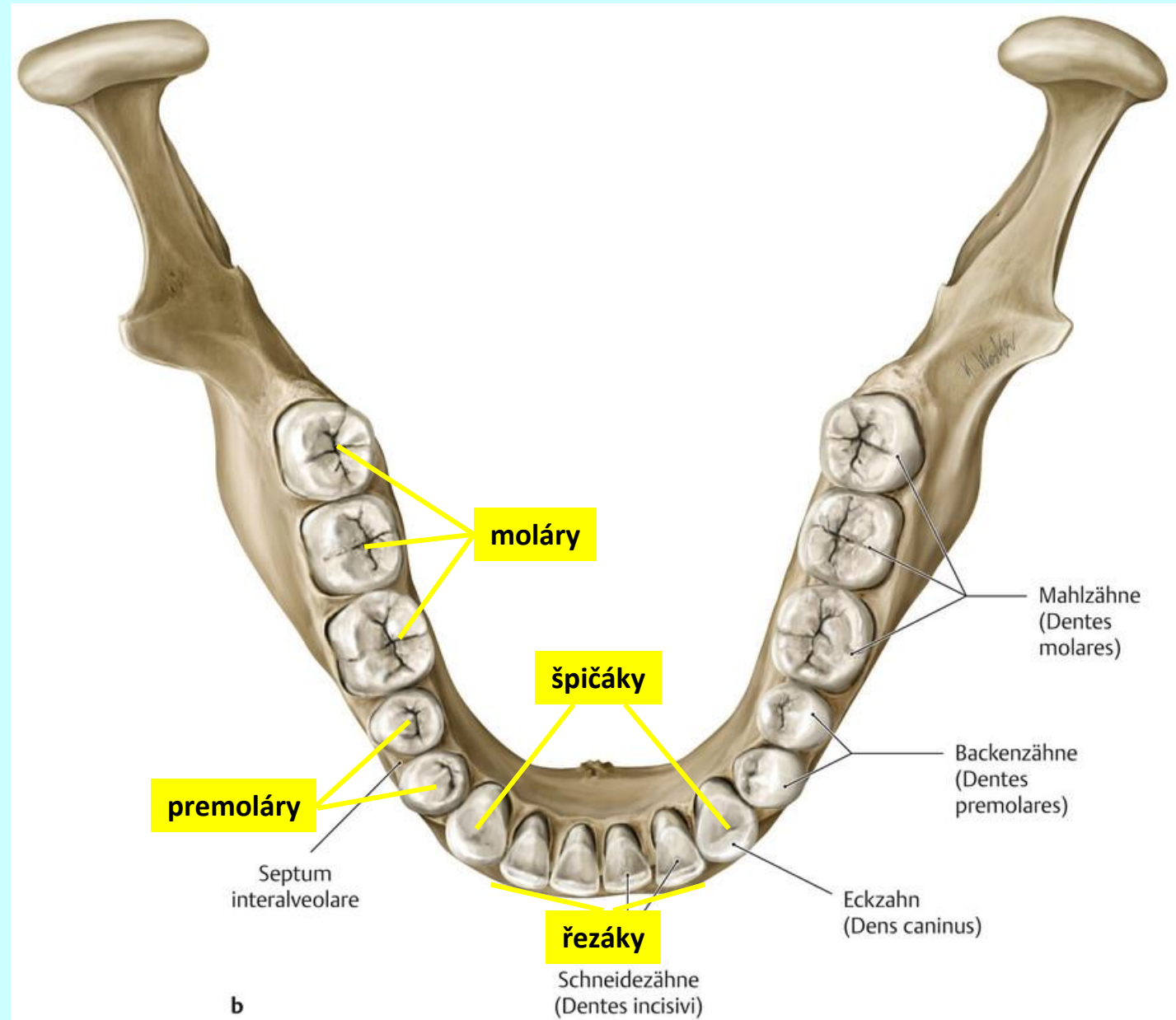
dásen

dásňový
výběžek čelisti

dřeňová
dutina

zuby (*dentes*)

typy zubů

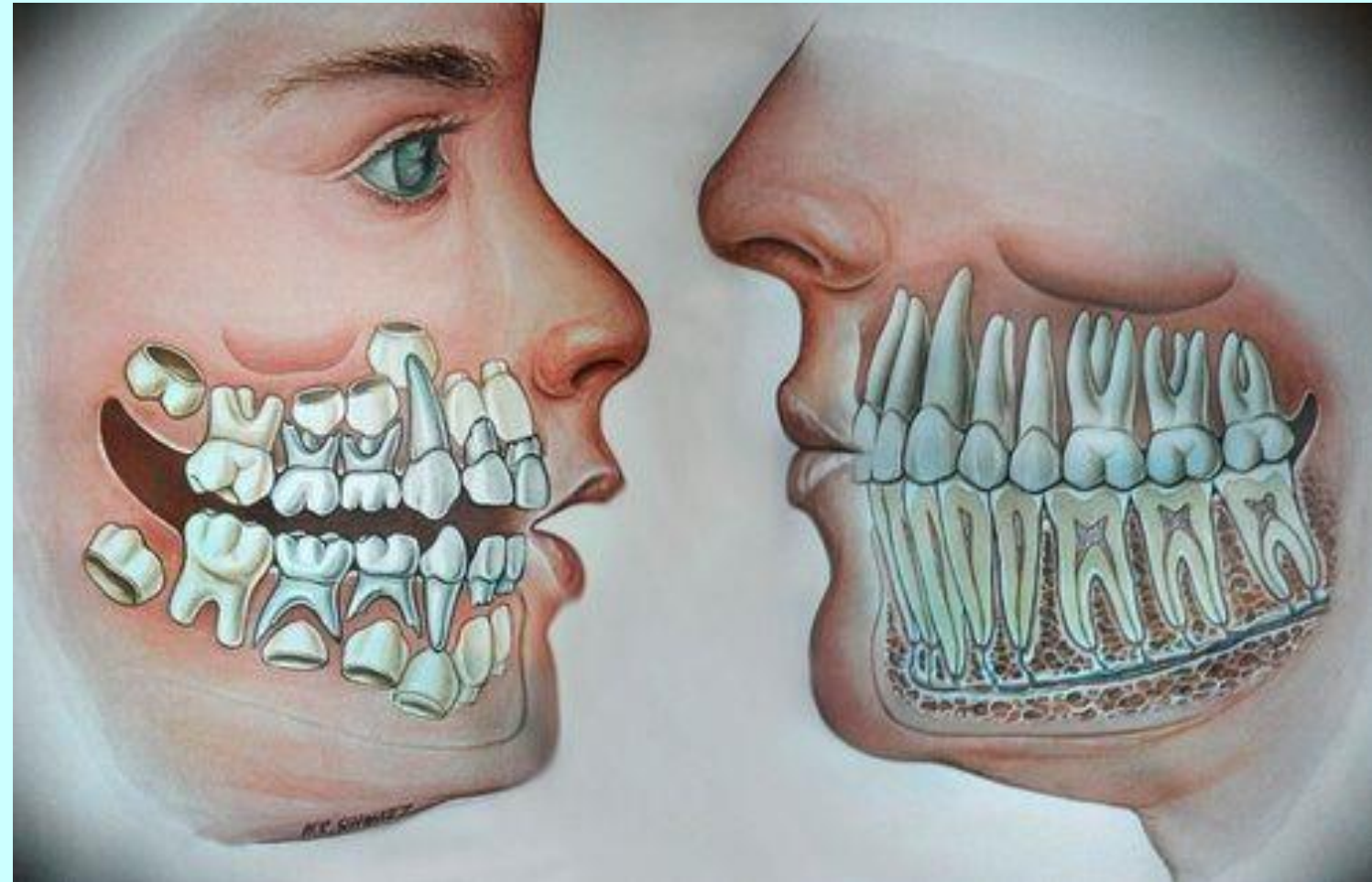


zuby (*dentes*)

generace chrupu

mléčné zuby (*dentes decidui*)

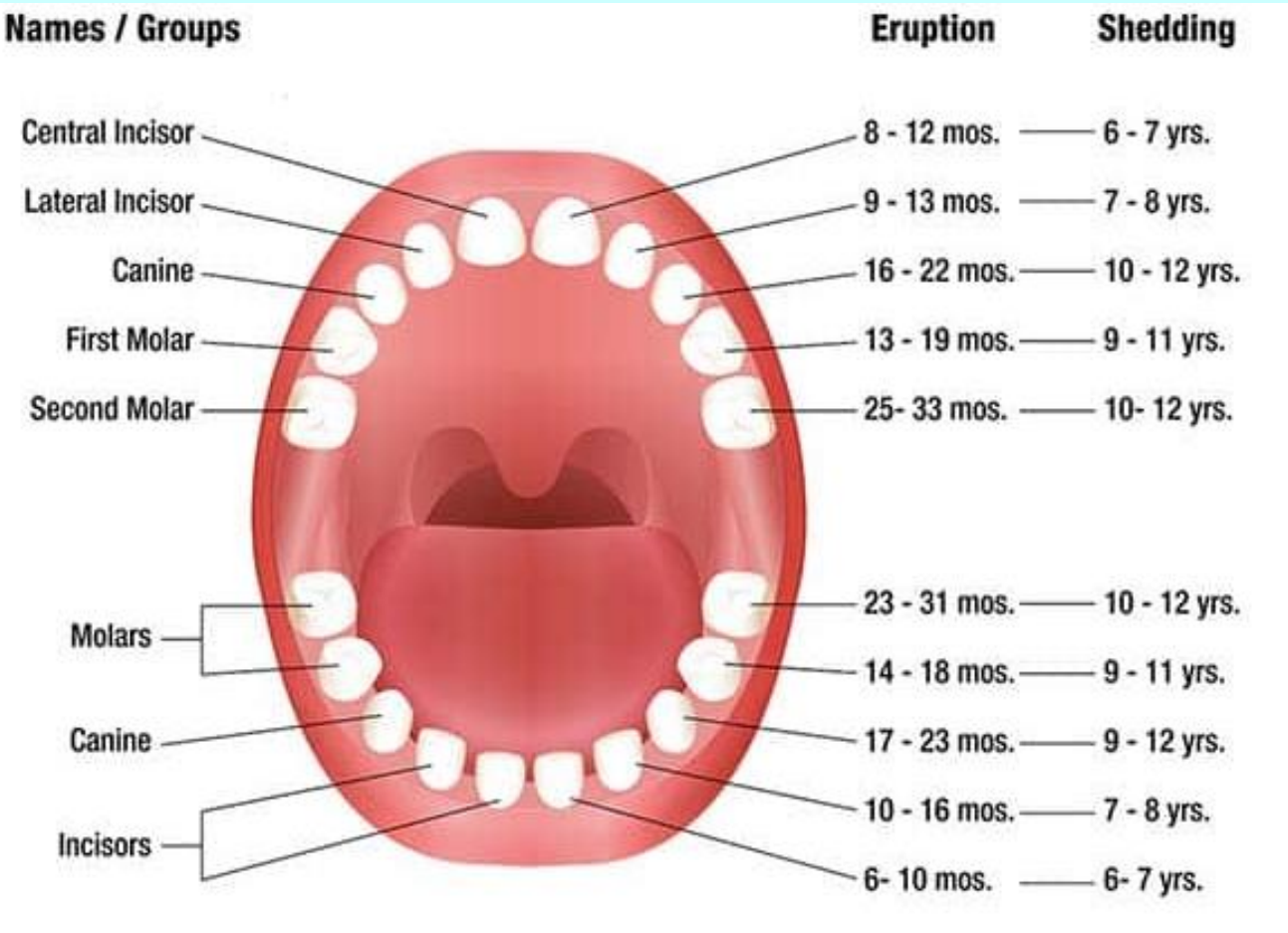
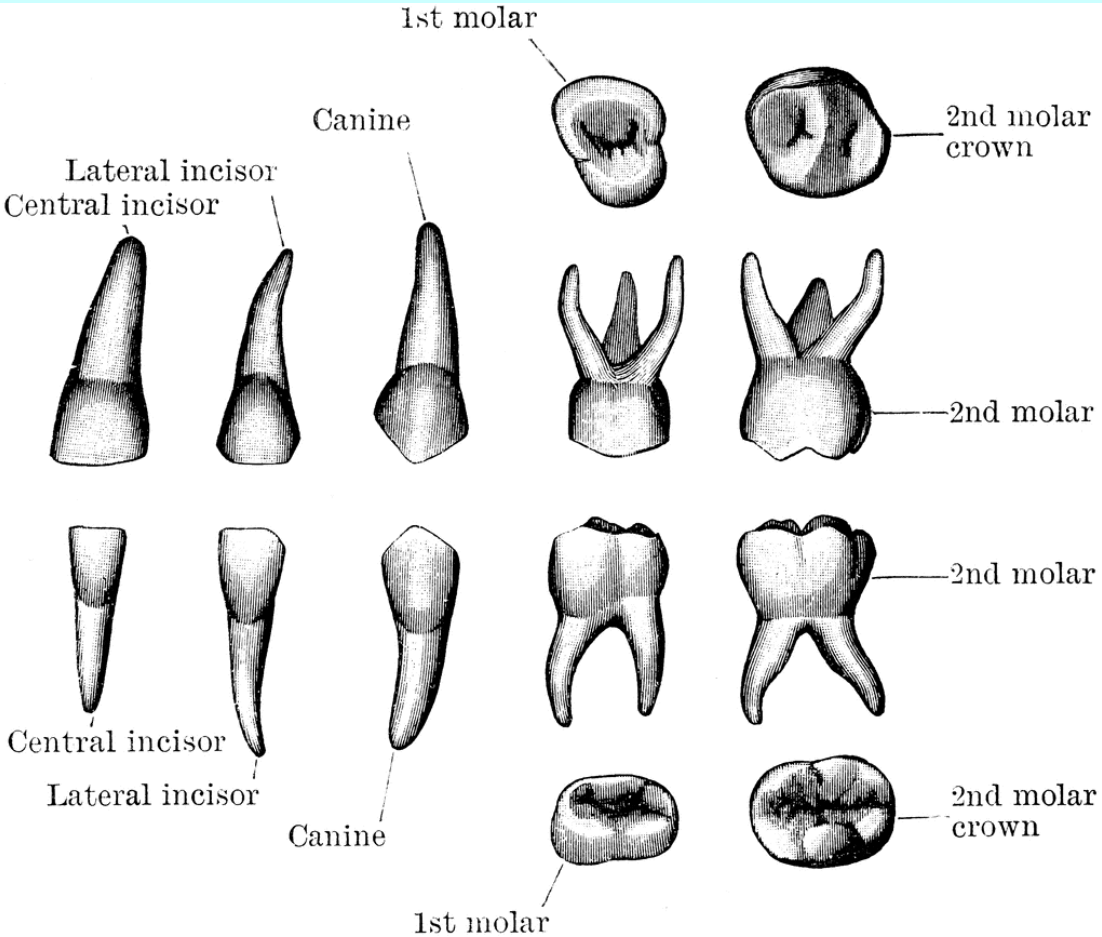
trvalé zuby (*dentes permanentes*)



zuby (*dentes*)

generace chrupu

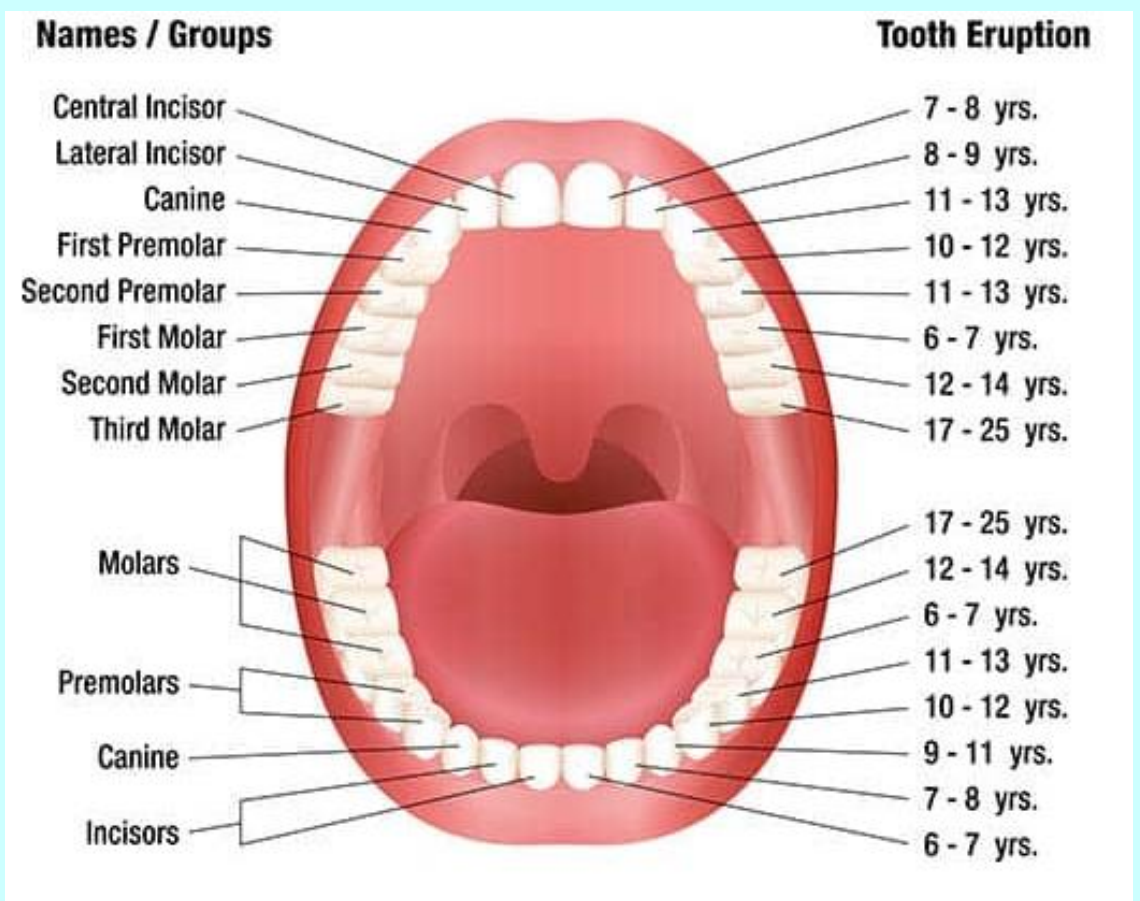
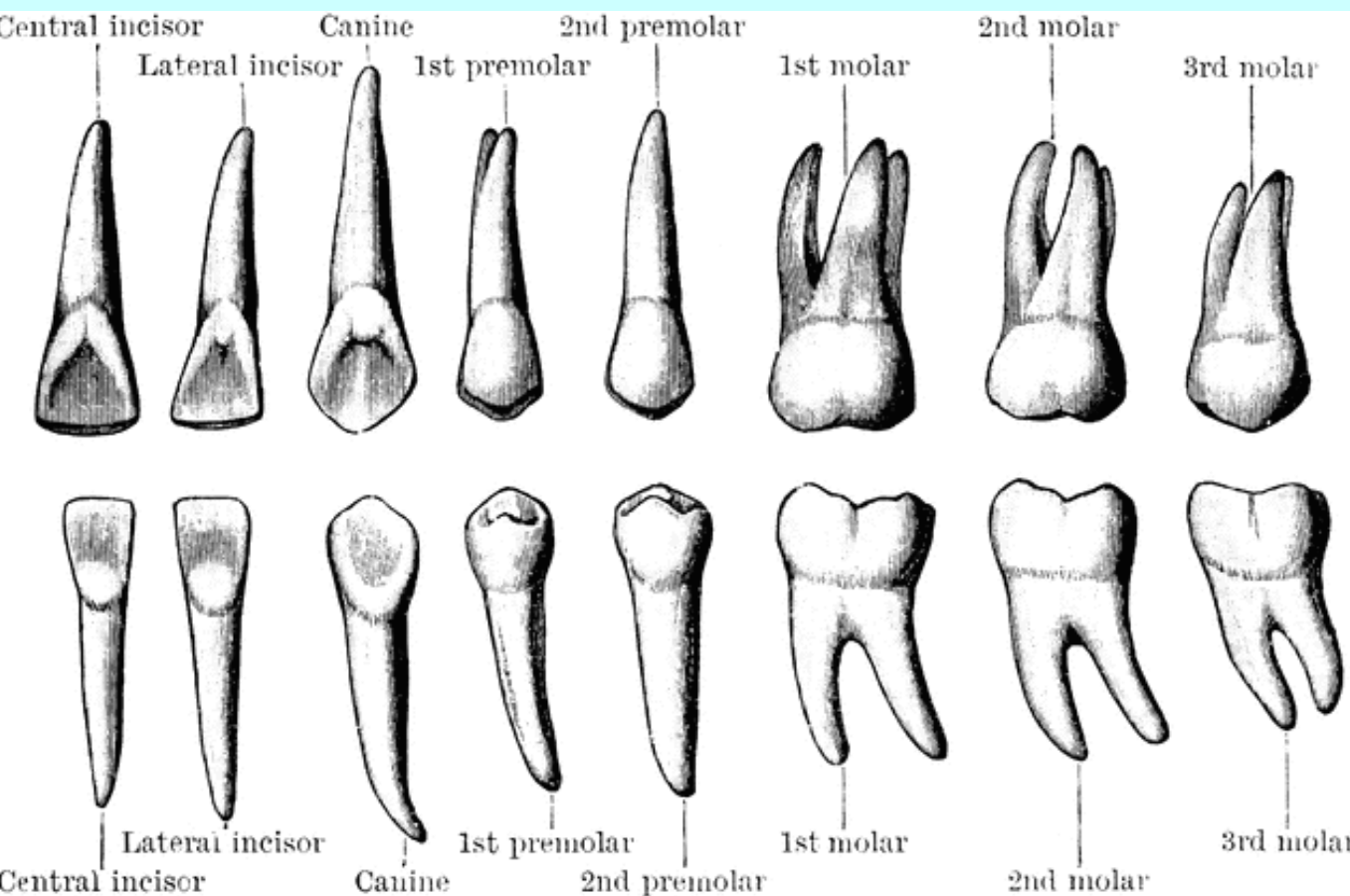
mléčné zuby (*dentes decidui*)



zuby (*dentes*)

generace chrupu

trvalé zuby (*dentes permanentes*)



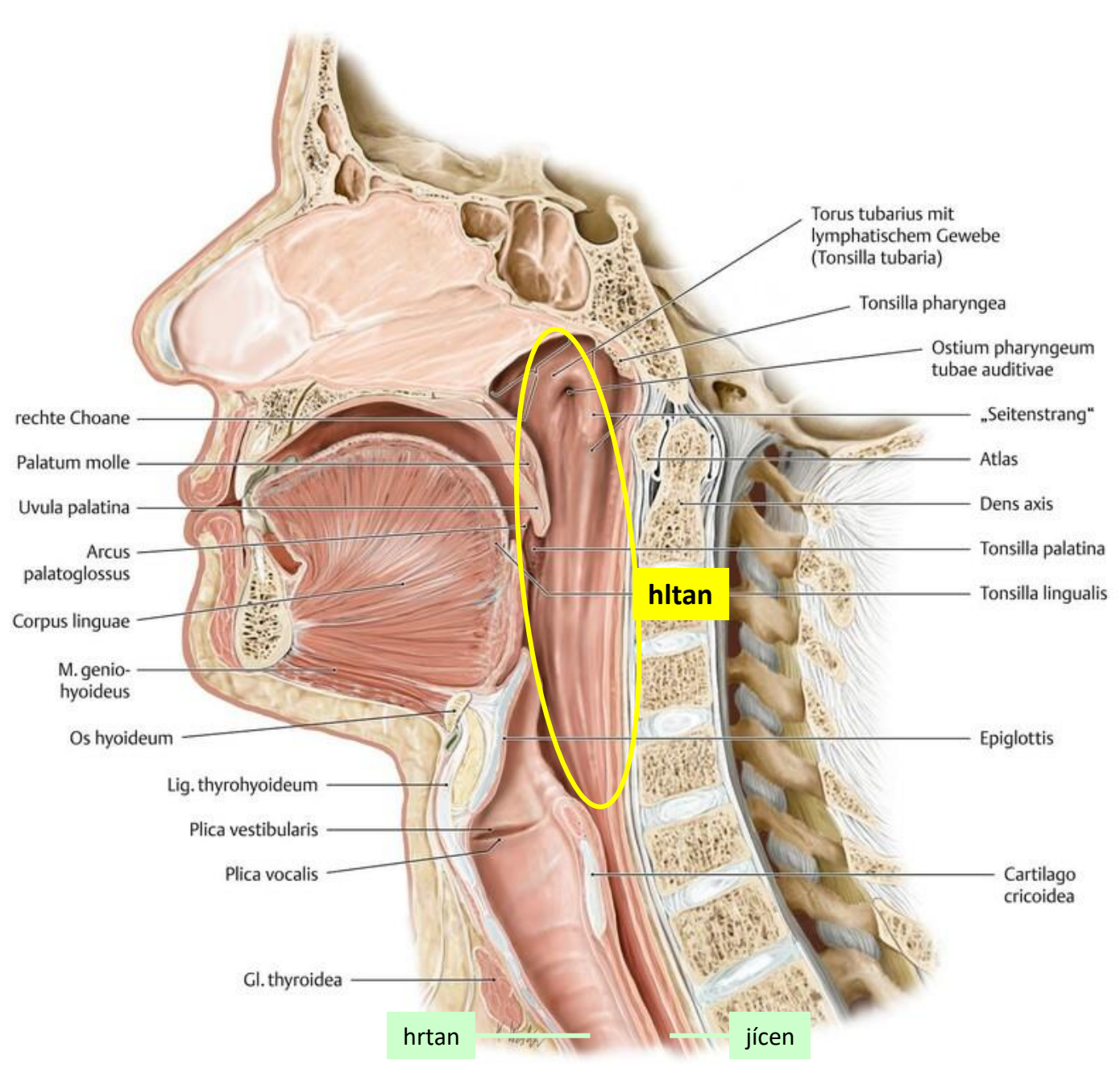
TRÁVICÍ SOUSTAVA

(Systema digestorium)

vlastní trávicí trubice
(canalis alimentarius)

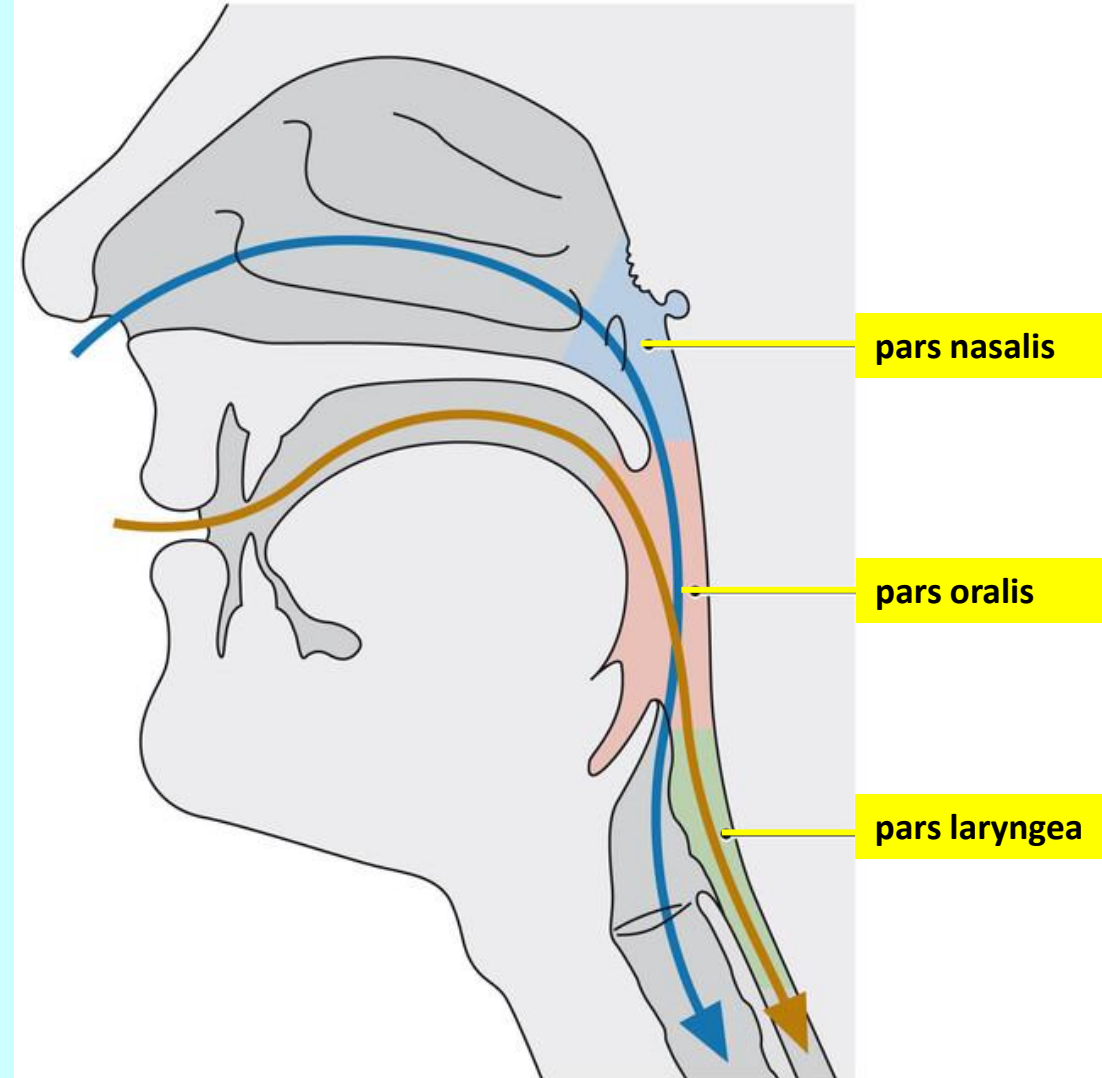
hltan (pharynx)

topografie



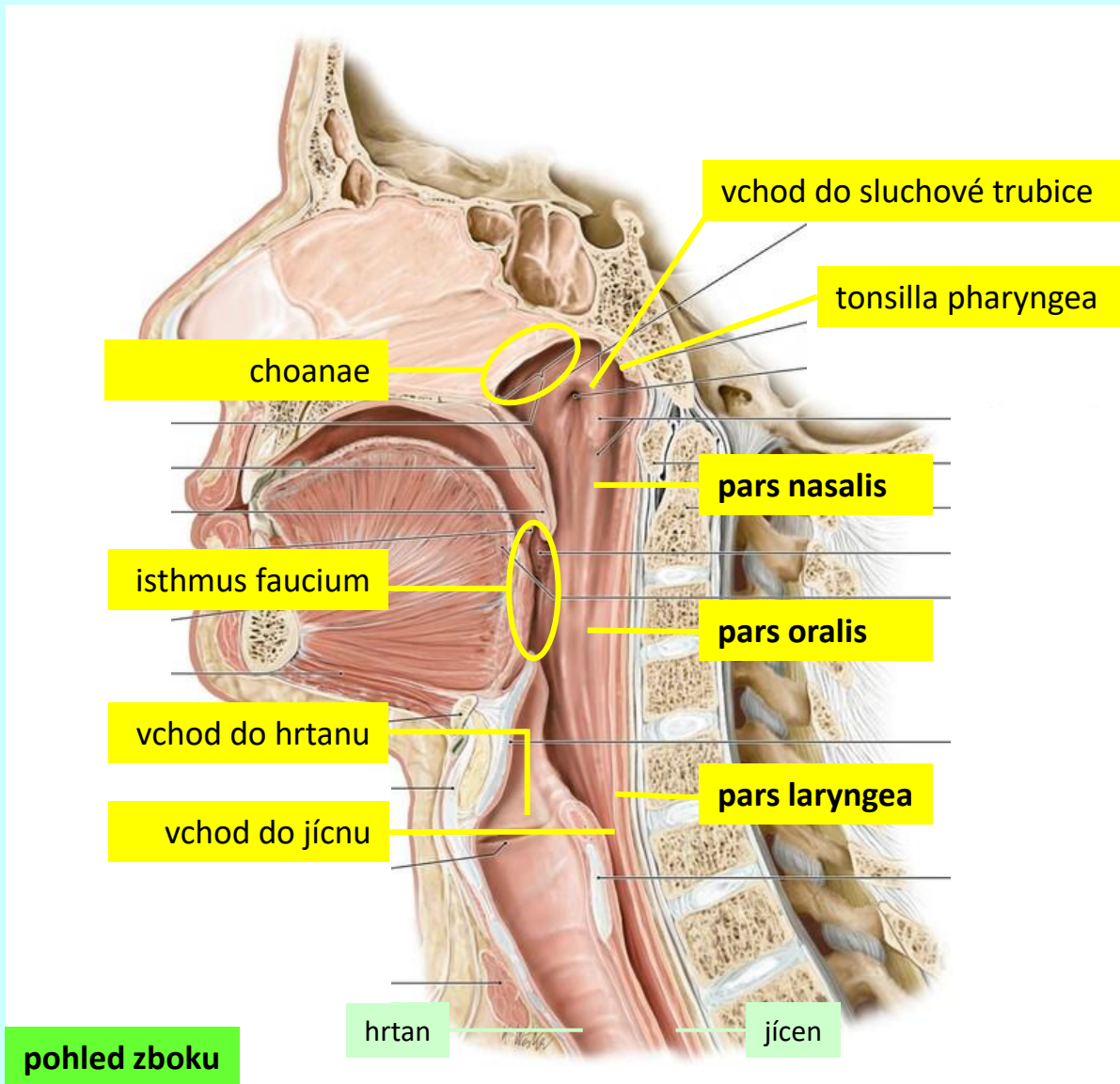
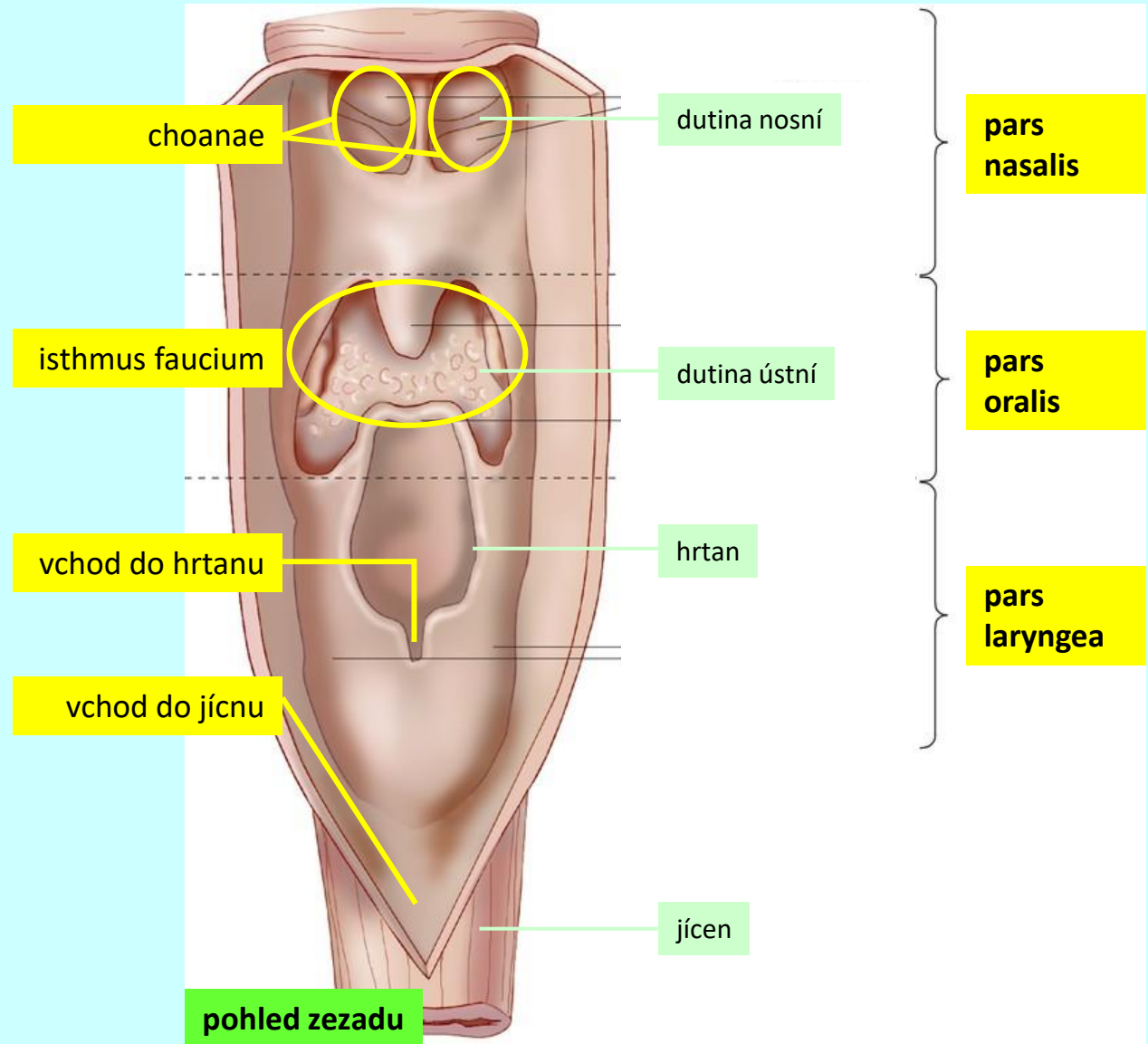
hltan (*pharynx*)

makroskopická stavba



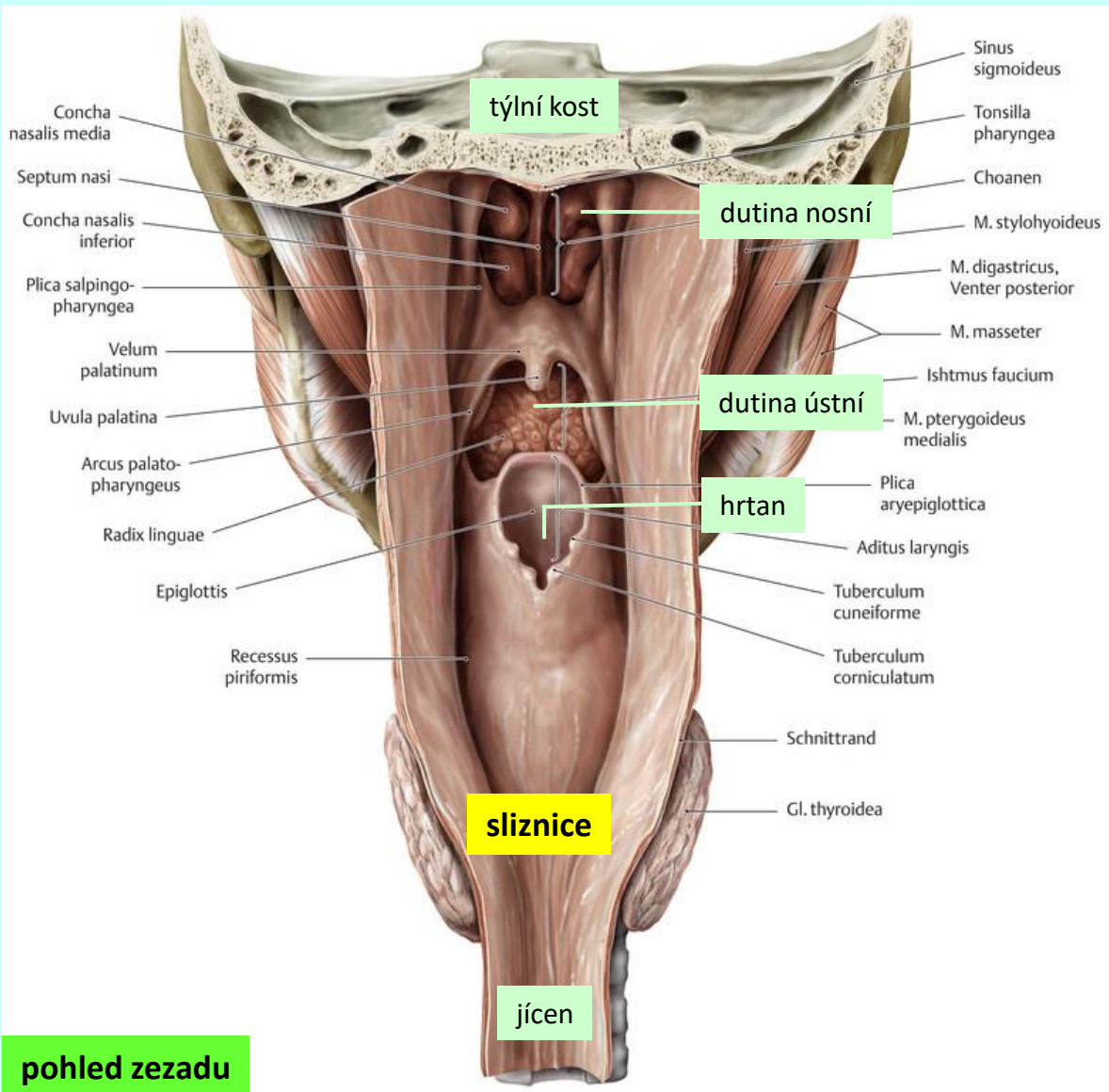
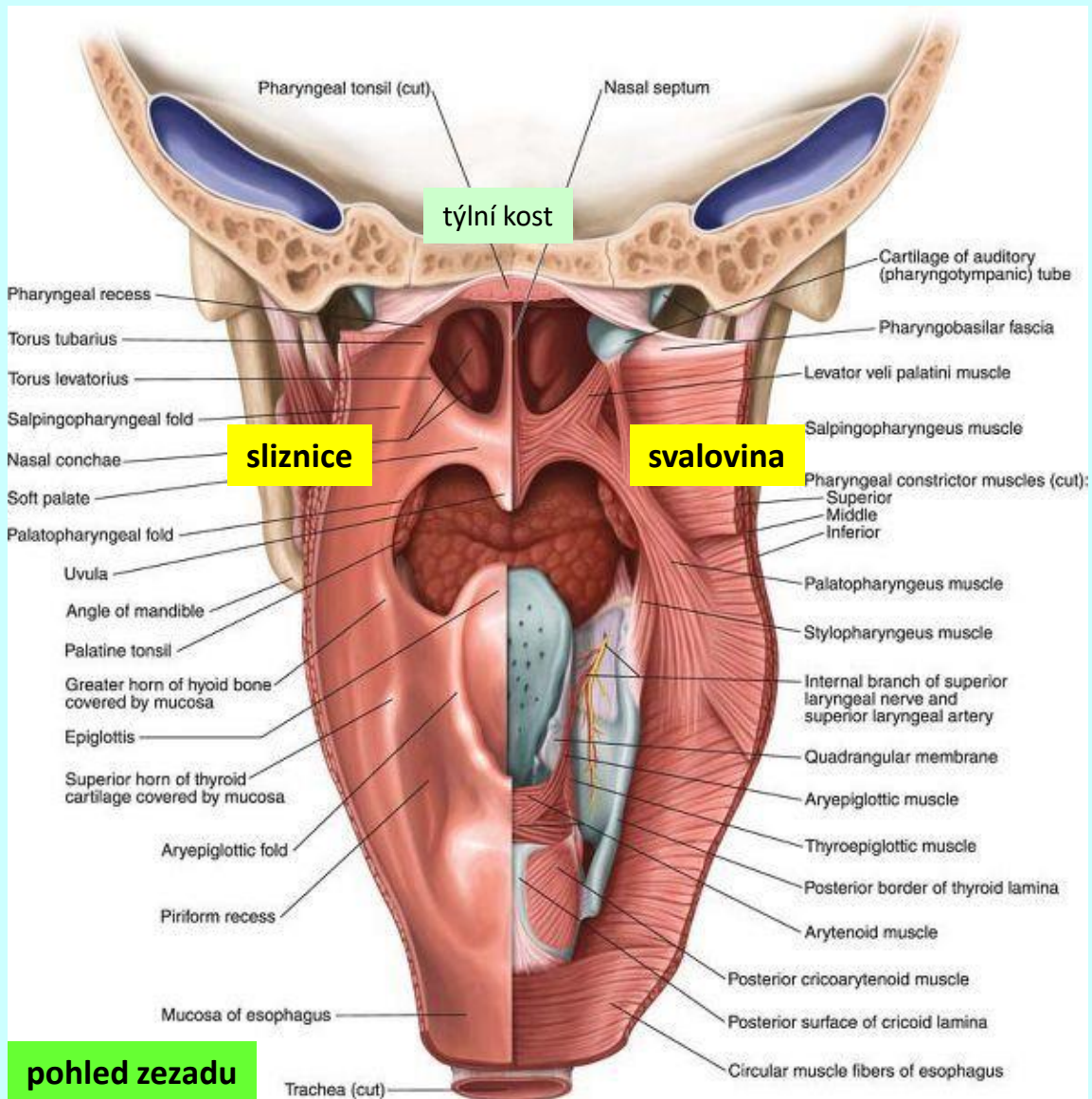
hltan (*pharynx*)

makroskopická stavba



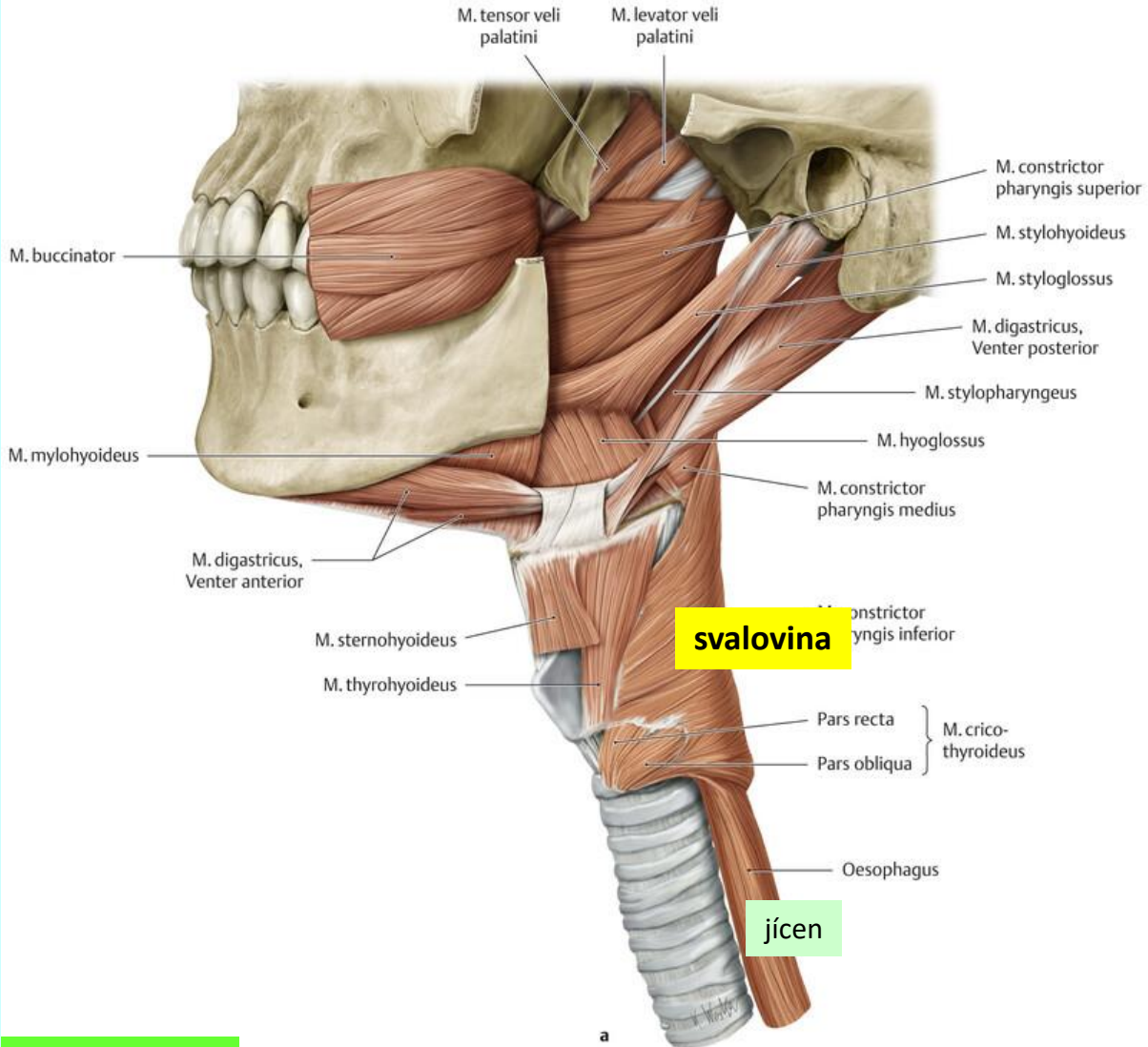
hltan (pharynx)

histologická stavba

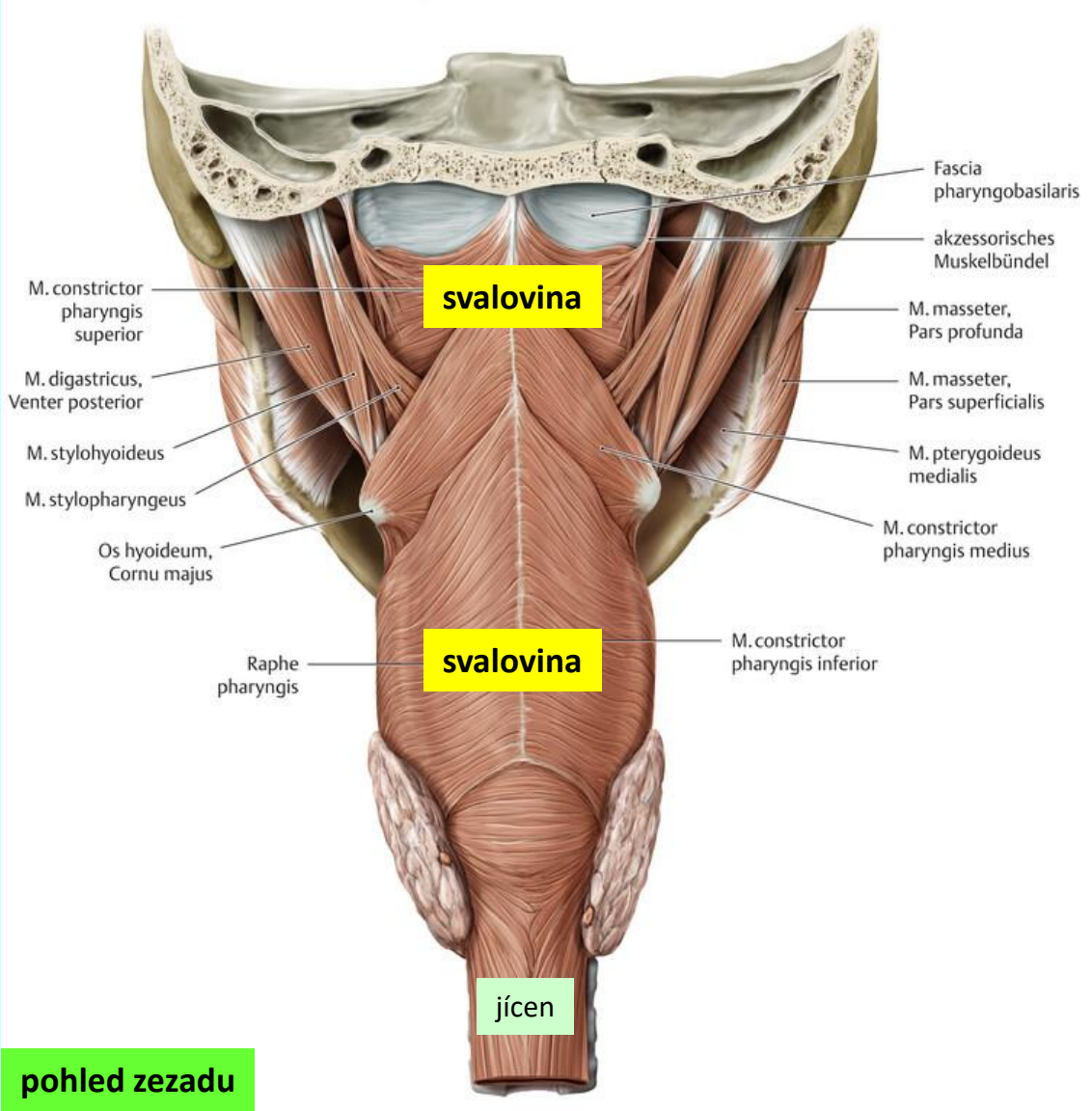


hltan (*pharynx*)

histologická stavba



pohled z boku

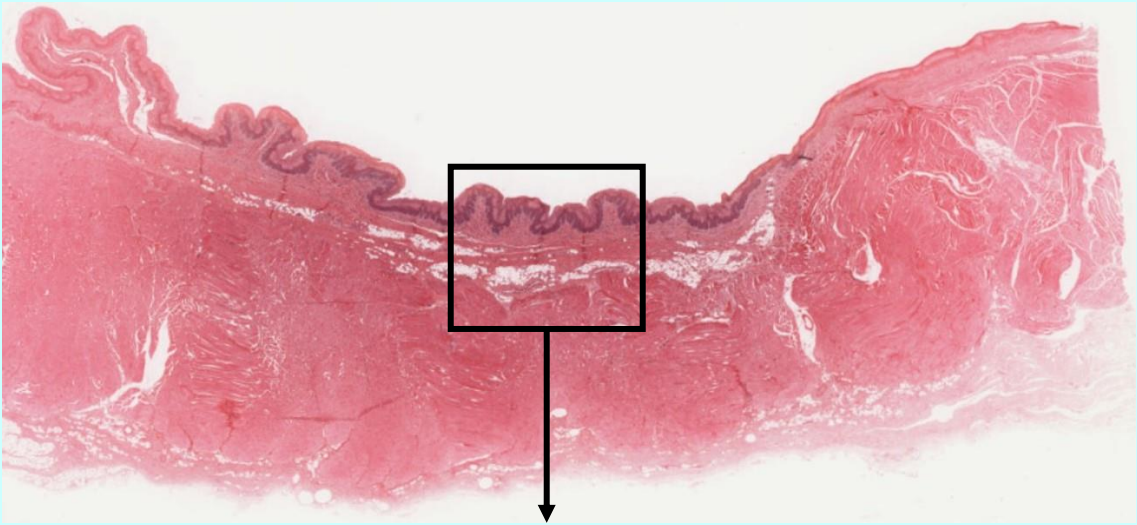


pohled zezadu

hltan (*pharynx*)

histologická stavba

pars oralis



Slide 155, pharynx, H&E, 4x obj.

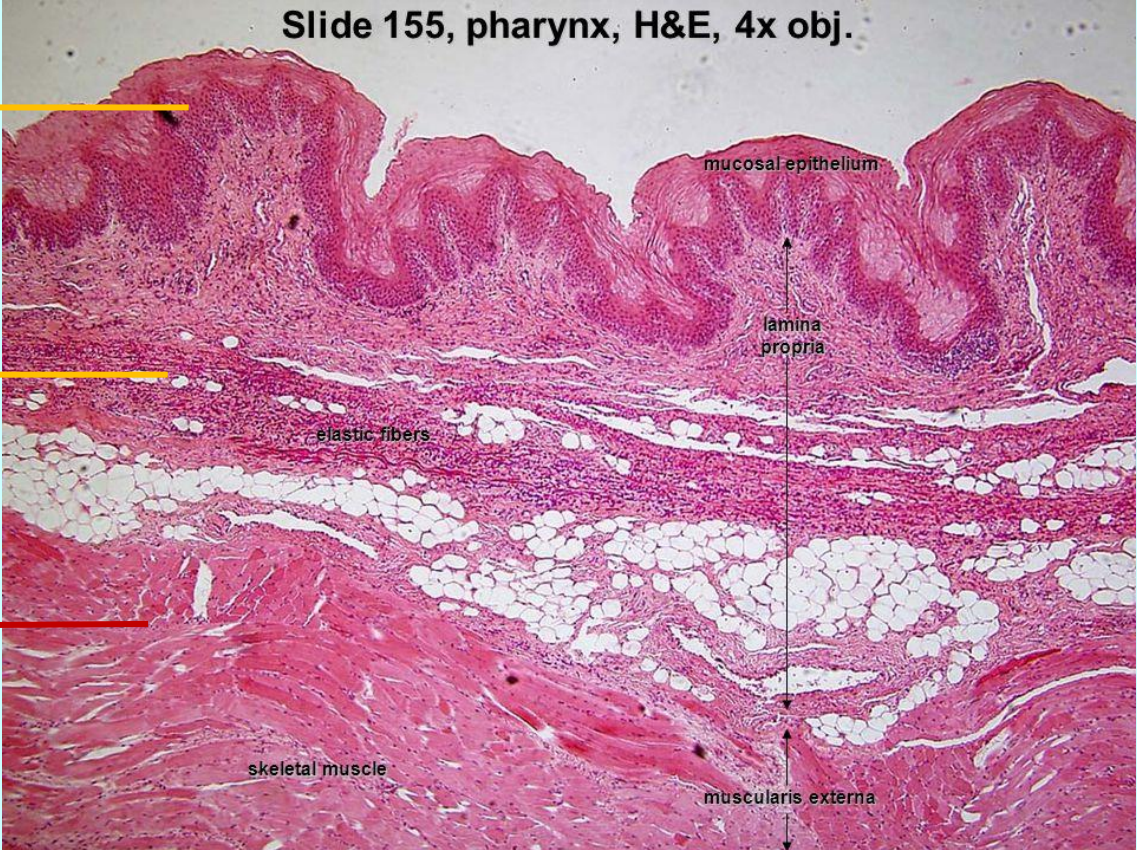
tunica mucosa

lamina epithelialis

lamina propria

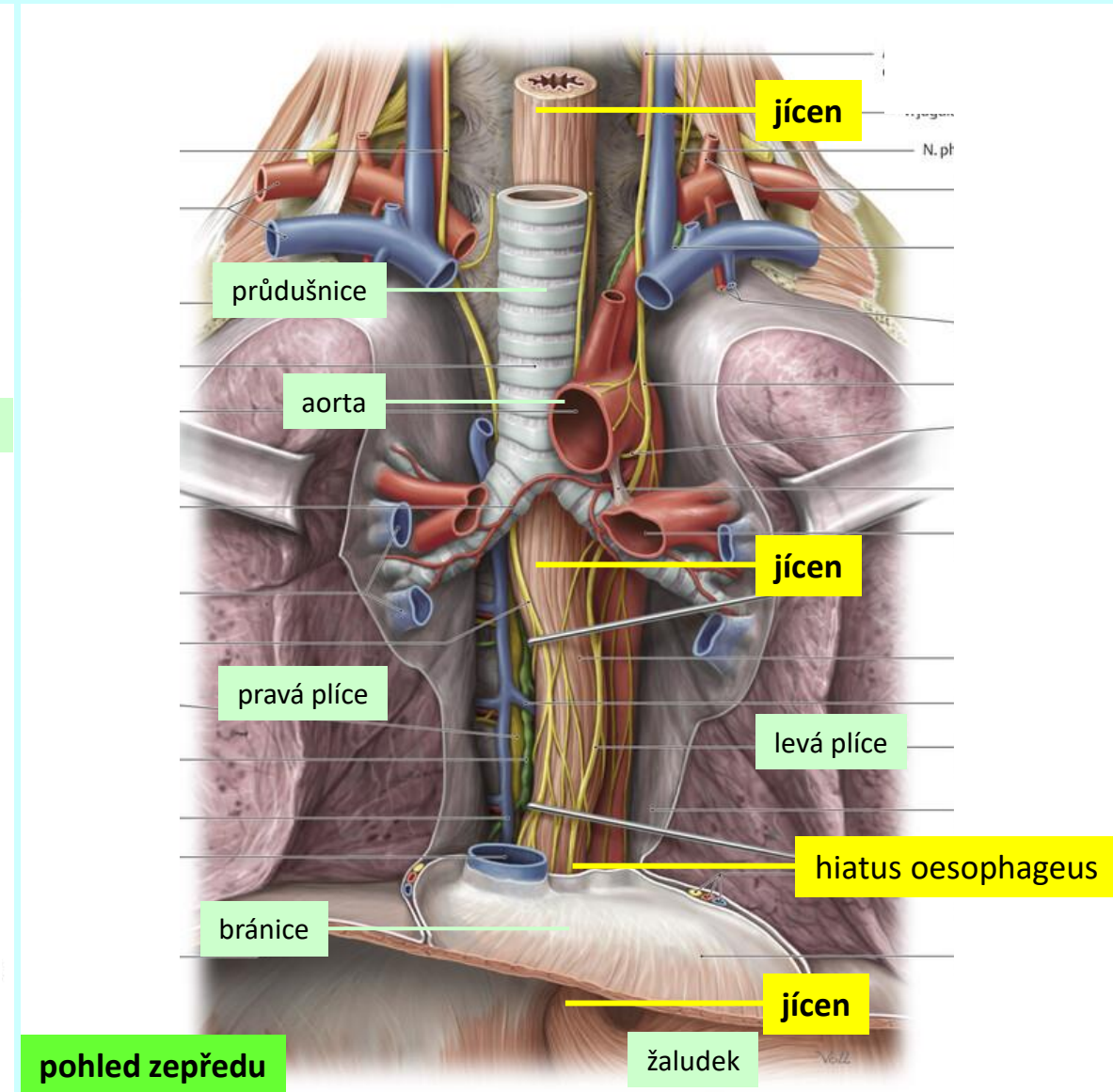
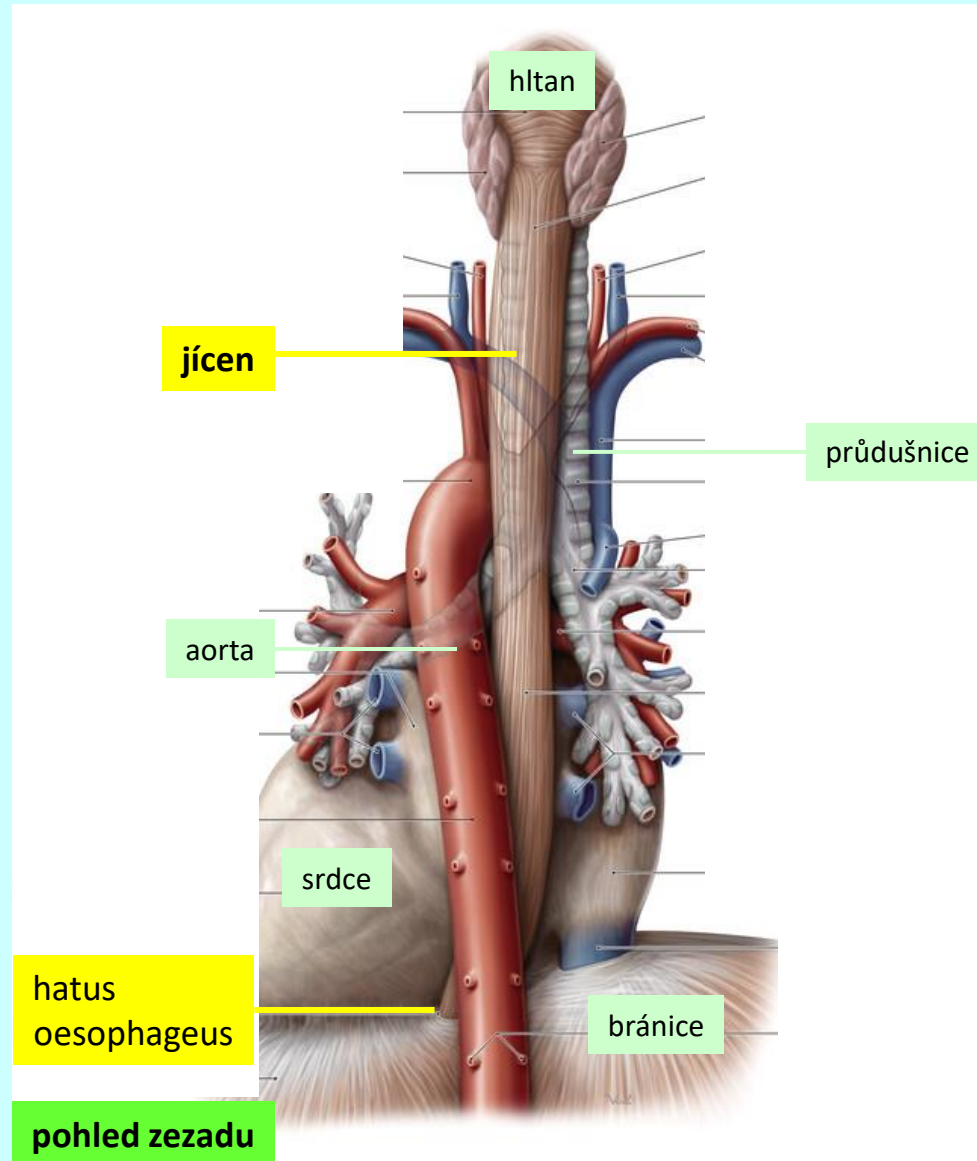
tunica muscularis

tunica adventitia



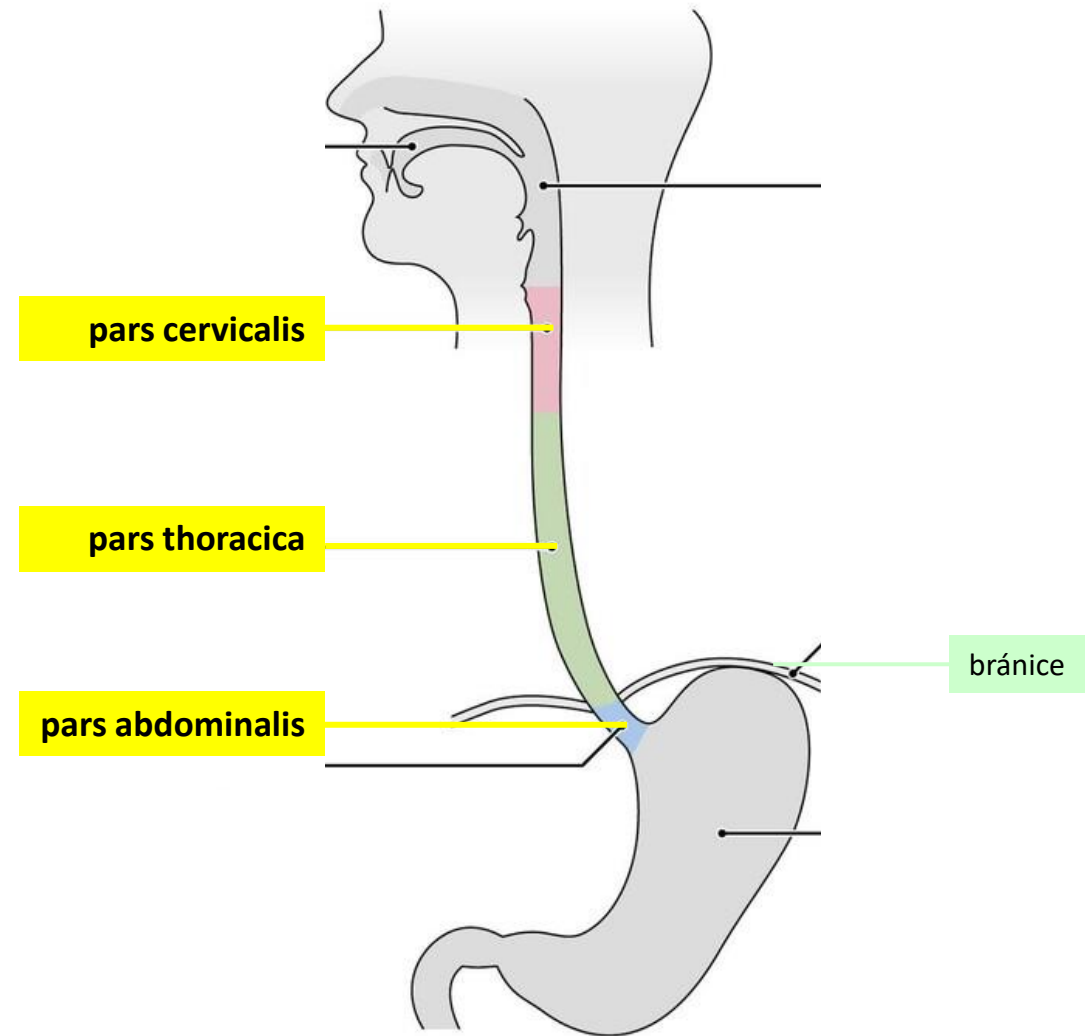
jícen (*oesophagus*)

topografie



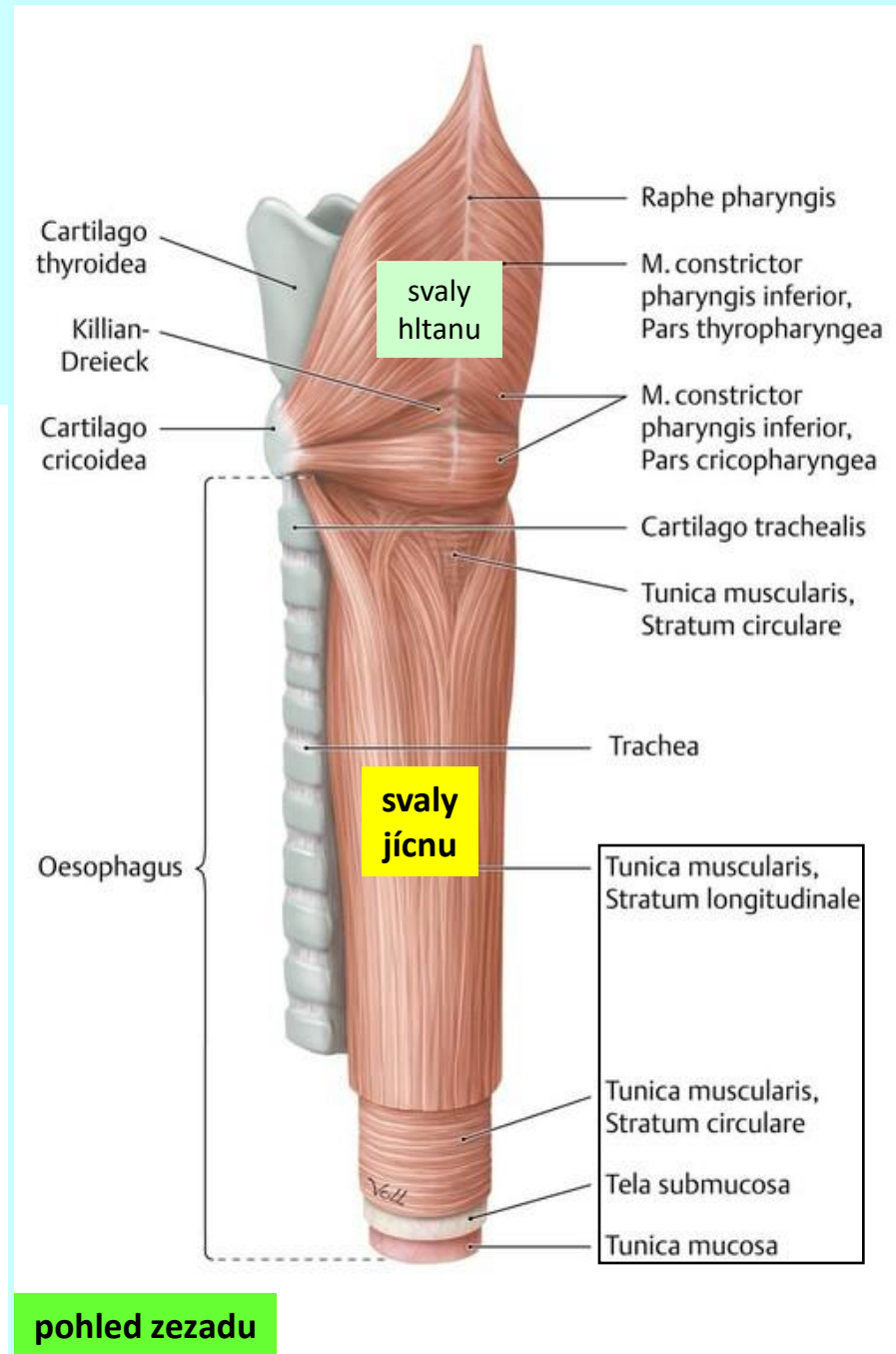
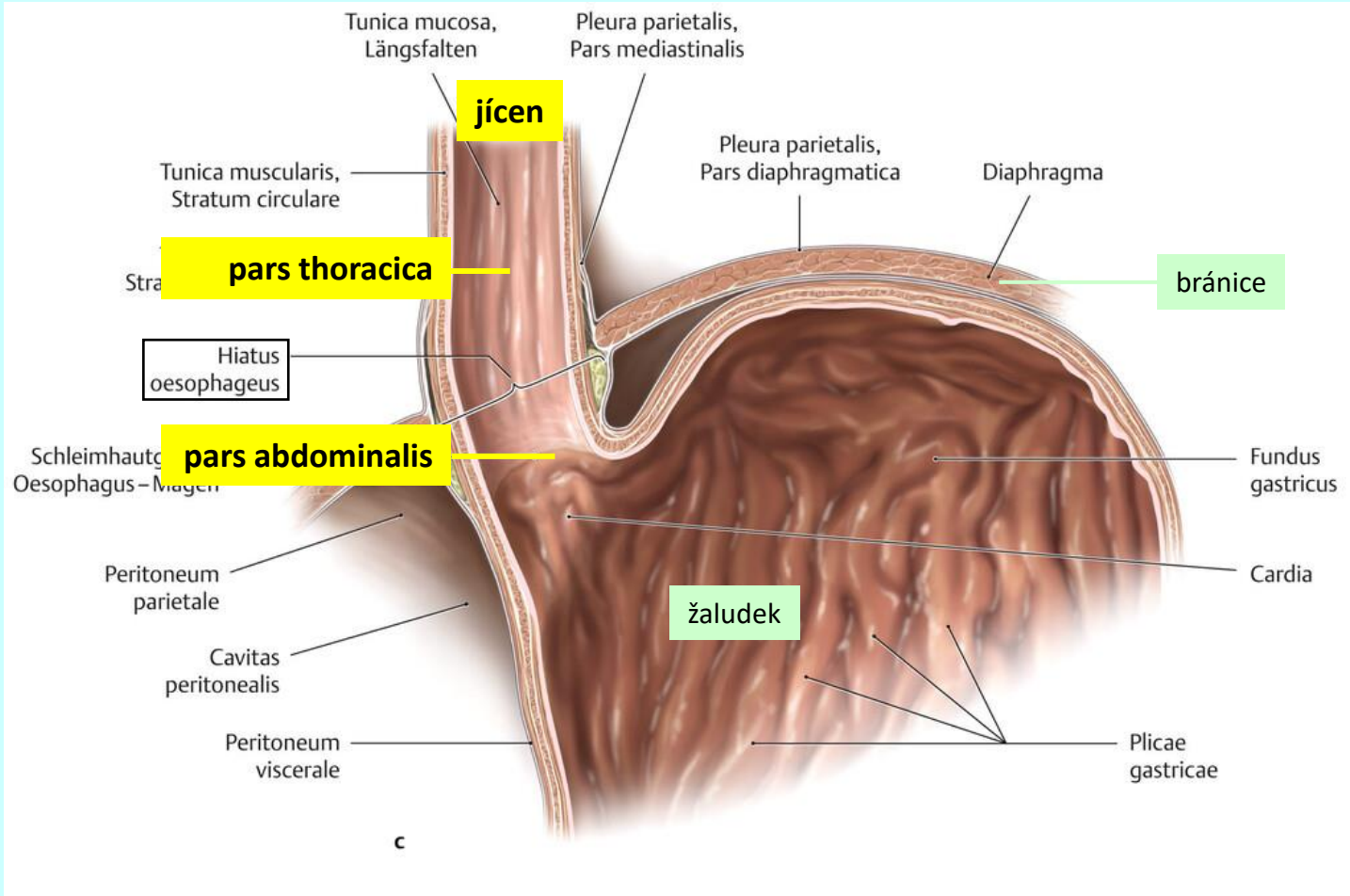
jícen (*oesophagus*)

makroskopická stavba



jícen (oesophagus)

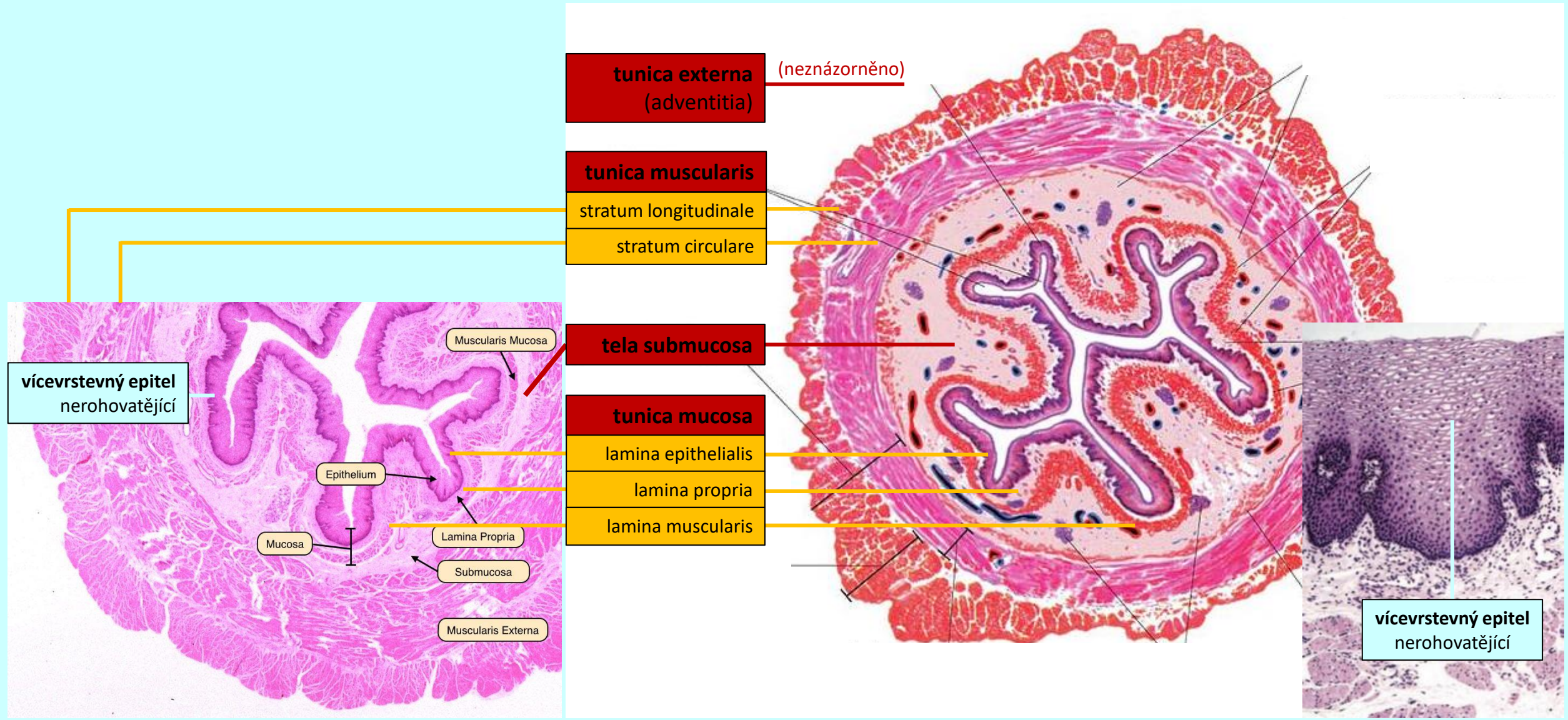
makroskopická stavba



pohled zezadu

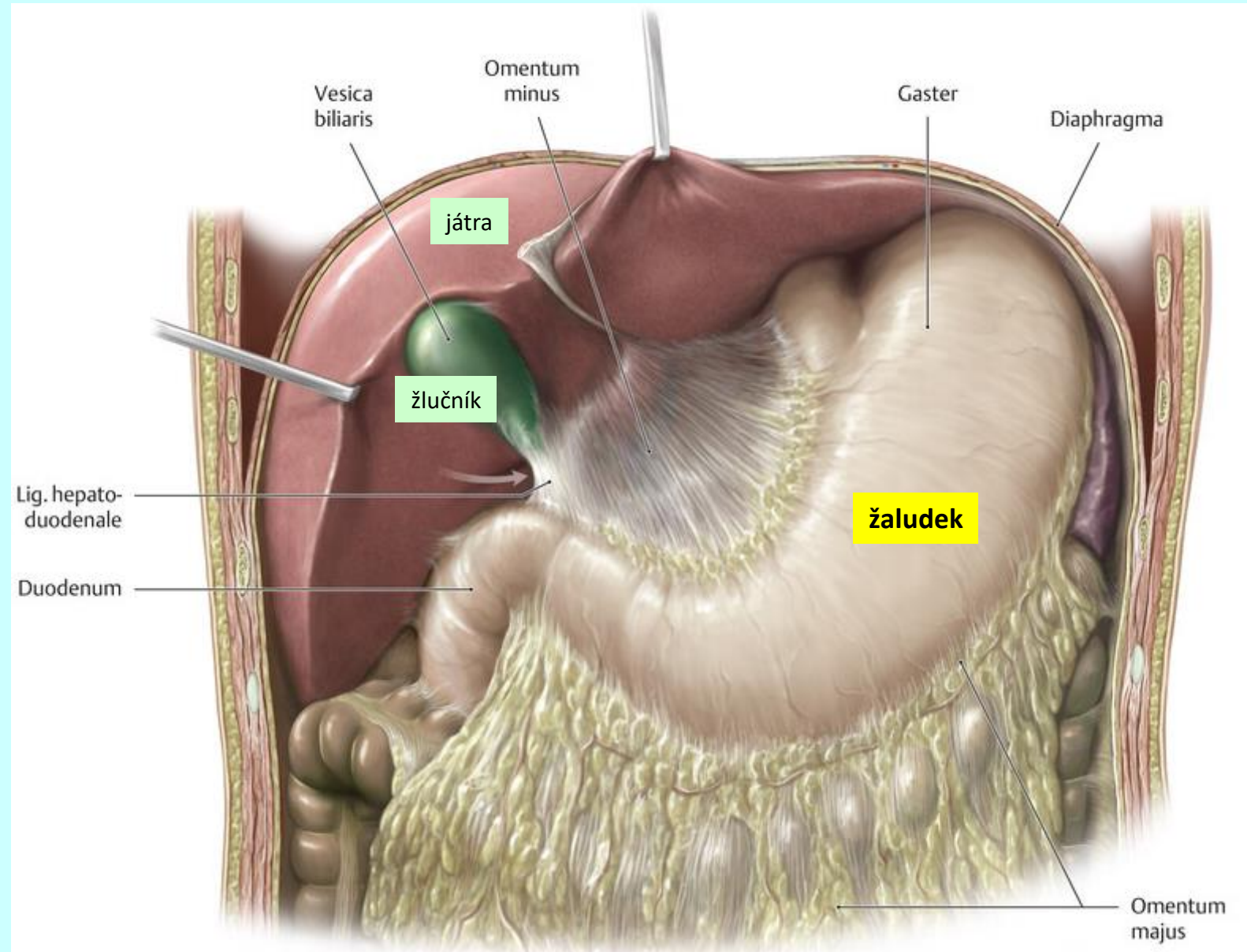
jícen (oesophagus)

histologická stavba



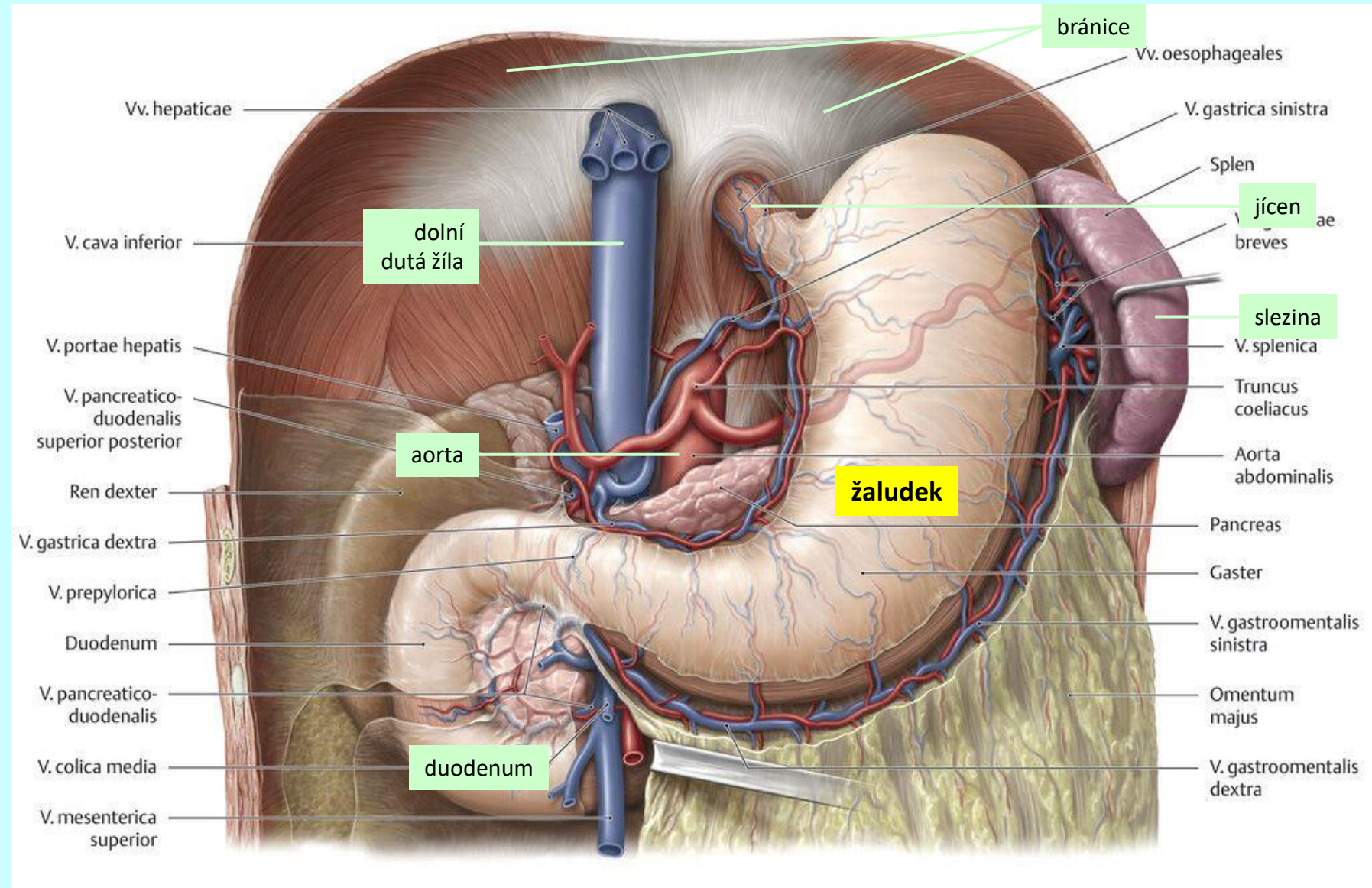
žaludek (*gaster*)

topografie



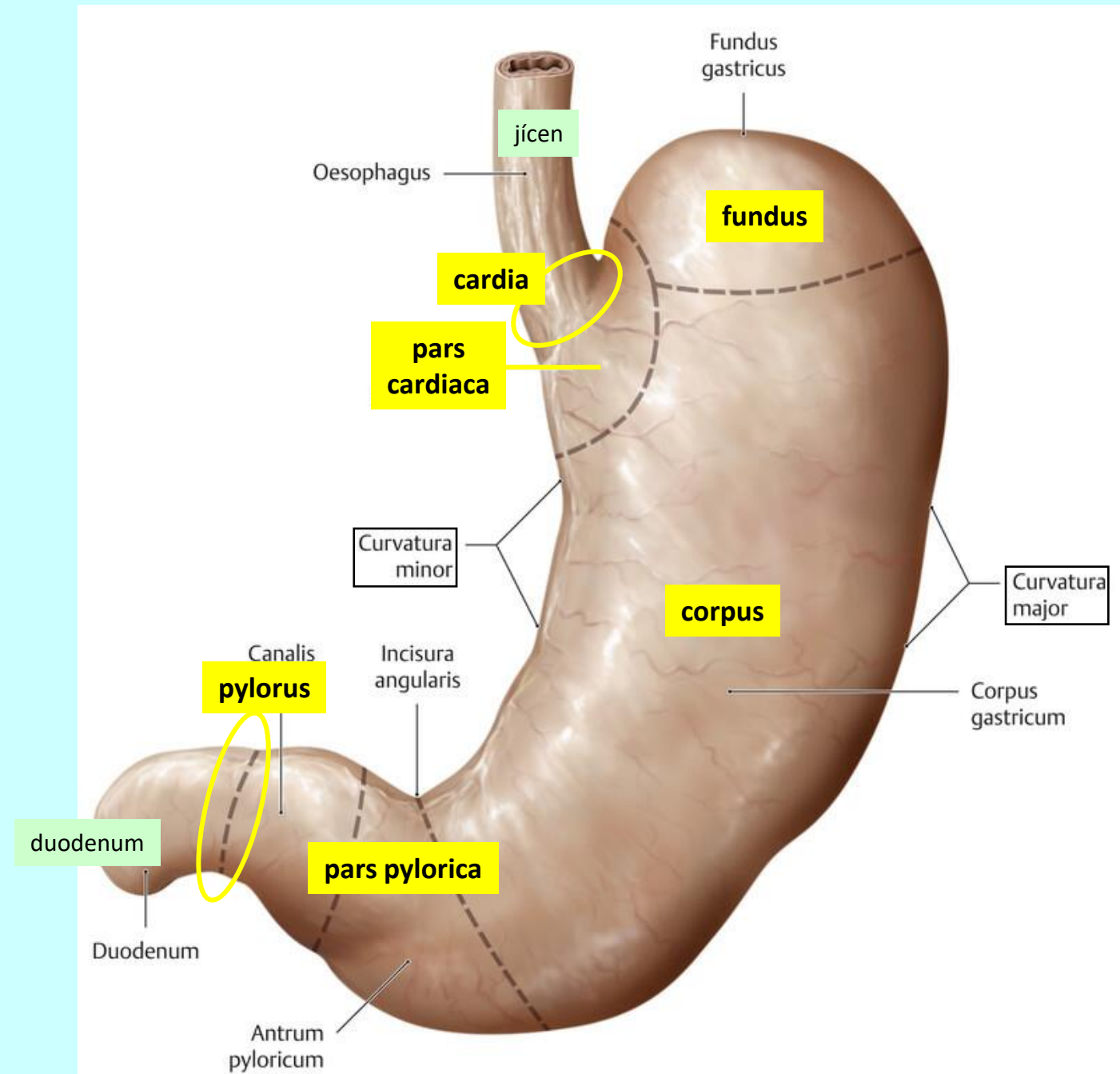
žaludek (*gaster*)

topografie



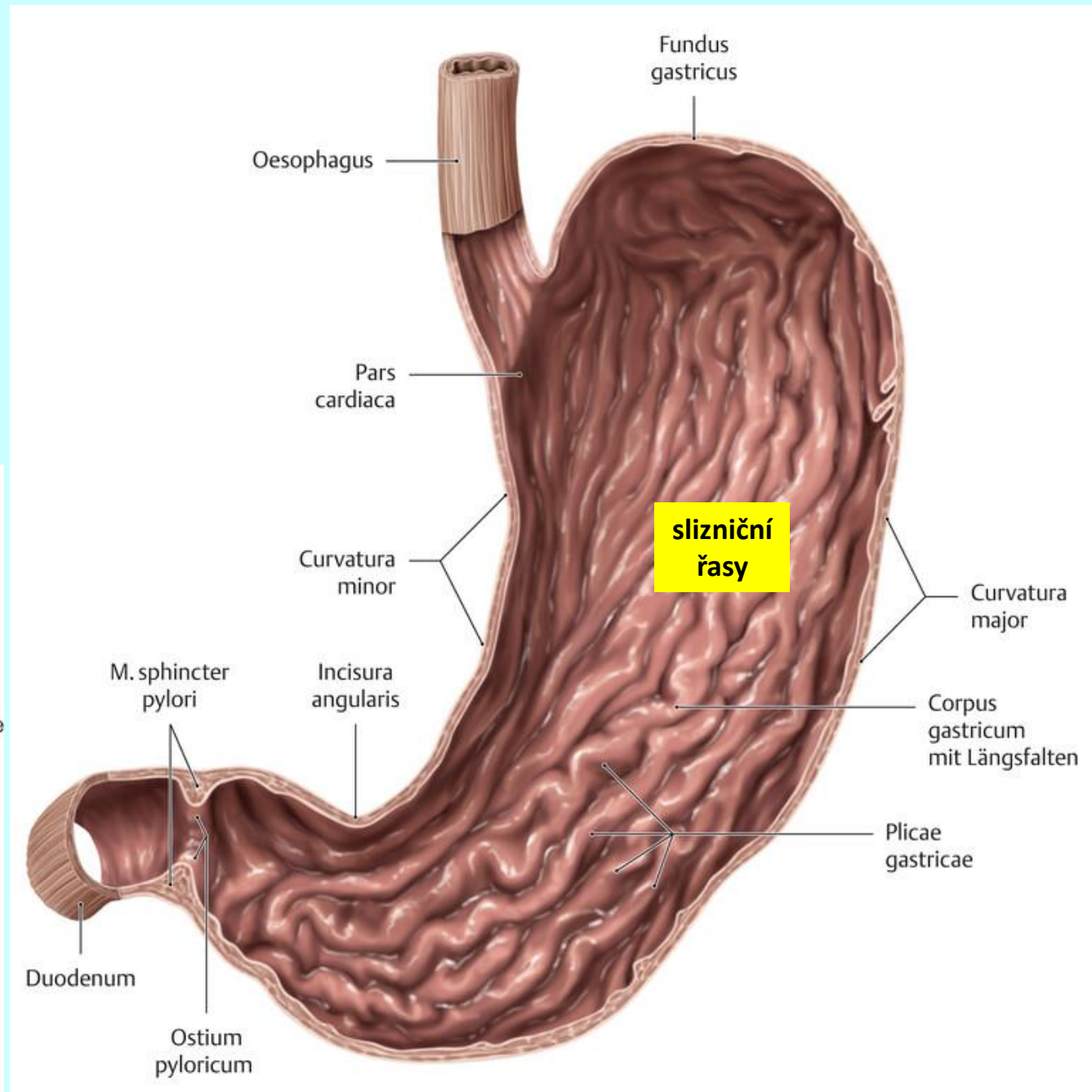
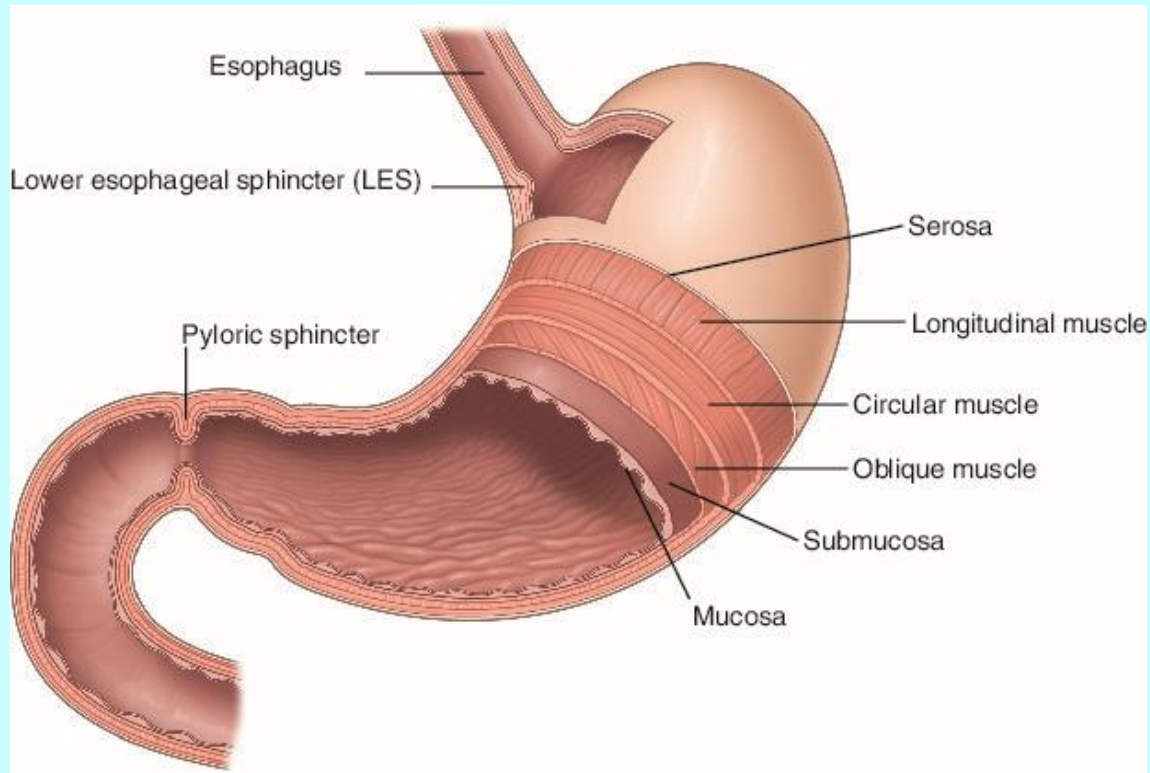
žaludek (*gaster*)

makroskopická stavba



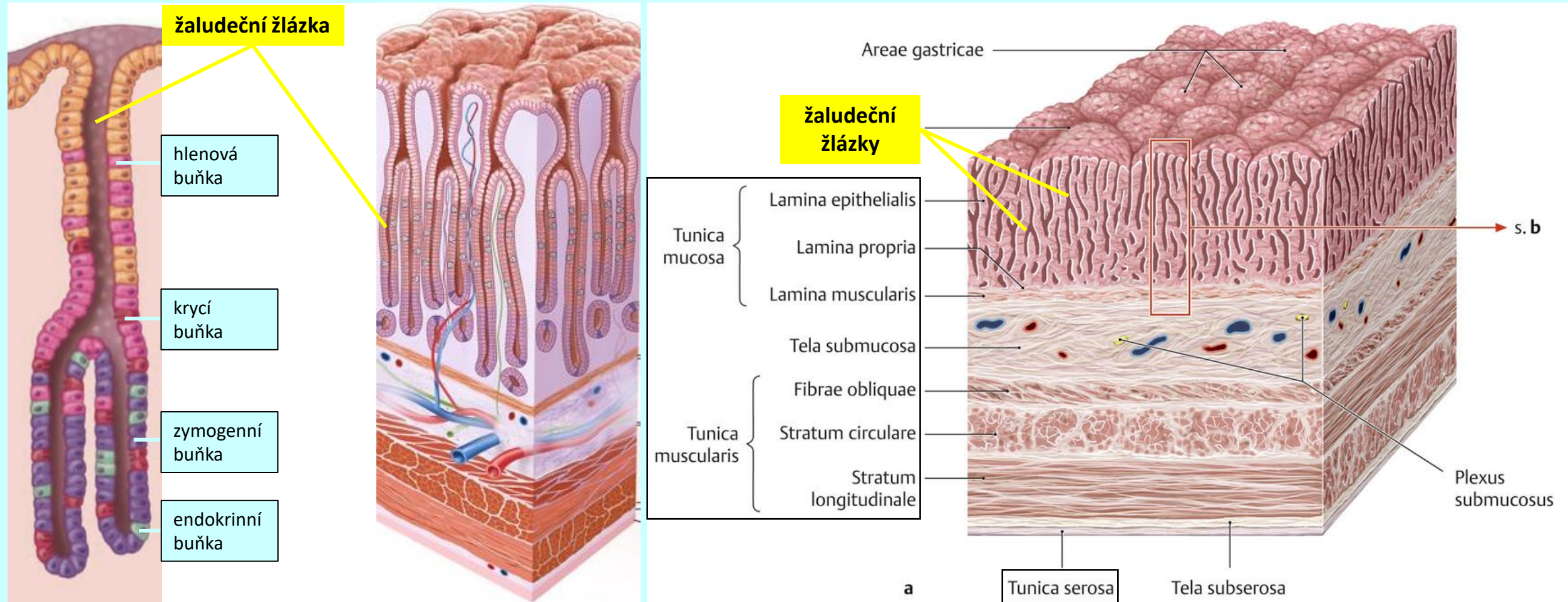
žaludek (*gaster*)

histologická stavba



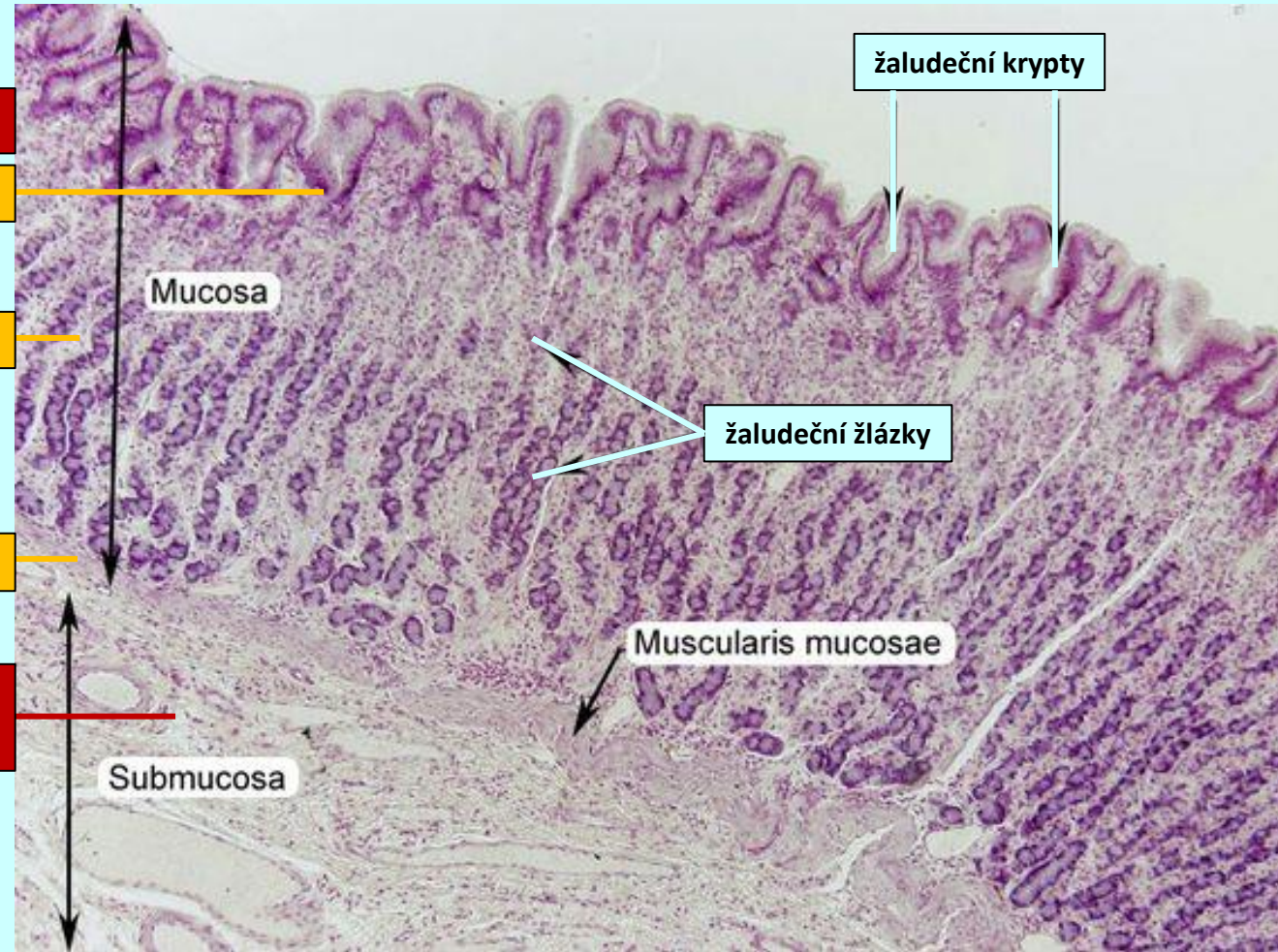
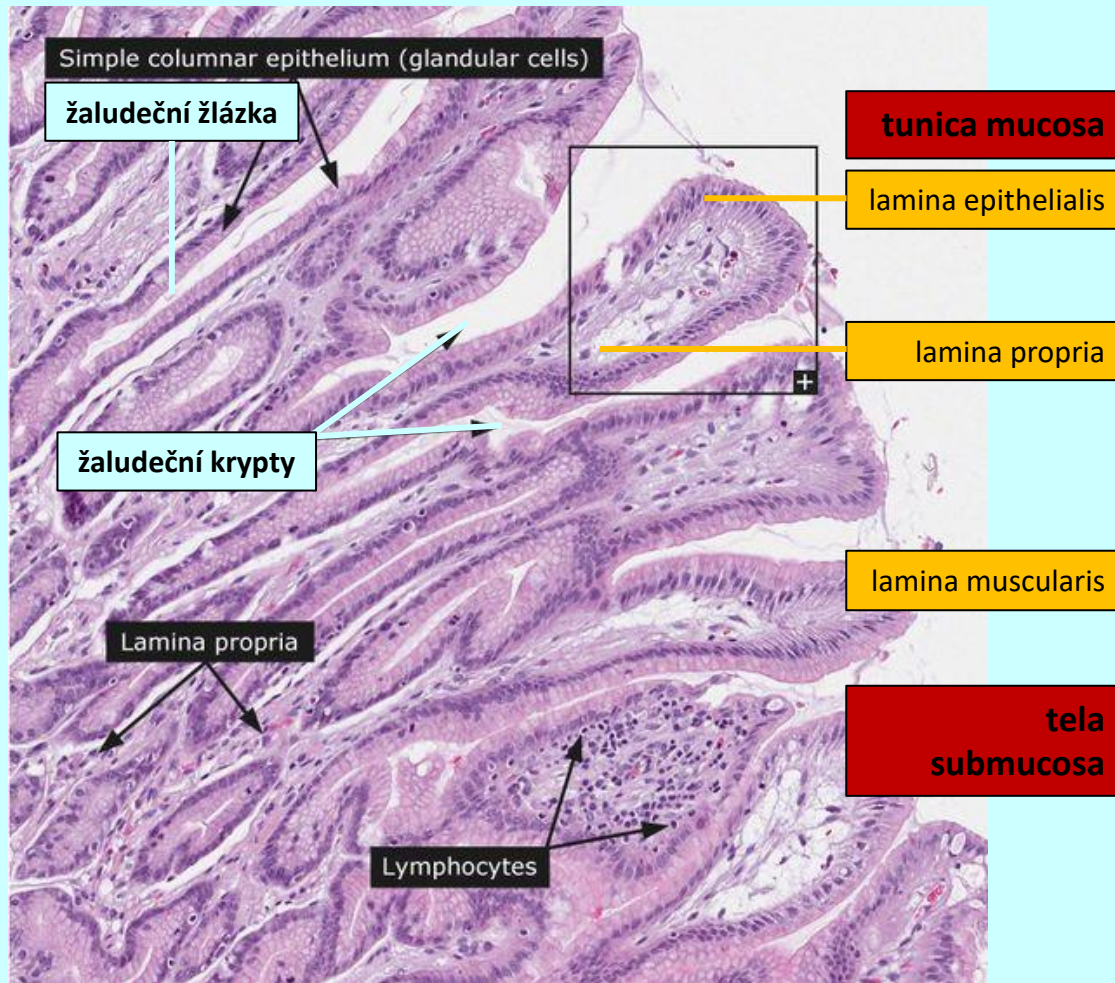
žaludek (*gaster*)

histologická stavba



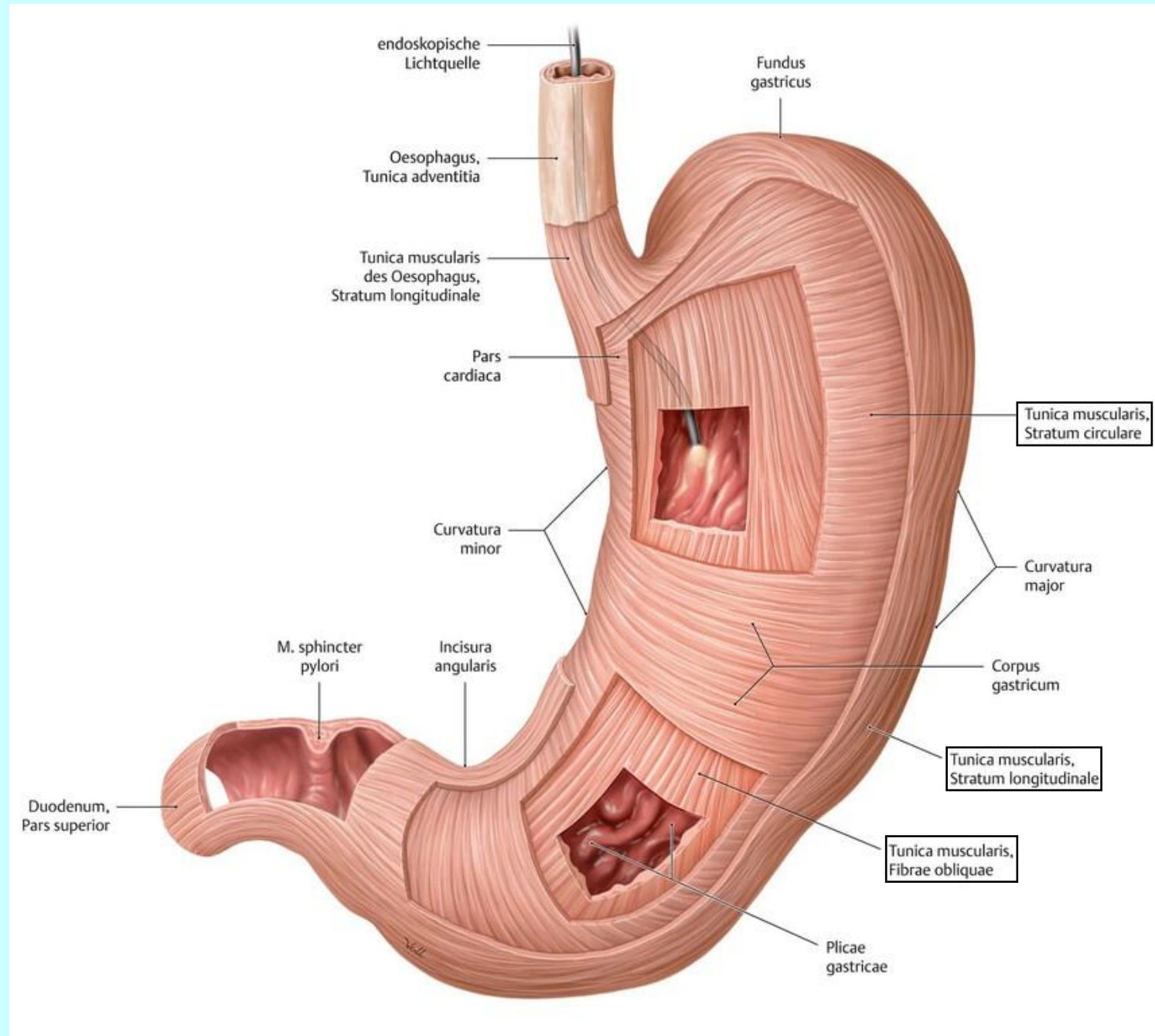
žaludek (*gaster*)

histologická stavba



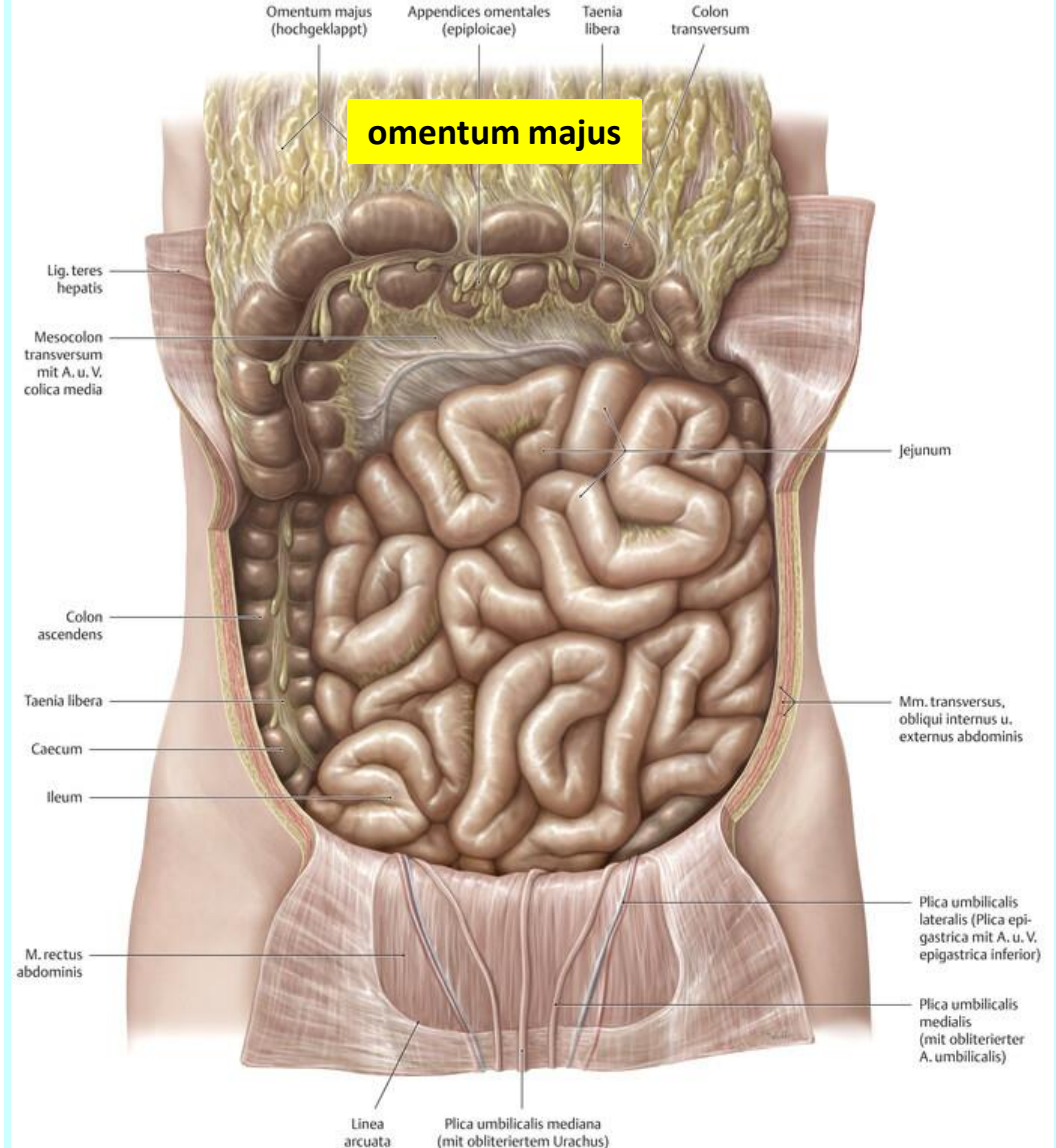
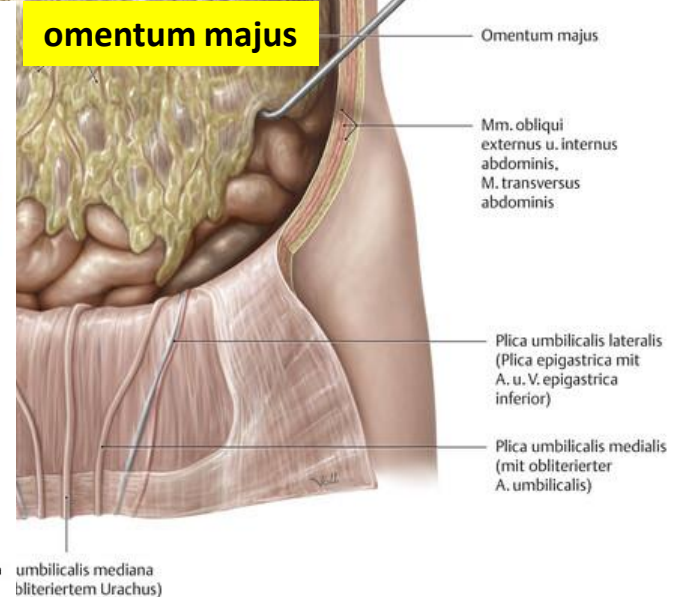
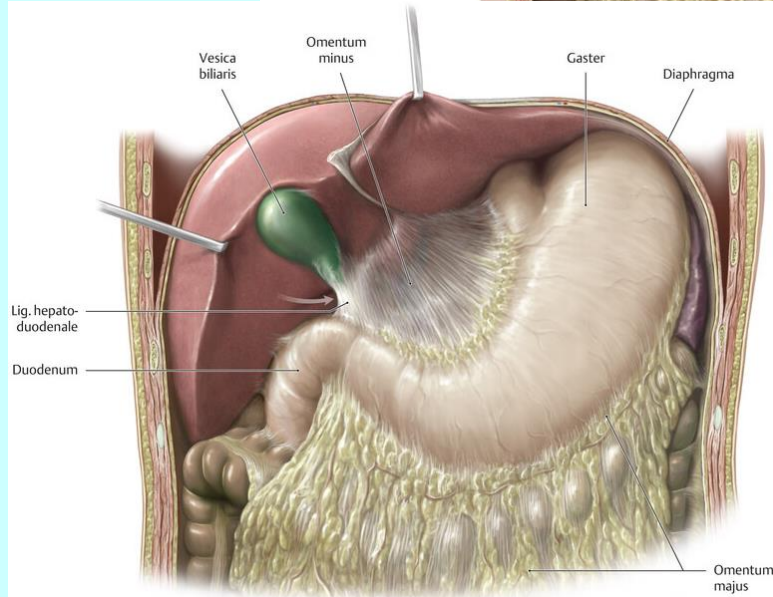
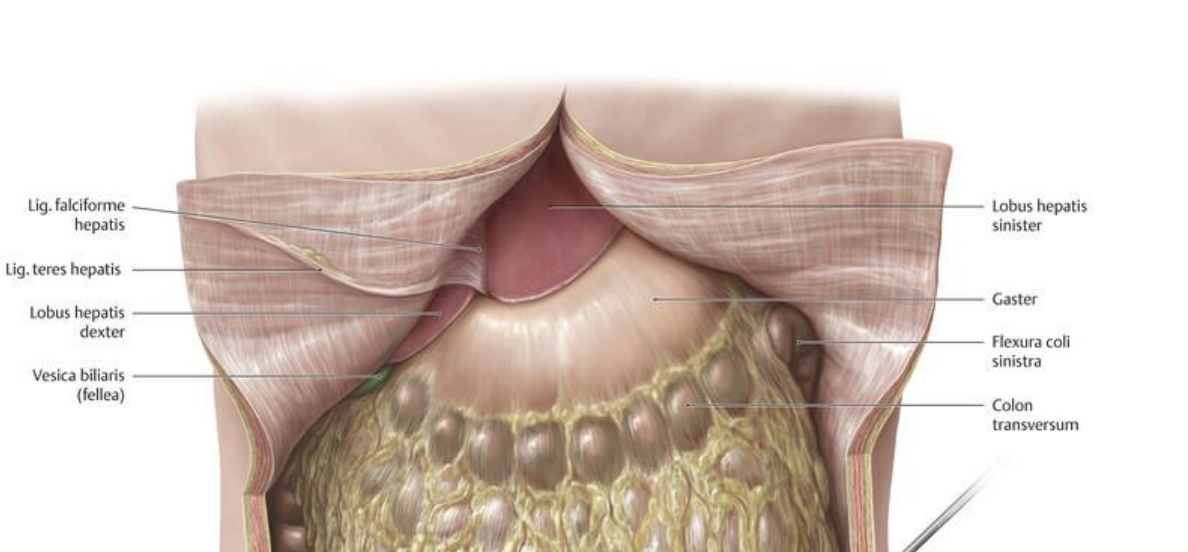
žaludek (*gaster*)

histologická stavba



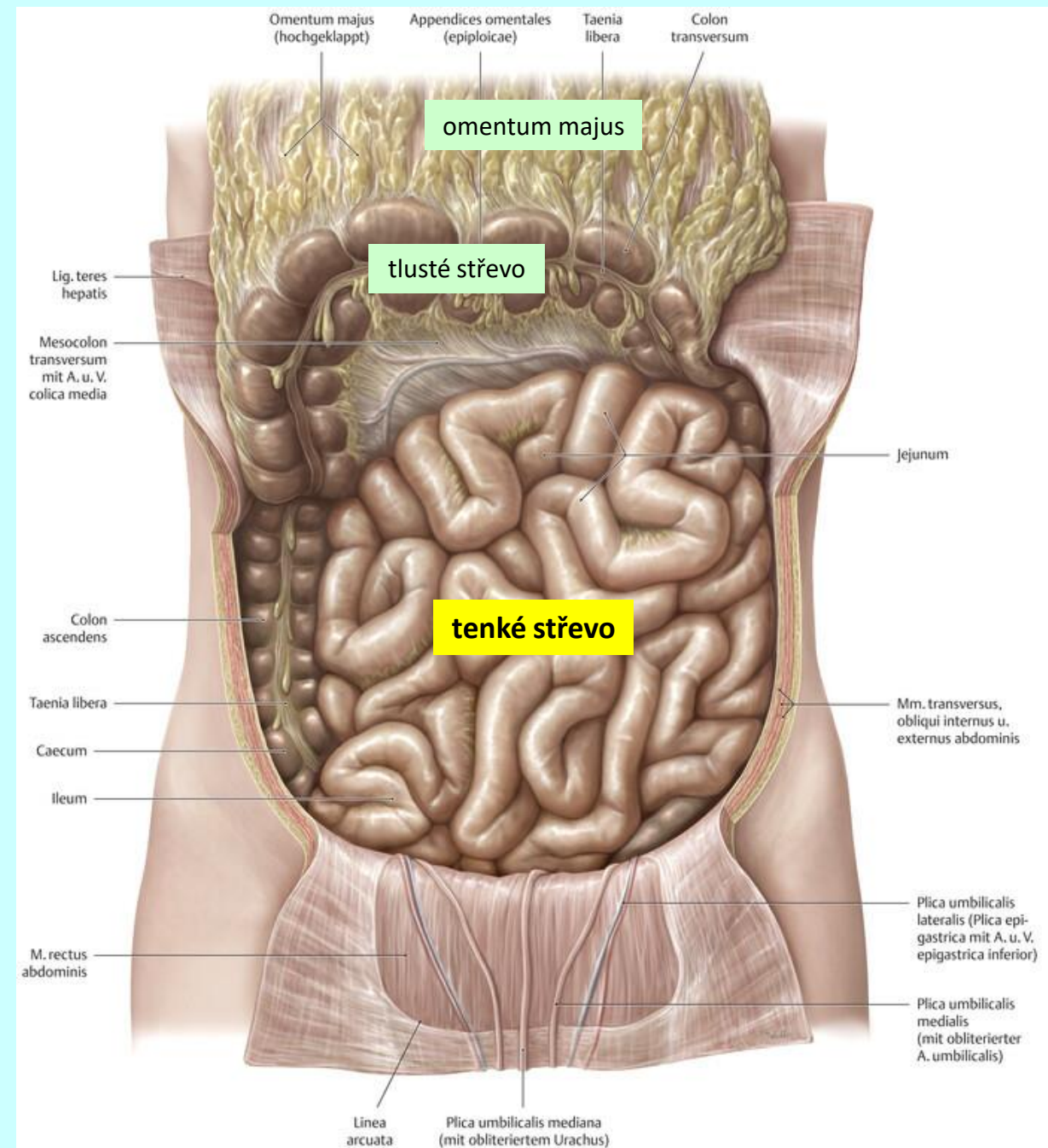
žaludek (*gaster*)

histologická stavba



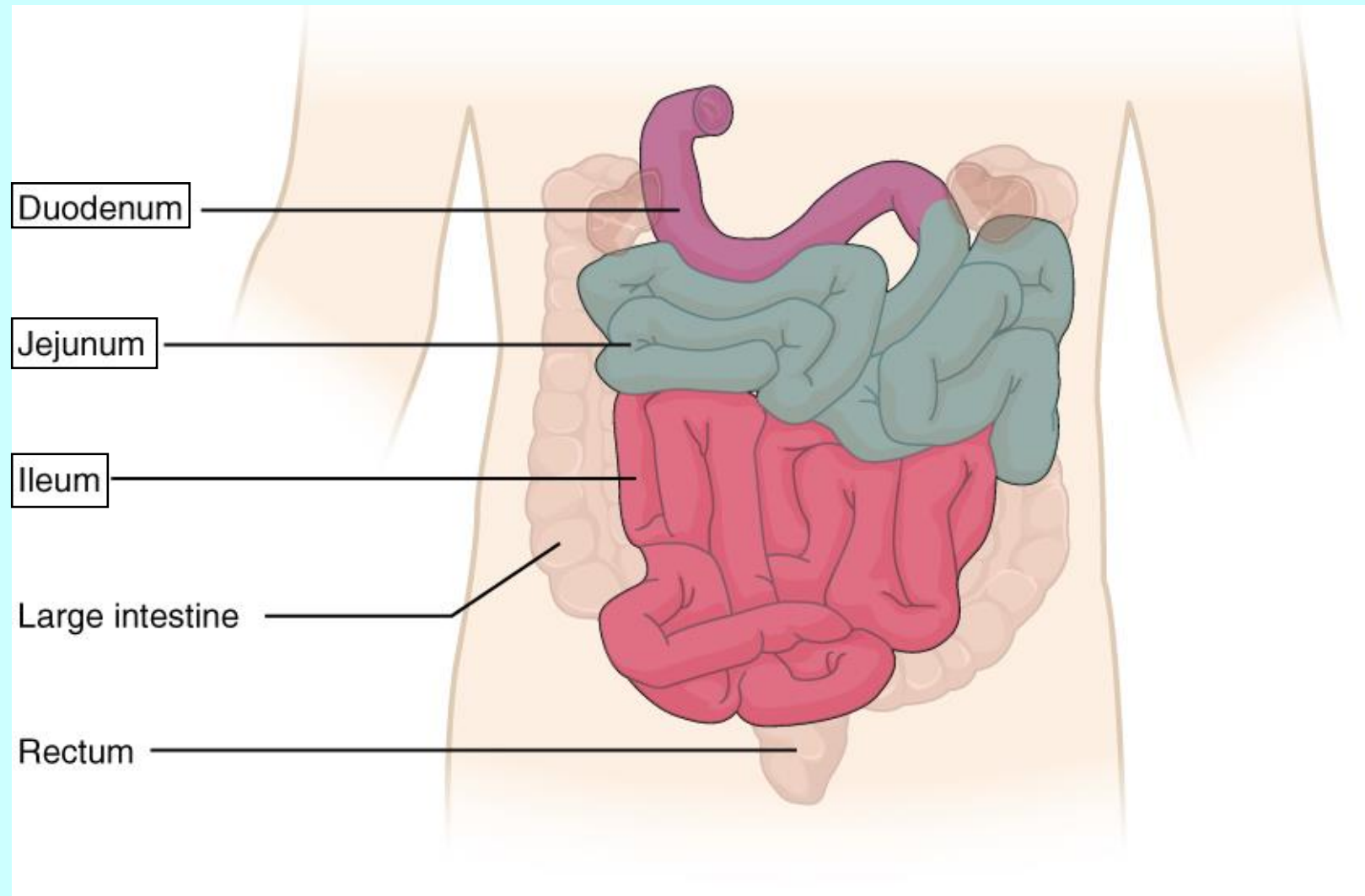
tenké střevo (*intestinum tenue*)

topografie



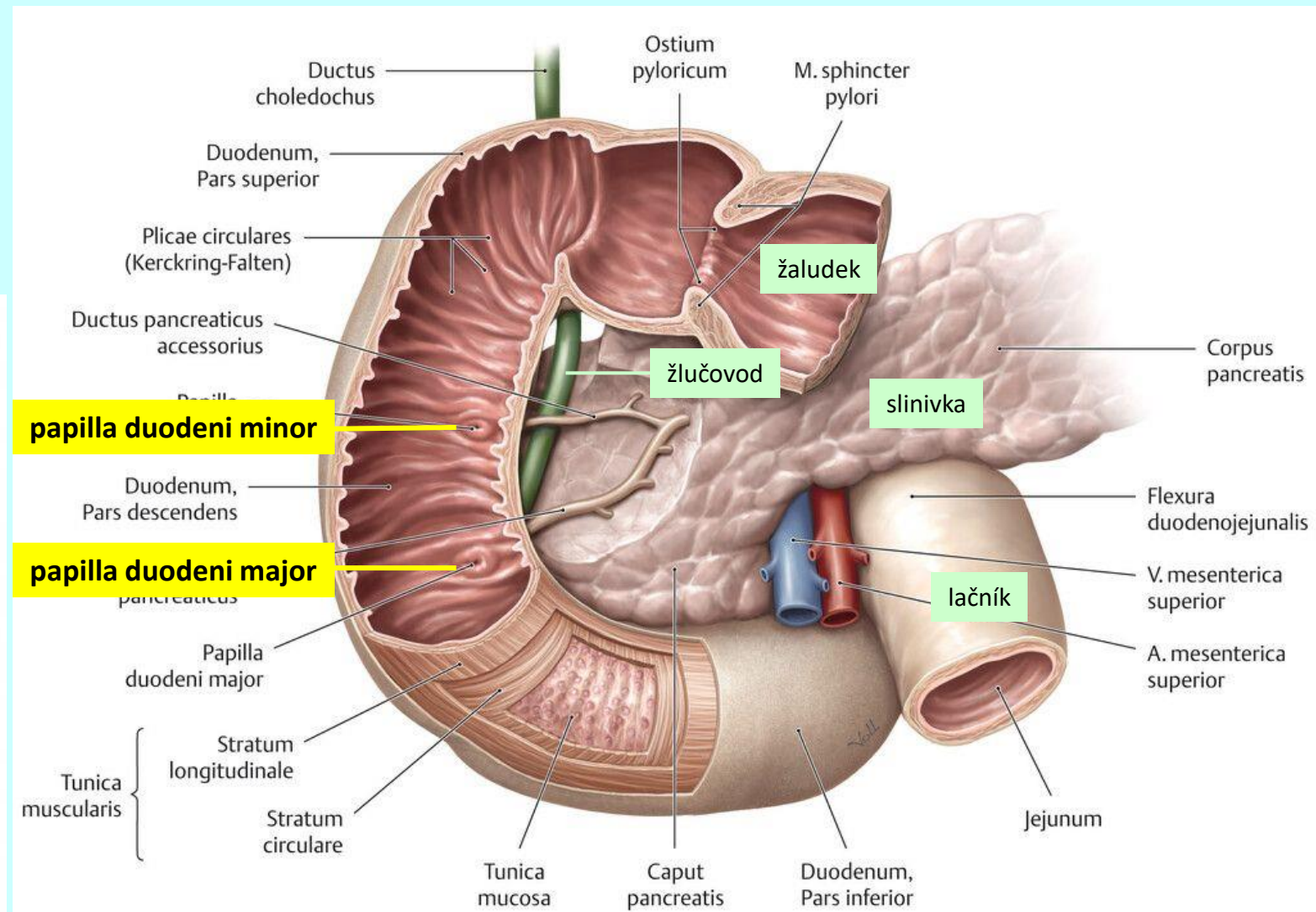
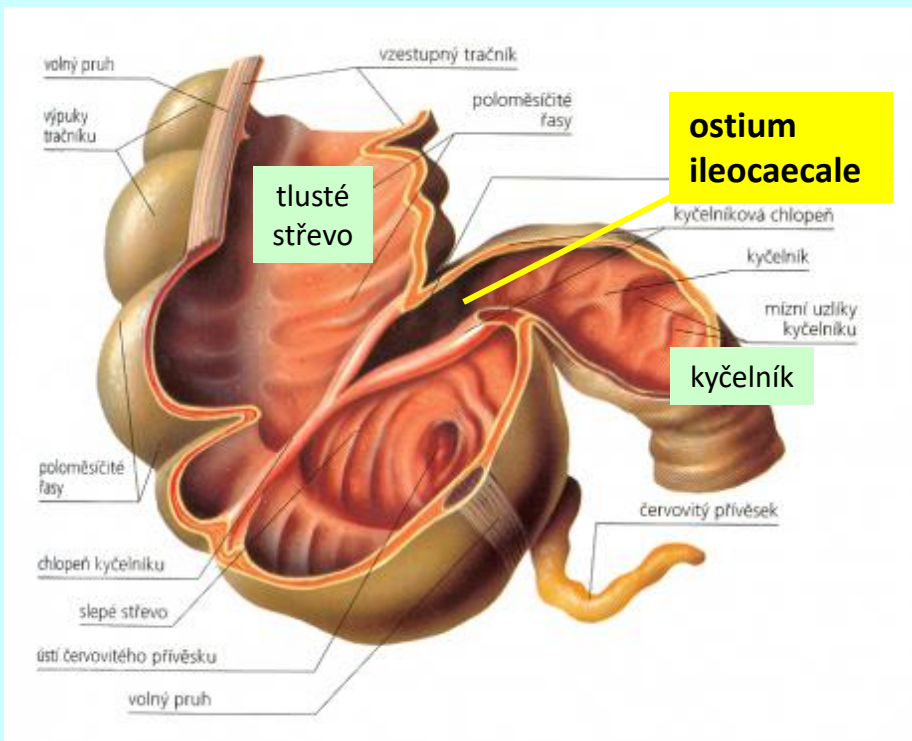
tenké střevo (*intestinum tenue*)

makroskopická stavba



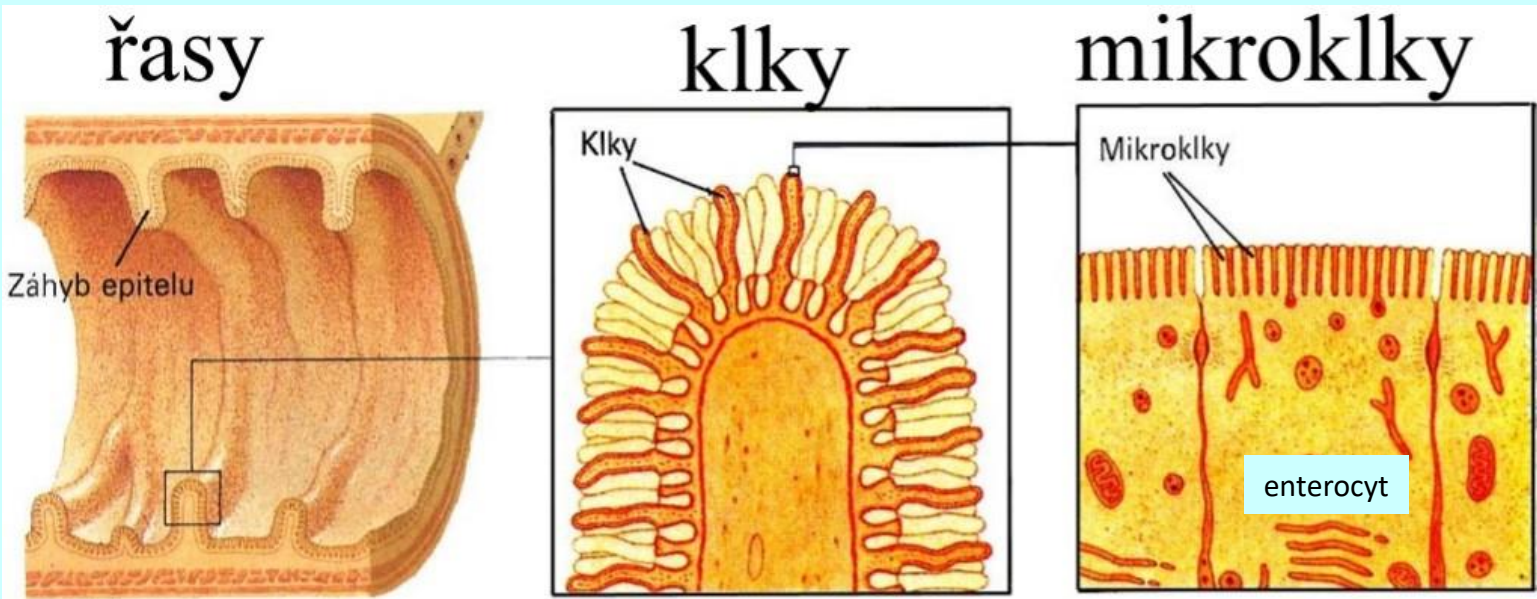
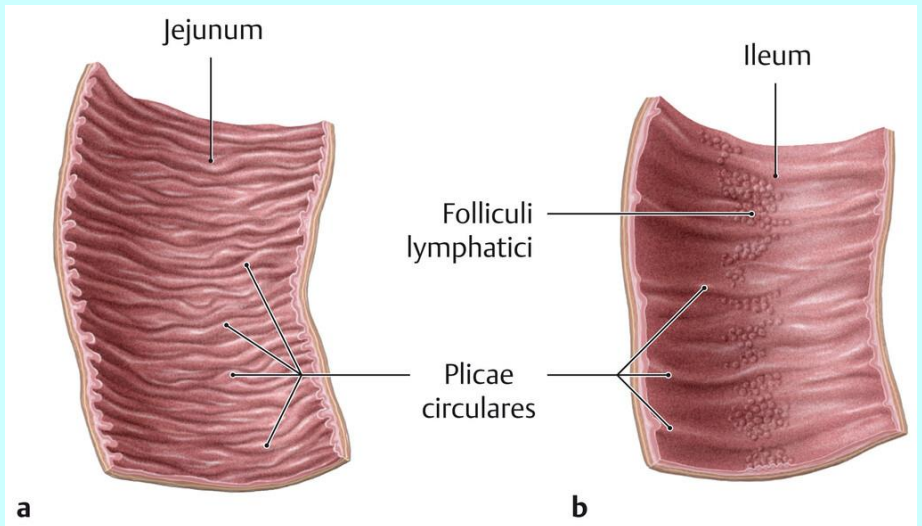
tenké střevo (*intestinum tenue*)

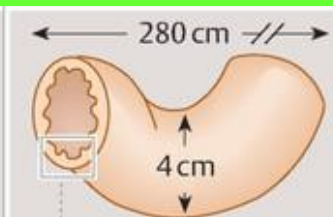
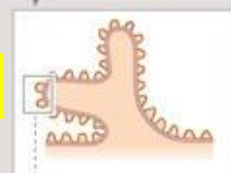
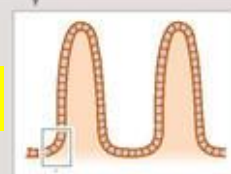
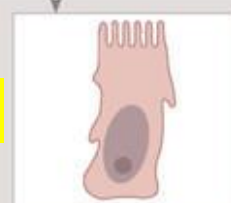
makroskopická stavba



tenké střevo (*intestinum tenue*)

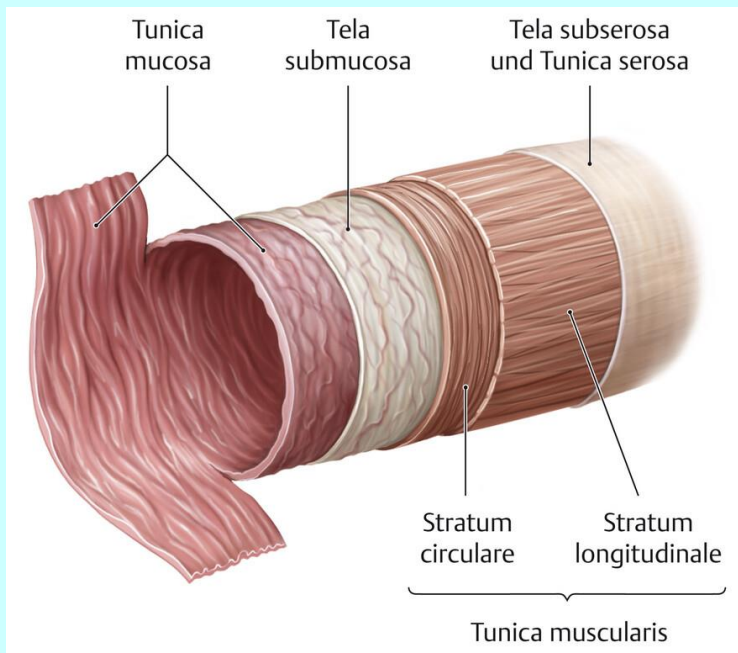
histologická stavba



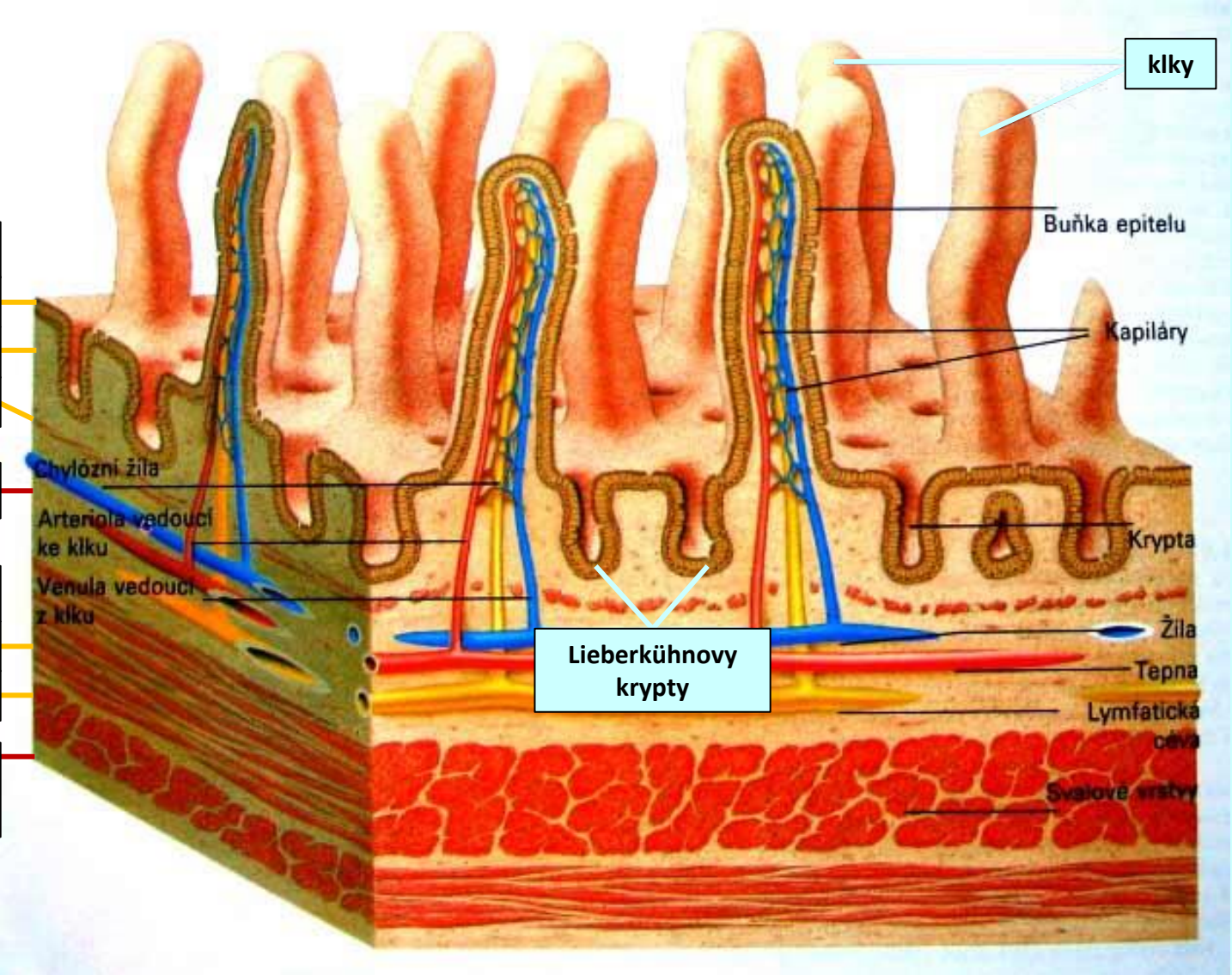
mechanizmy zvětšení resorpční plochy	násobek zvětšení	plocha v m ²
Darm als Zylinder 	1	0,33
řasy 	3	1
klky 	30	10
mikroklky 	600	200

tenké střevo (*intestinum tenue*)

histologická stavba

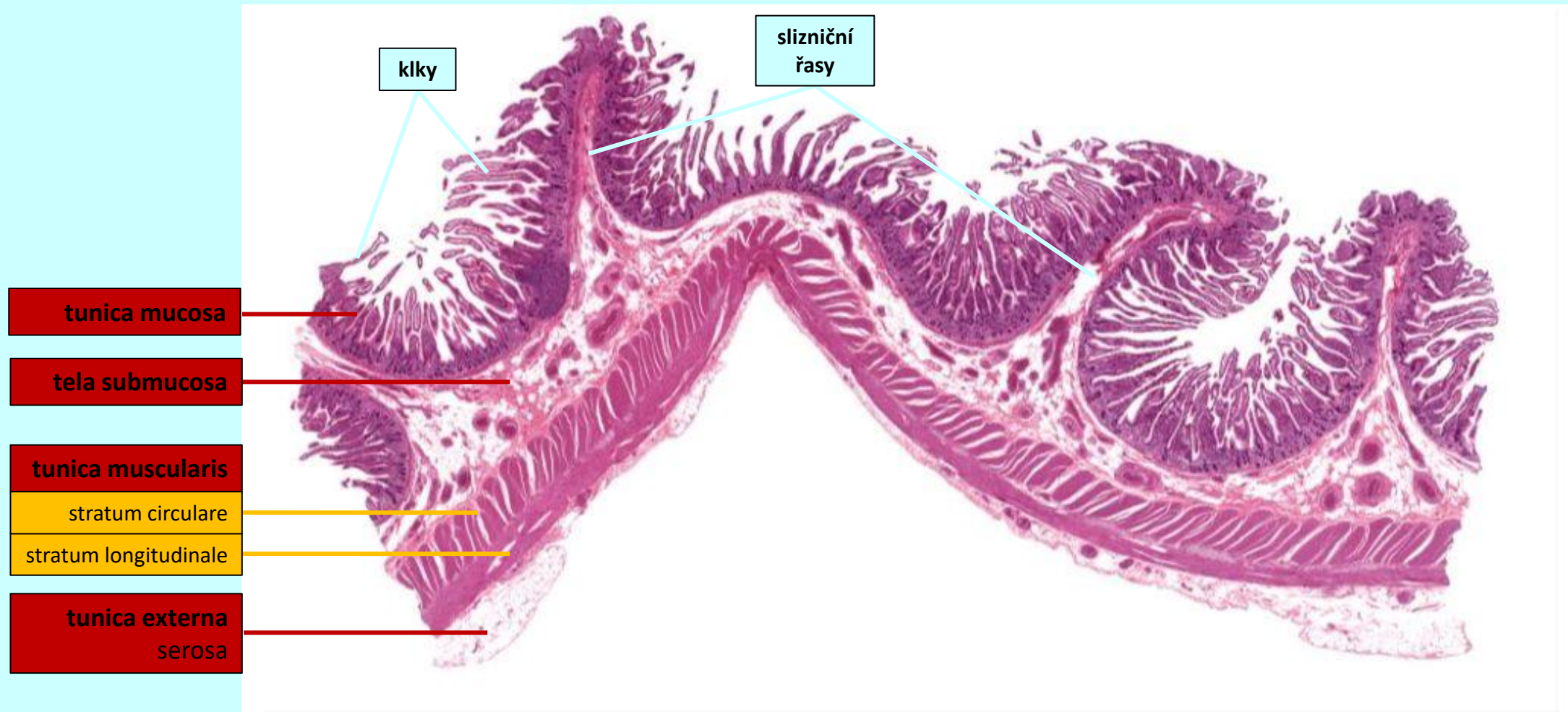


- tunica mucosa
 - lamina epithelialis
 - lamina propria
 - lamina muscularis
- tela submucosa
- tunica muscularis
 - stratum circulare
 - stratum longitudinale
- tunica externa serosa



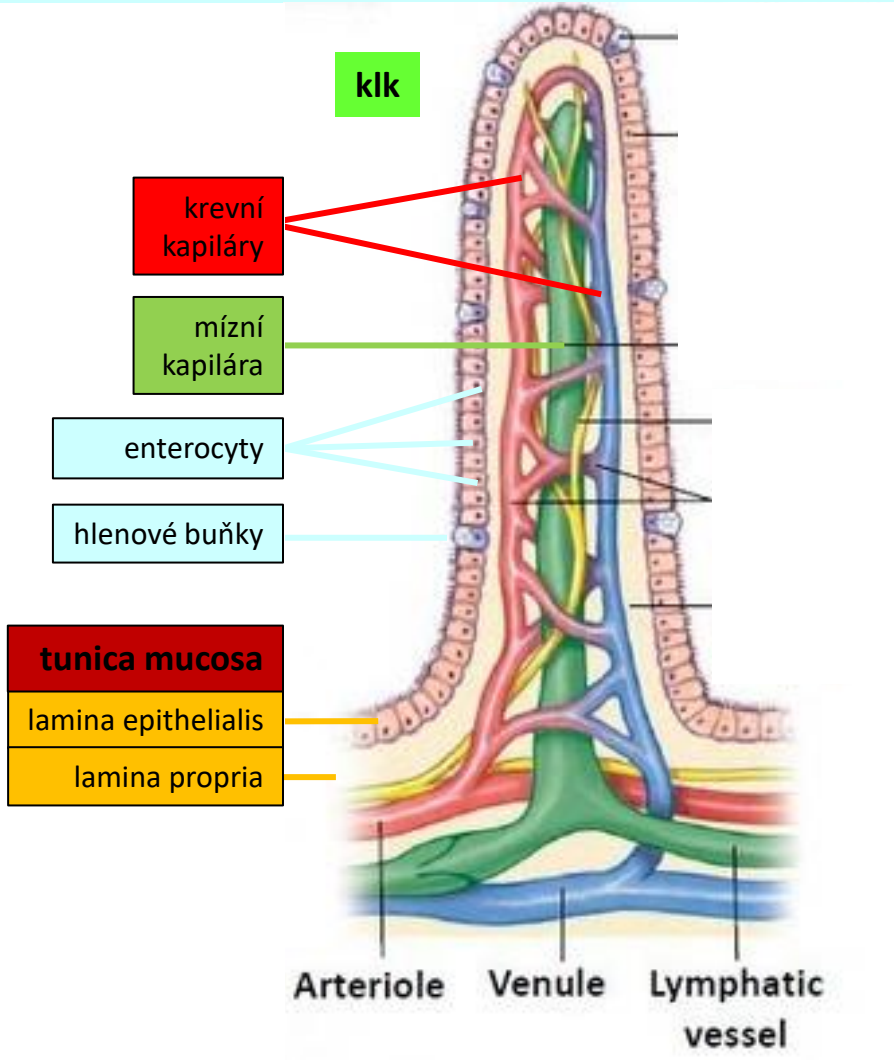
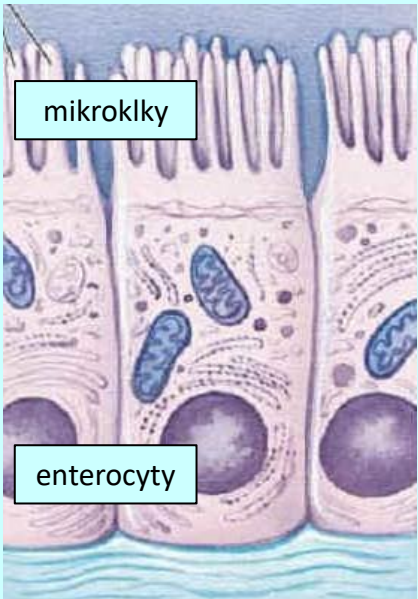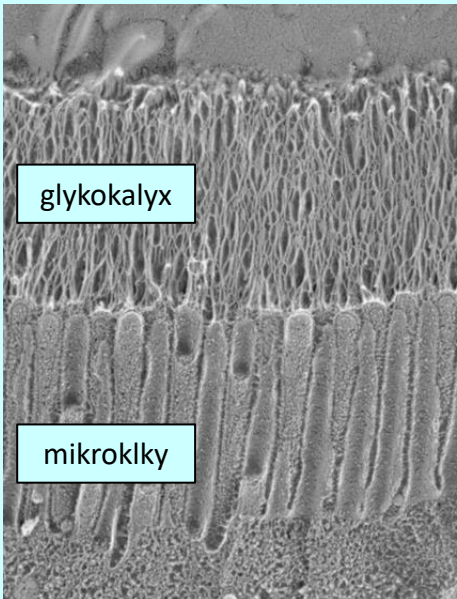
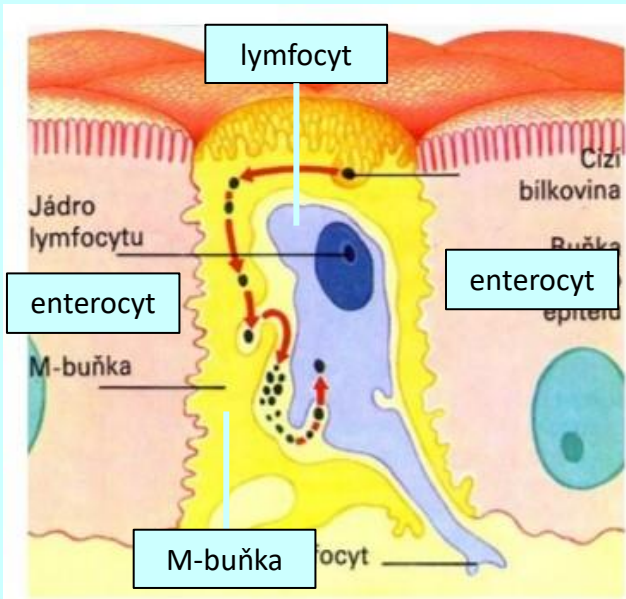
tenké střevo (*intestinum tenue*)

histologická stavba



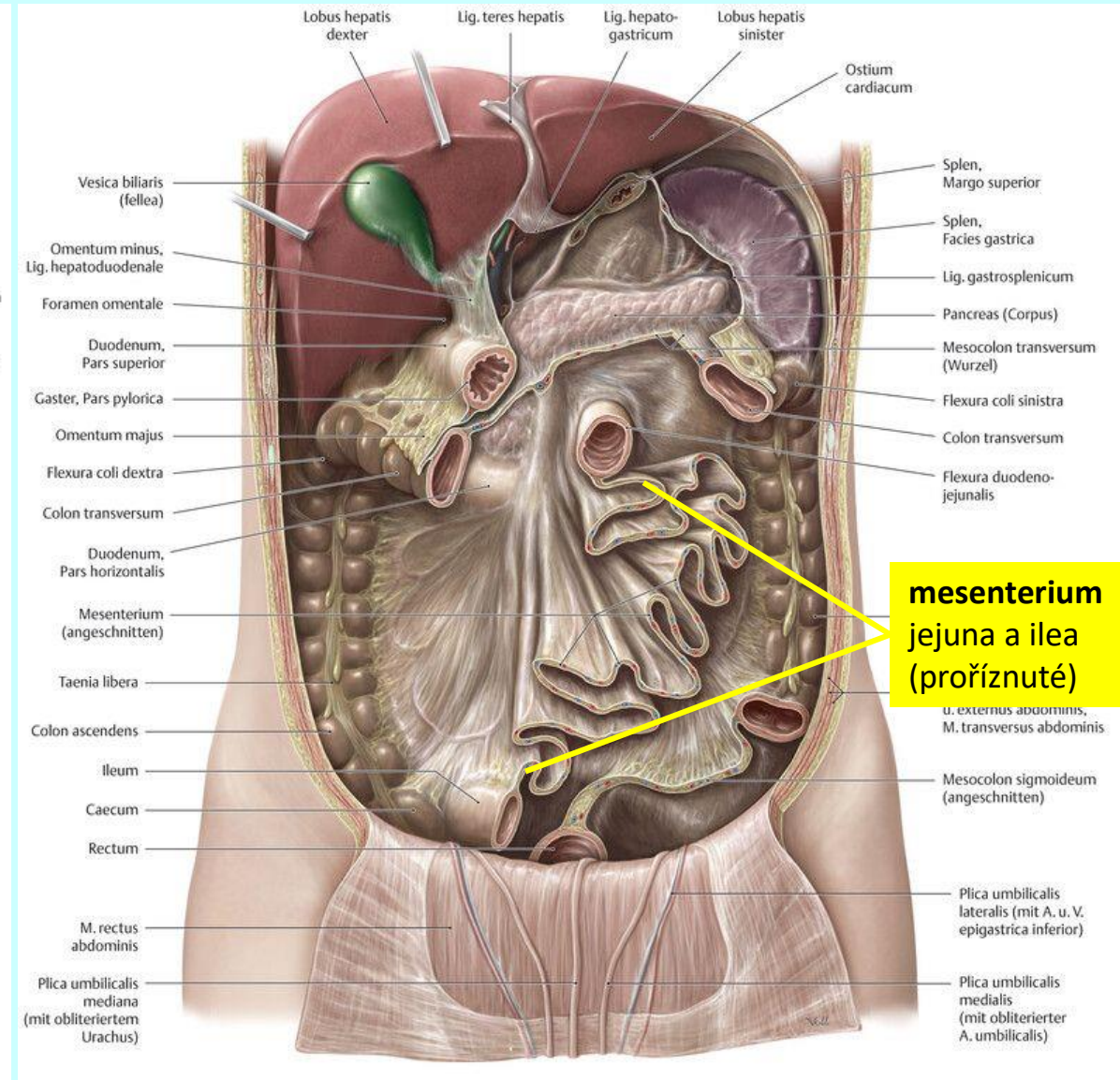
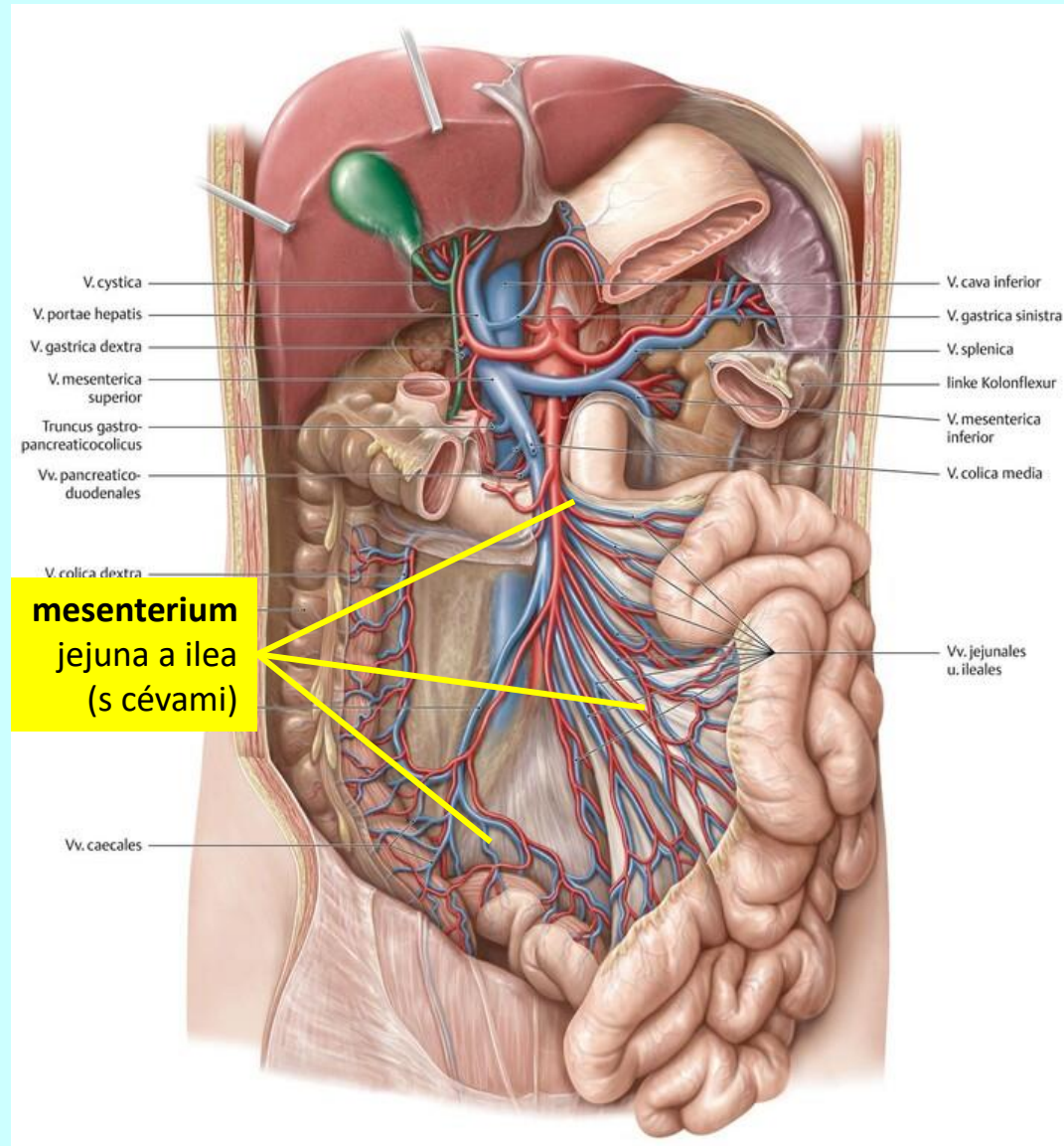
tenké střevo (*intestinum tenue*)

histologická stavba



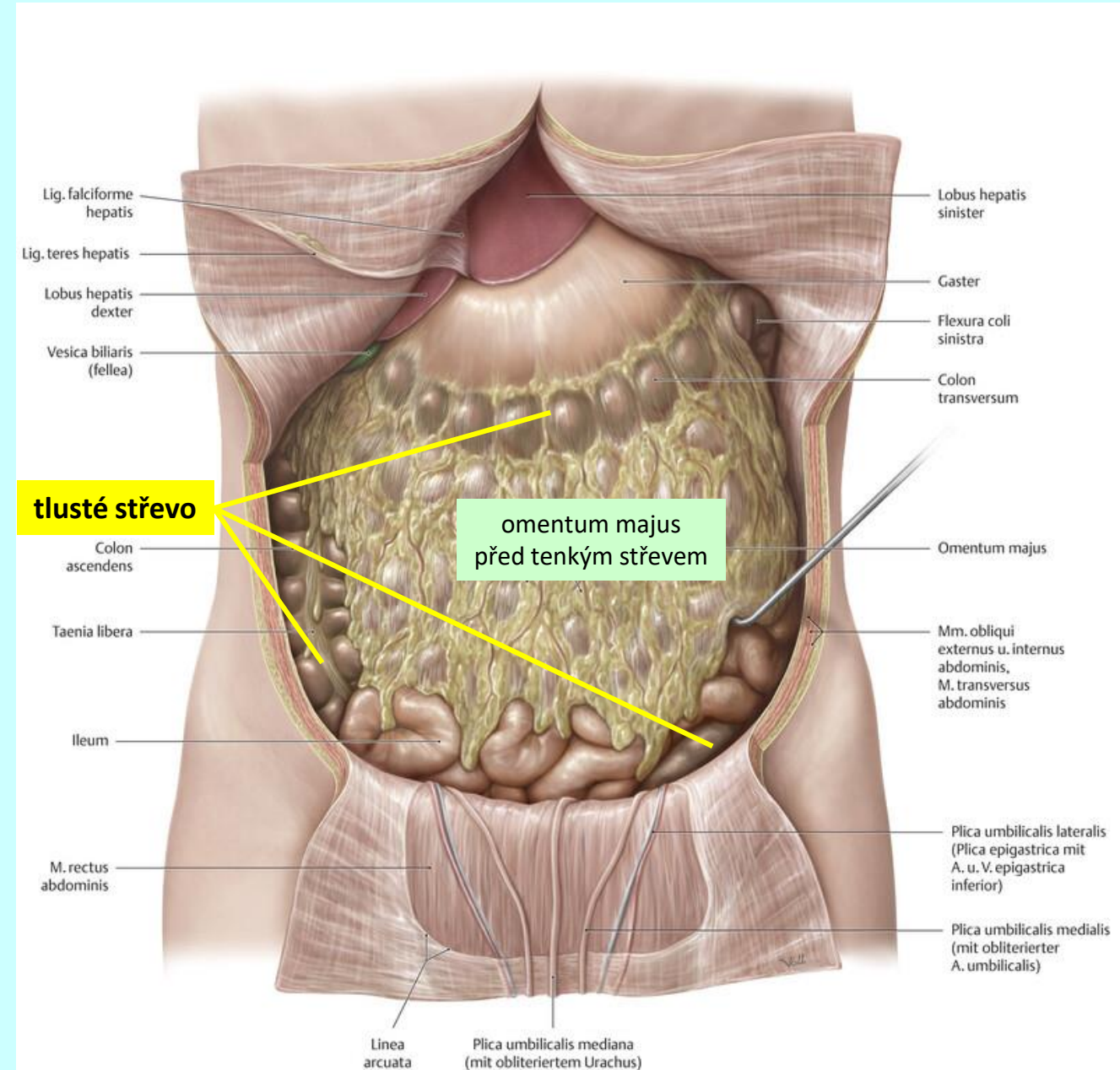
tenké střevo (*intestinum tenue*)

histologická stavba



tlusté střevo (*intestinum crassum*)

topografie



tlusté střevo (*intestinum crassum*)

makroskopická stavba

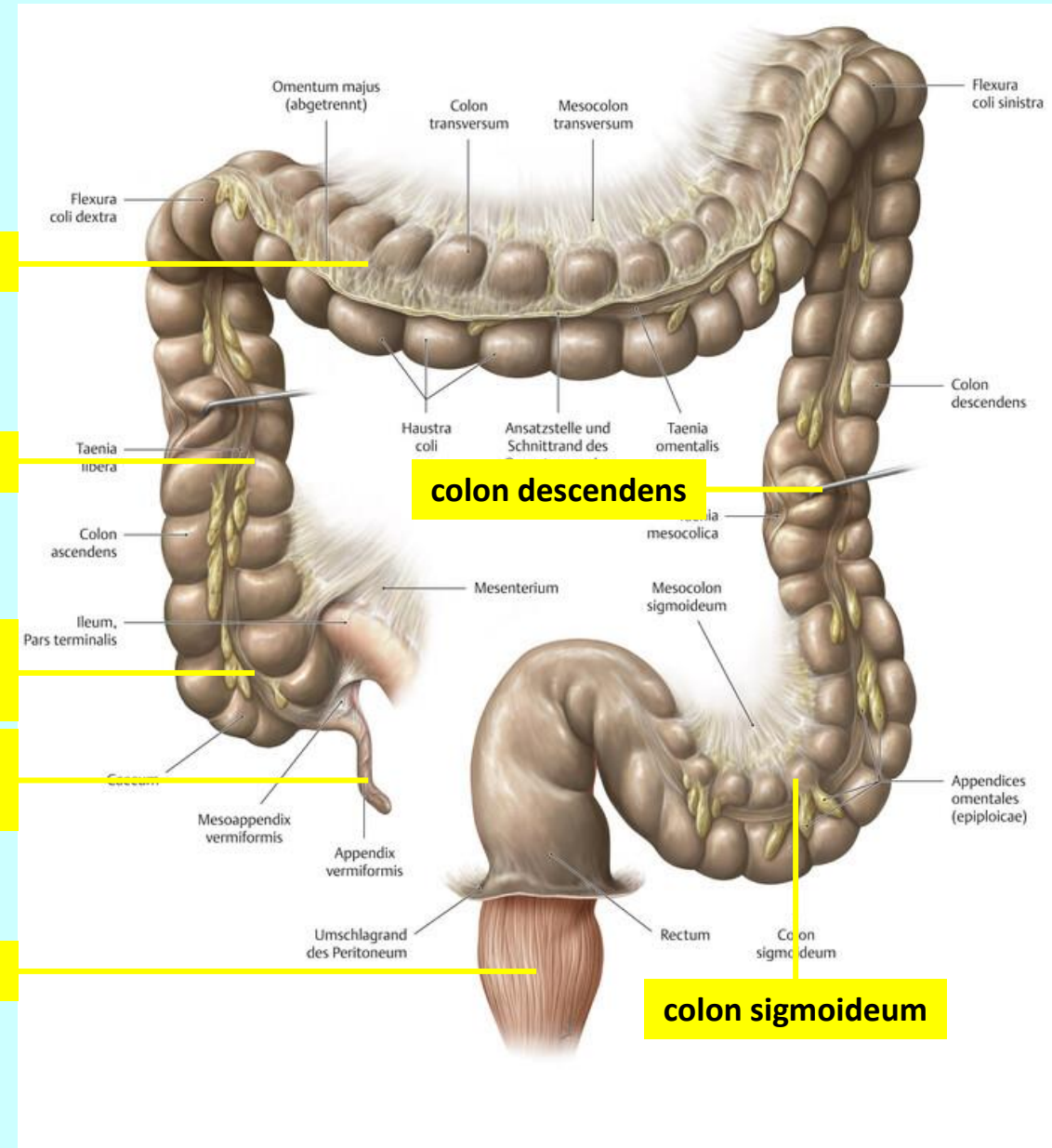
colon transversum

colon ascendens

intestinum
caecum

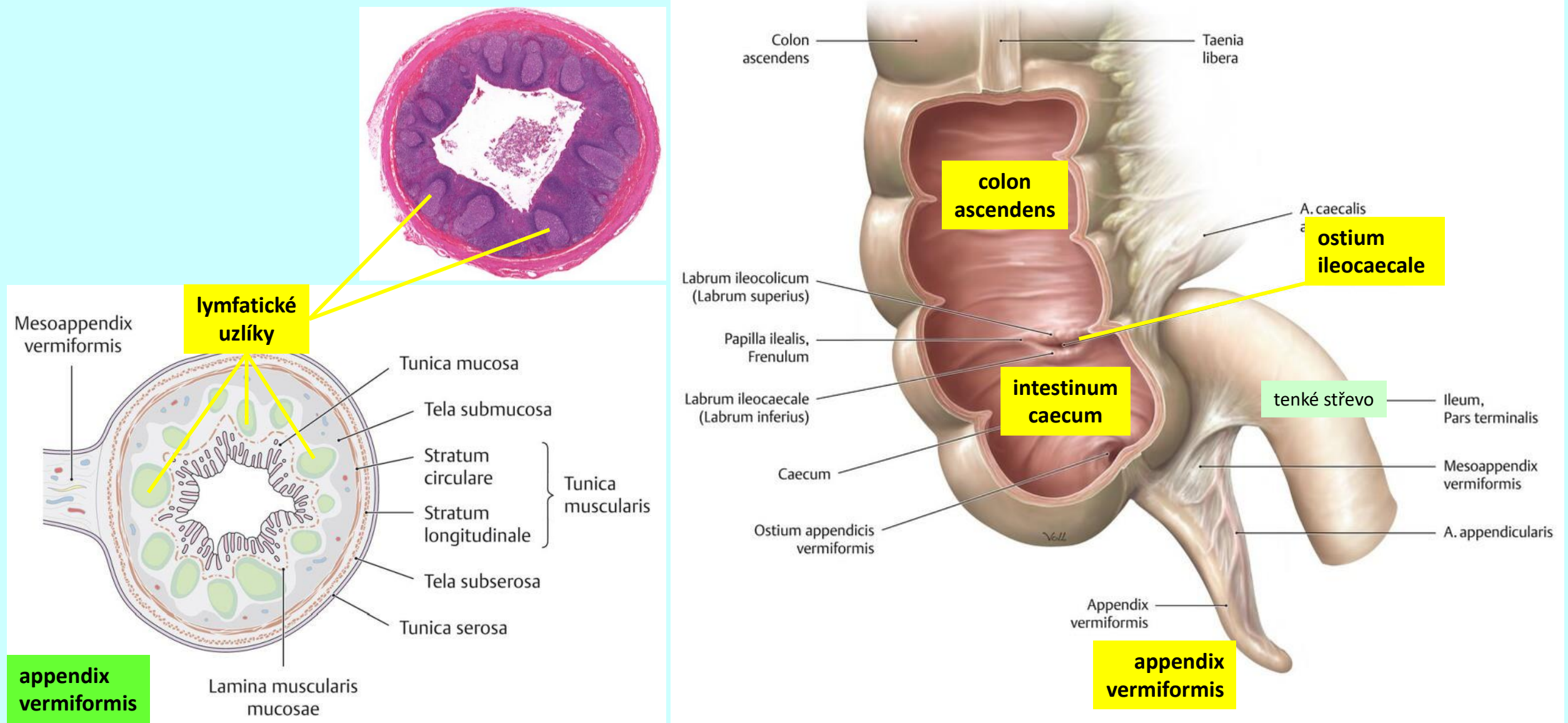
appendix
vermiformis

rectum



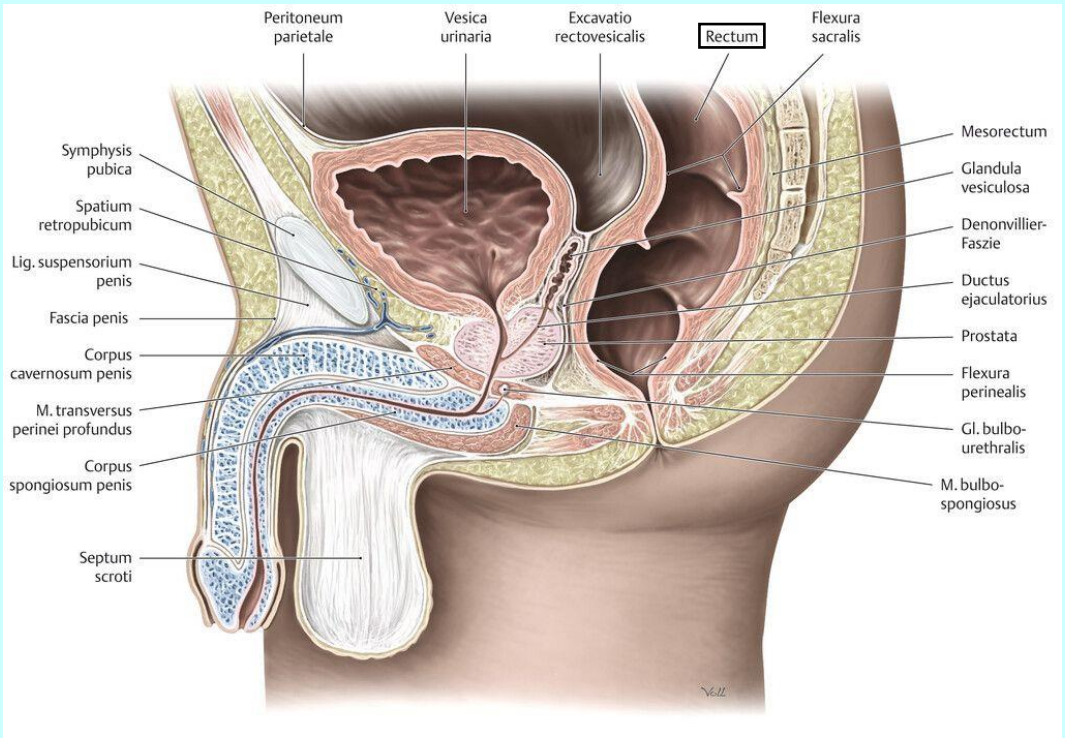
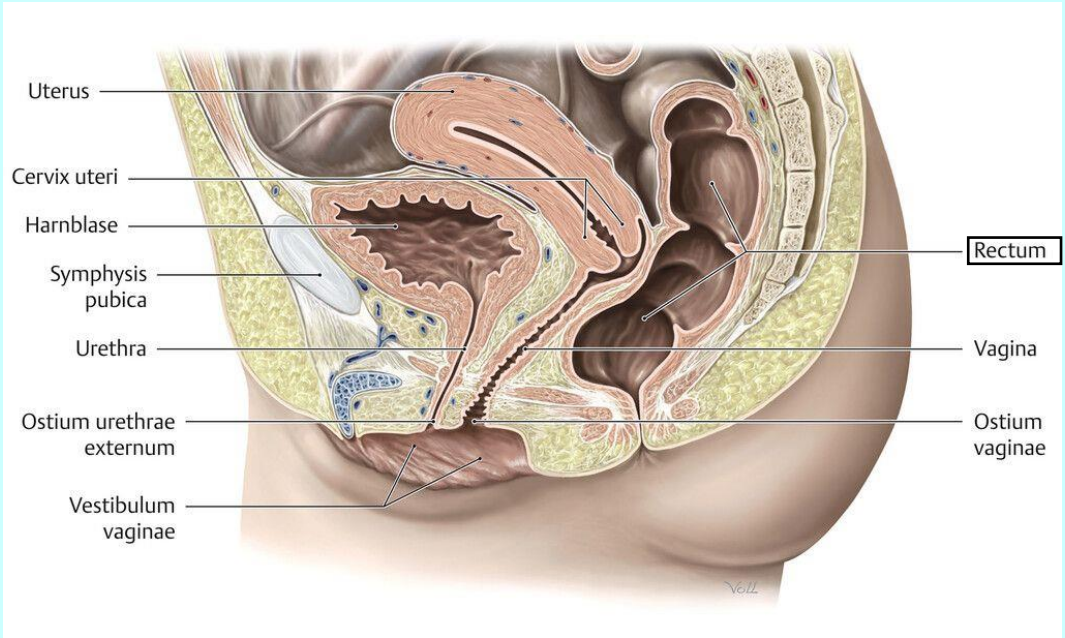
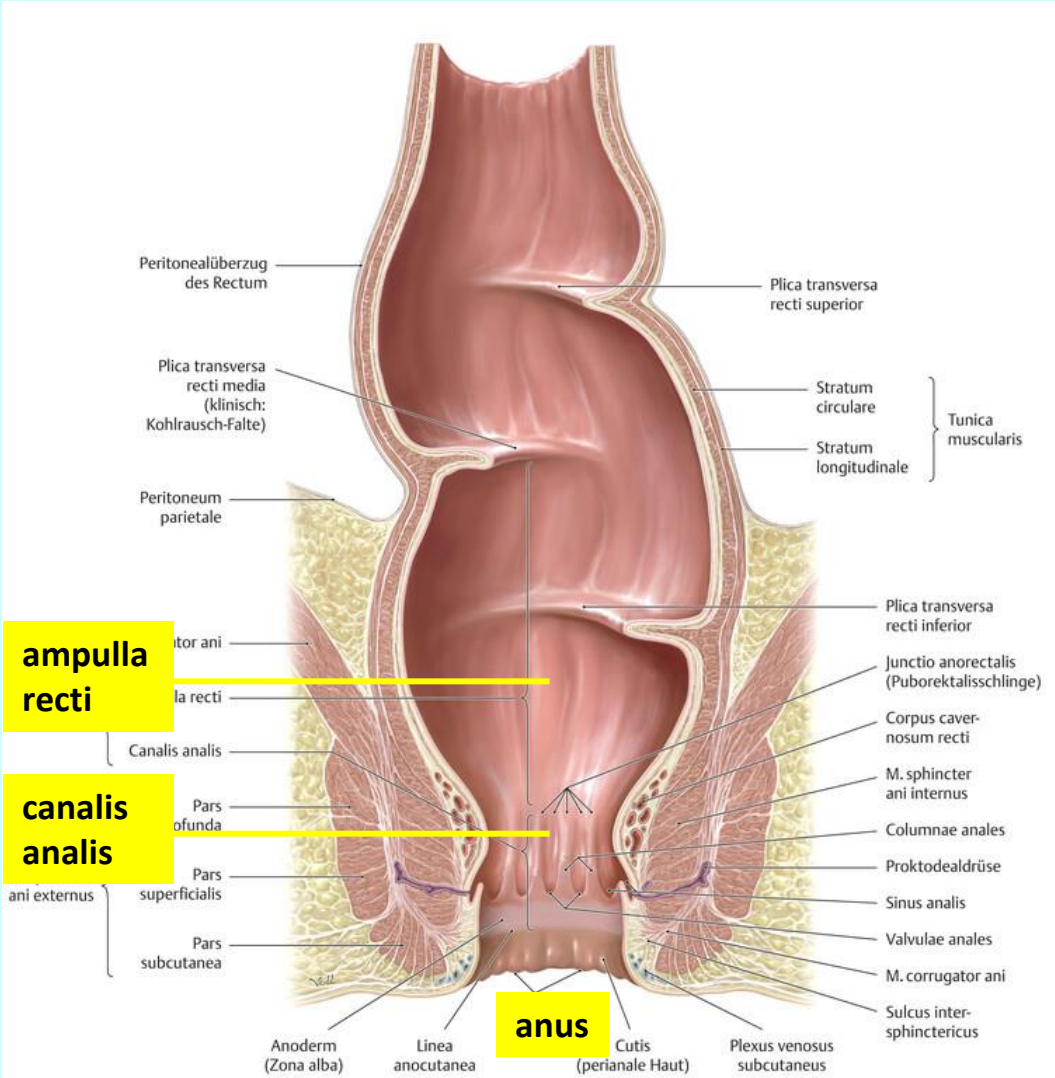
tlusté střevo (*intestinum crassum*)

makroskopická stavba



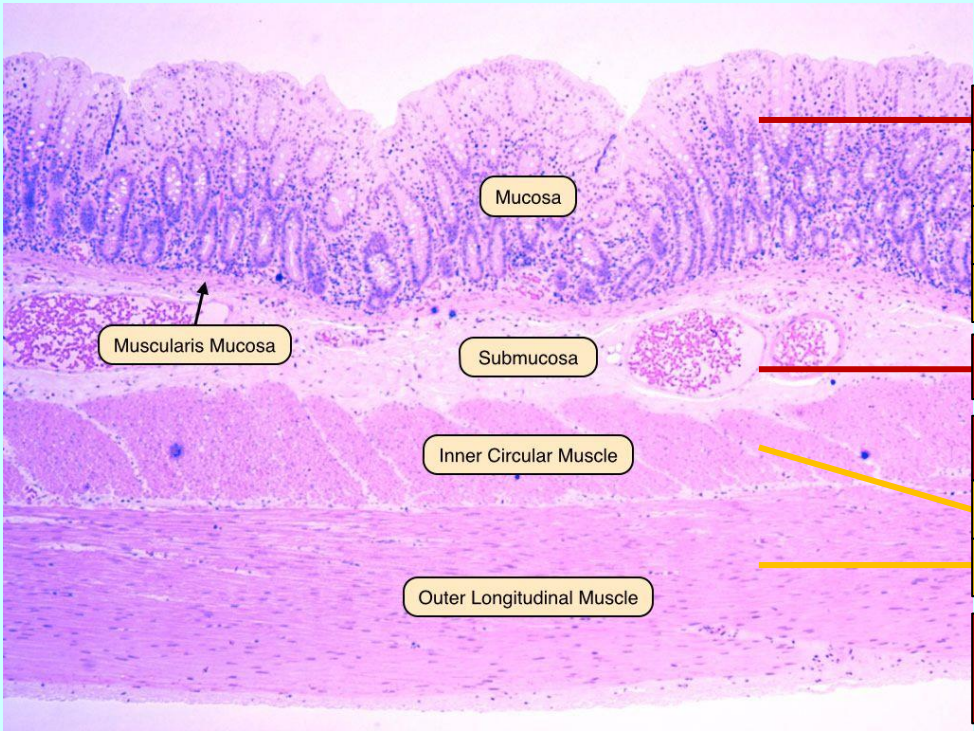
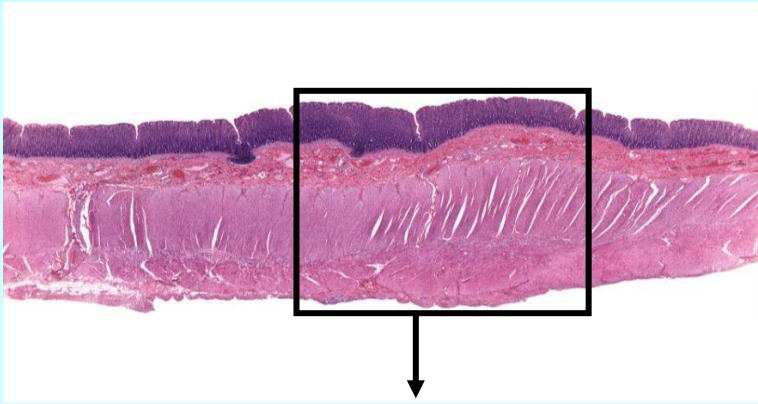
tlusté střevo (*intestinum crassum*)

makroskopická stavba

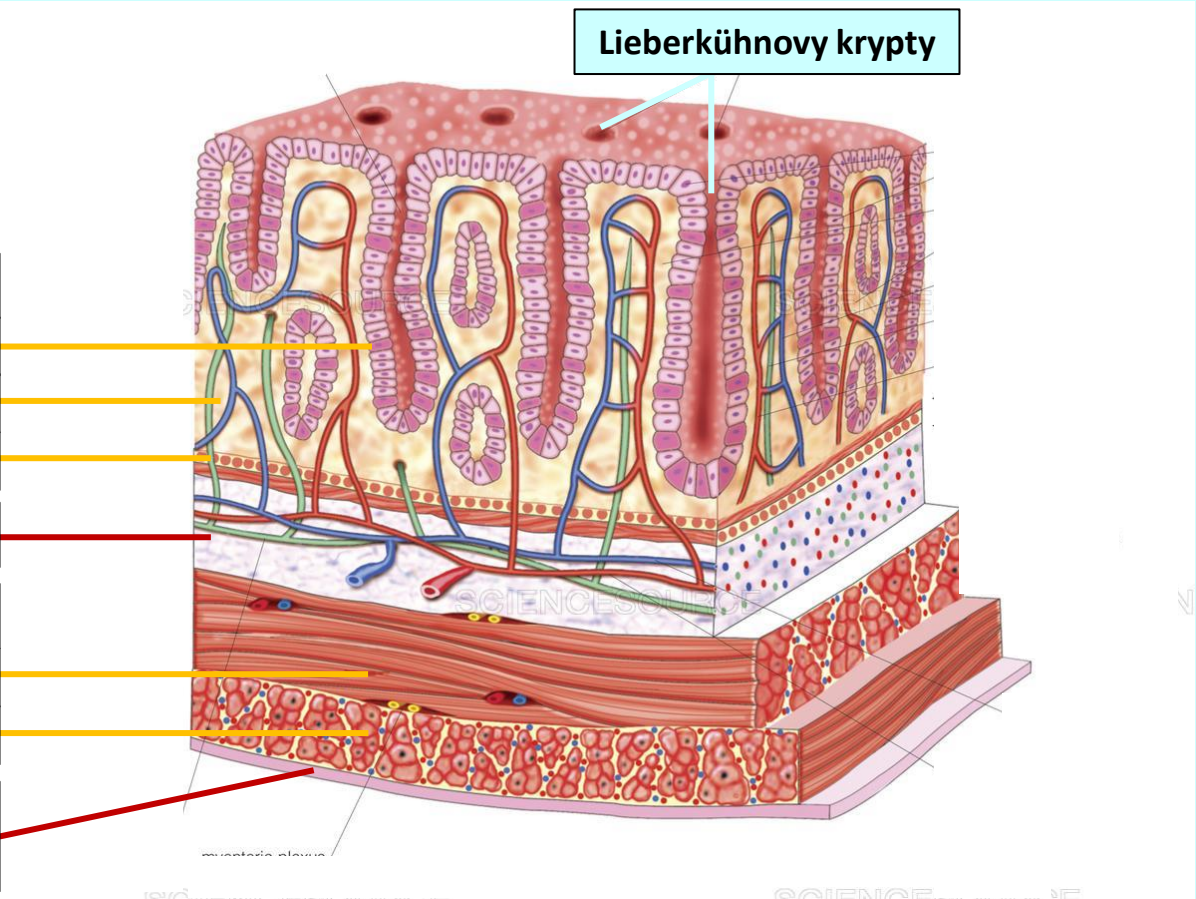


tlusté střevo (*intestinum crassum*)

histologická stavba

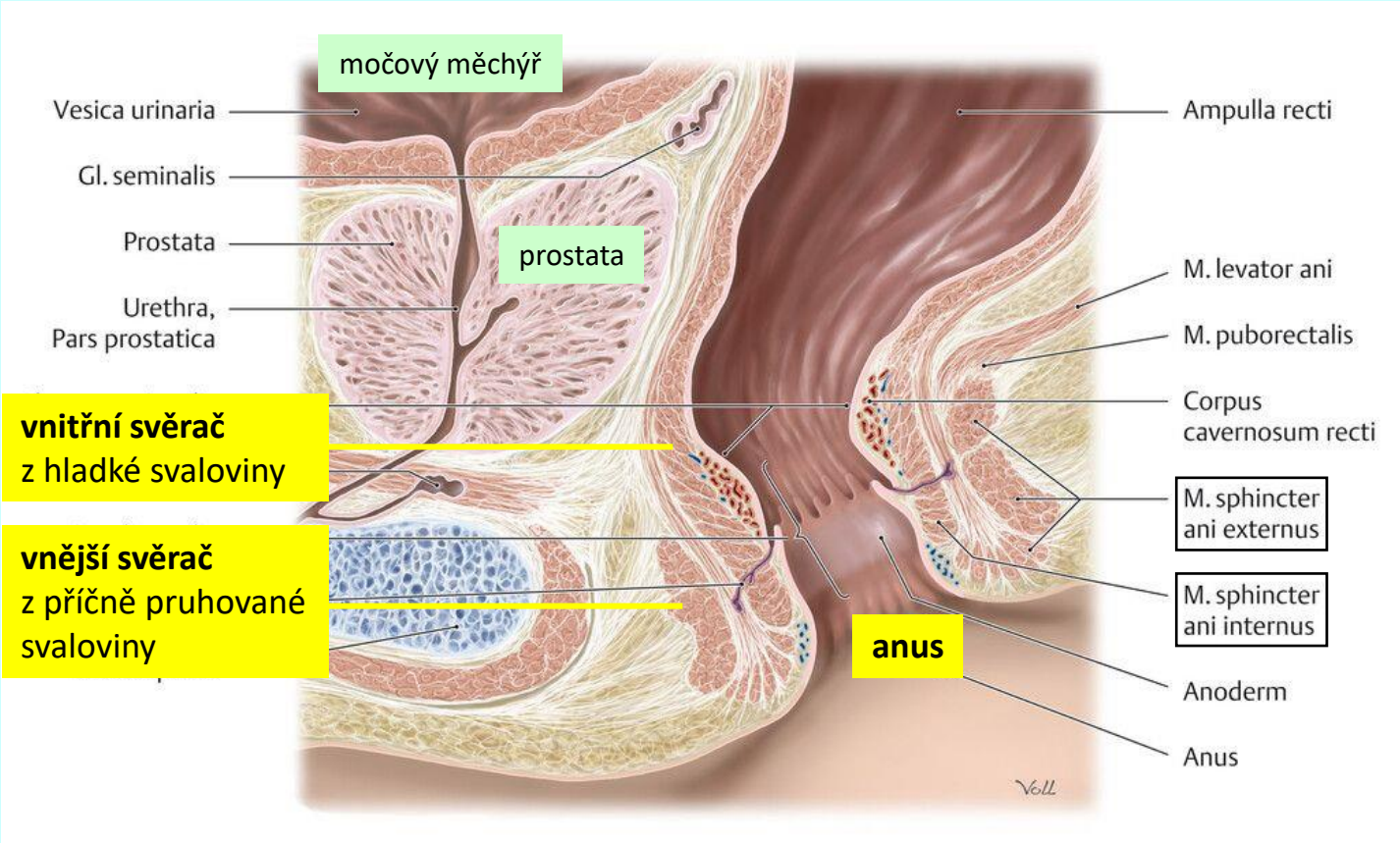
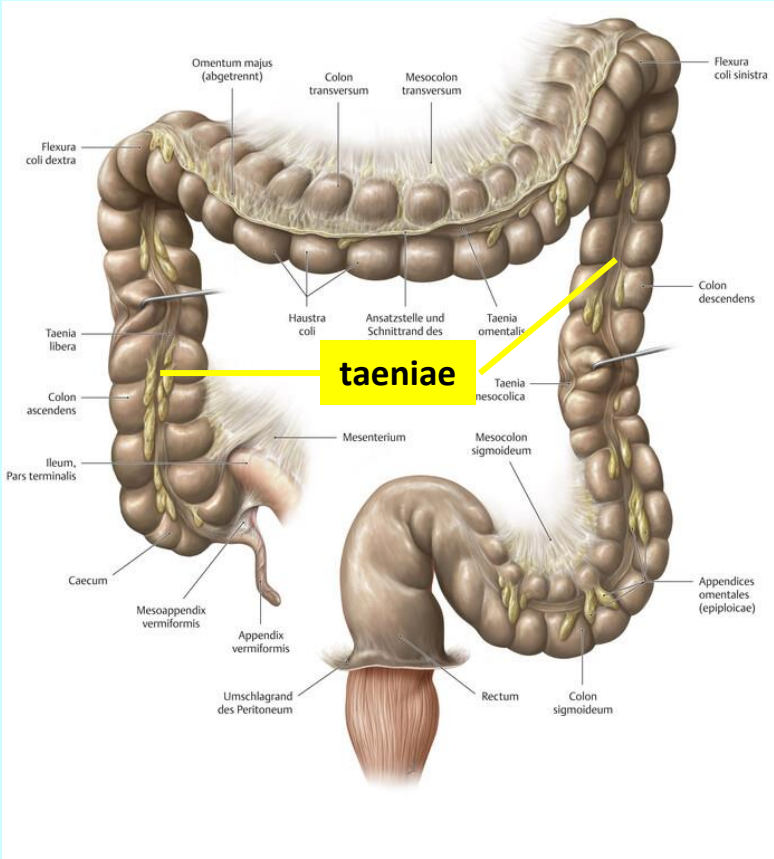
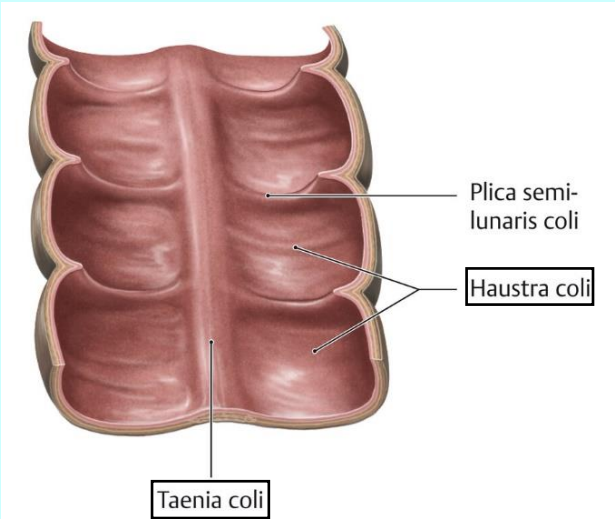


- tunica mucosa
- lamina epithelialis
- lamina propria
- lamina muscularis
- tela submucosa
- tunica muscularis
- stratum circulare
- stratum longitudinale
- tunica externa serosa



tlusté střevo (*intestinum crassum*)

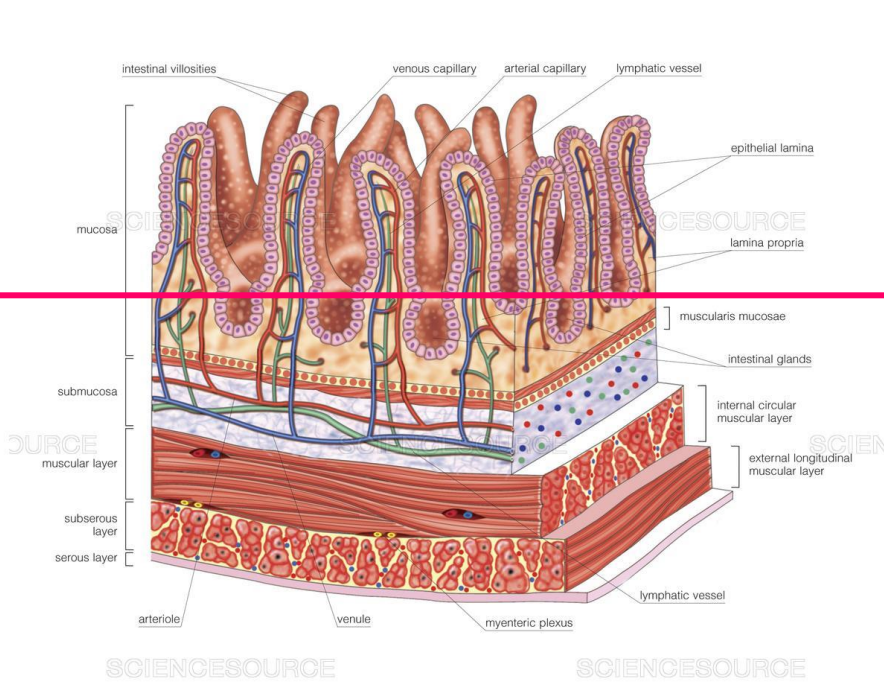
histologická stavba



trávicí trubice

porovnání histologické stavby

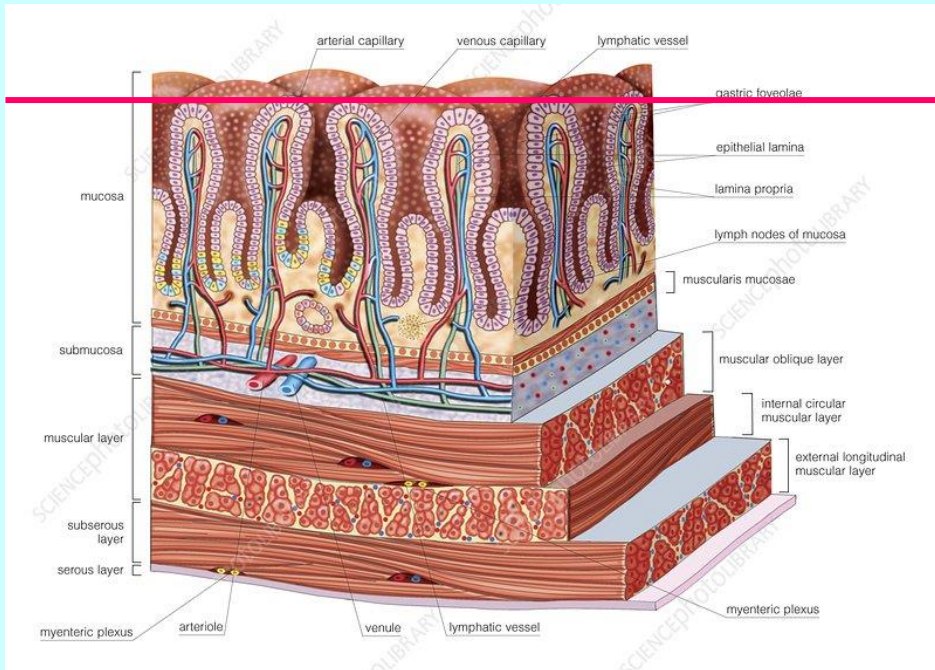
everze
(klky)
↑
povrch sliznice
↓
inverze
(Lieberkühnovy
krypty)



tenké střevo

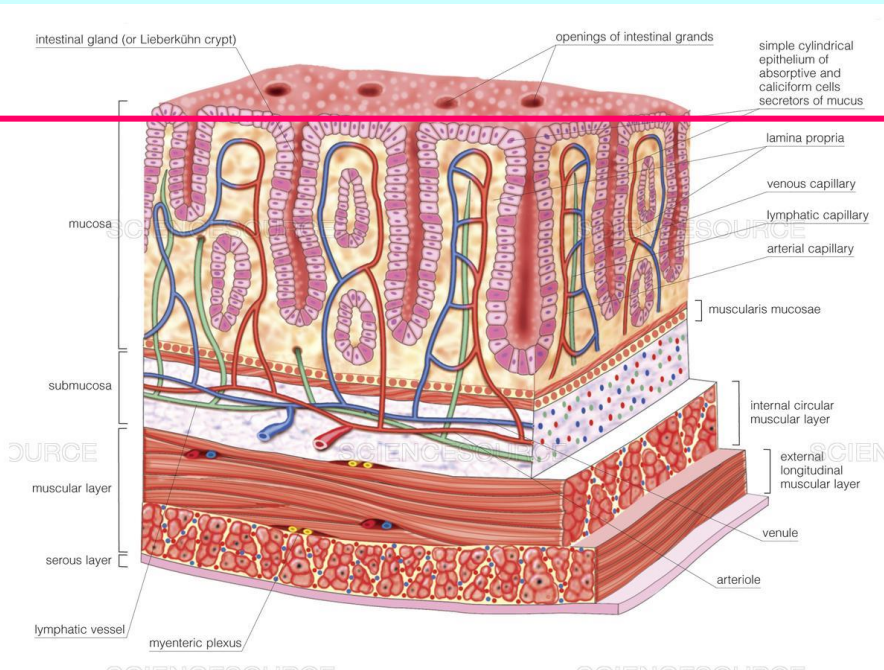
povrch sliznice
↓
inverze
(žaludeční
žlásky)

žaludek



povrch sliznice
↓
inverze
(Lieberkühnovy
krypty)

tlusté střevo



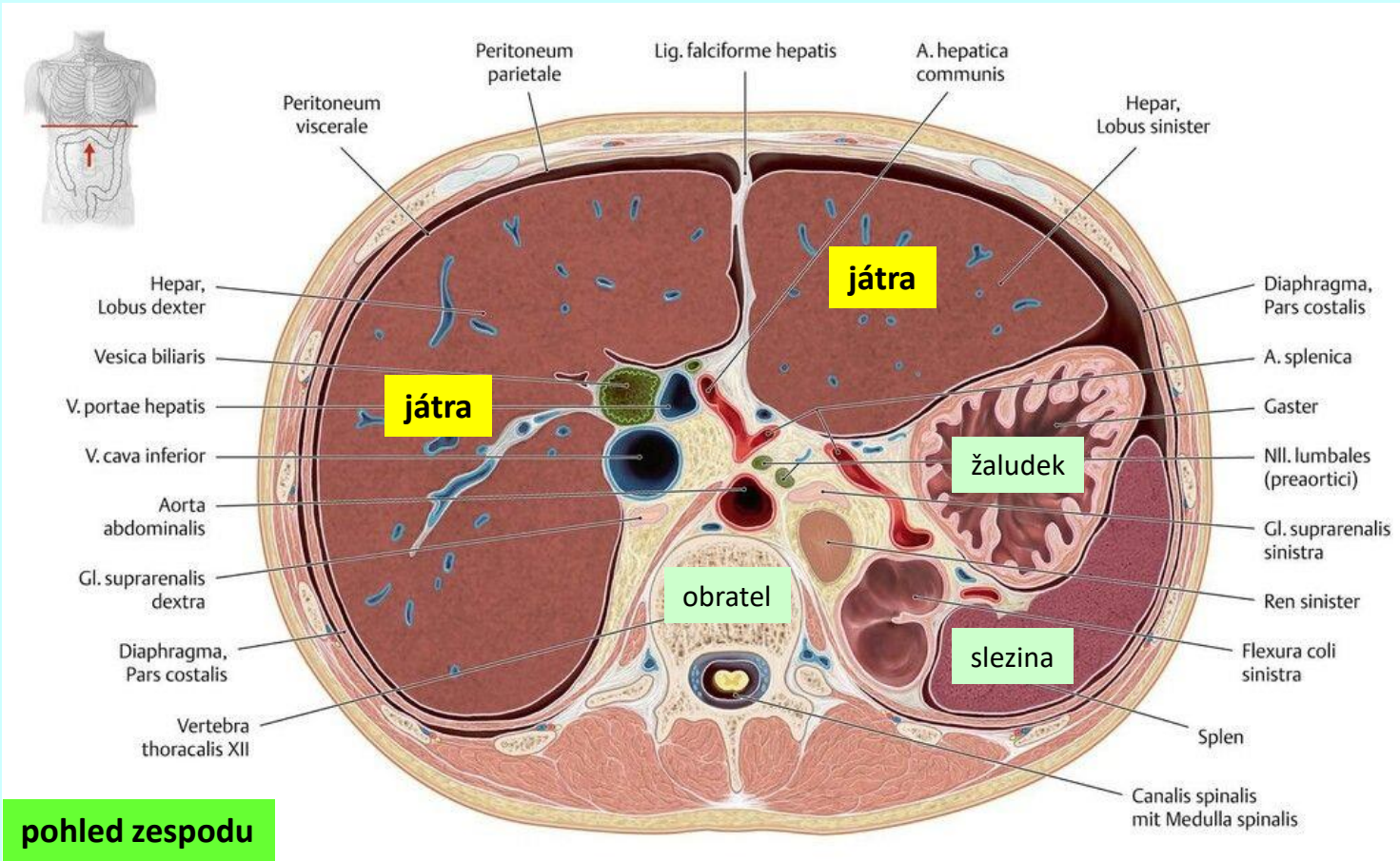
TRÁVICÍ SOUSTAVA

(Systema digestorium)

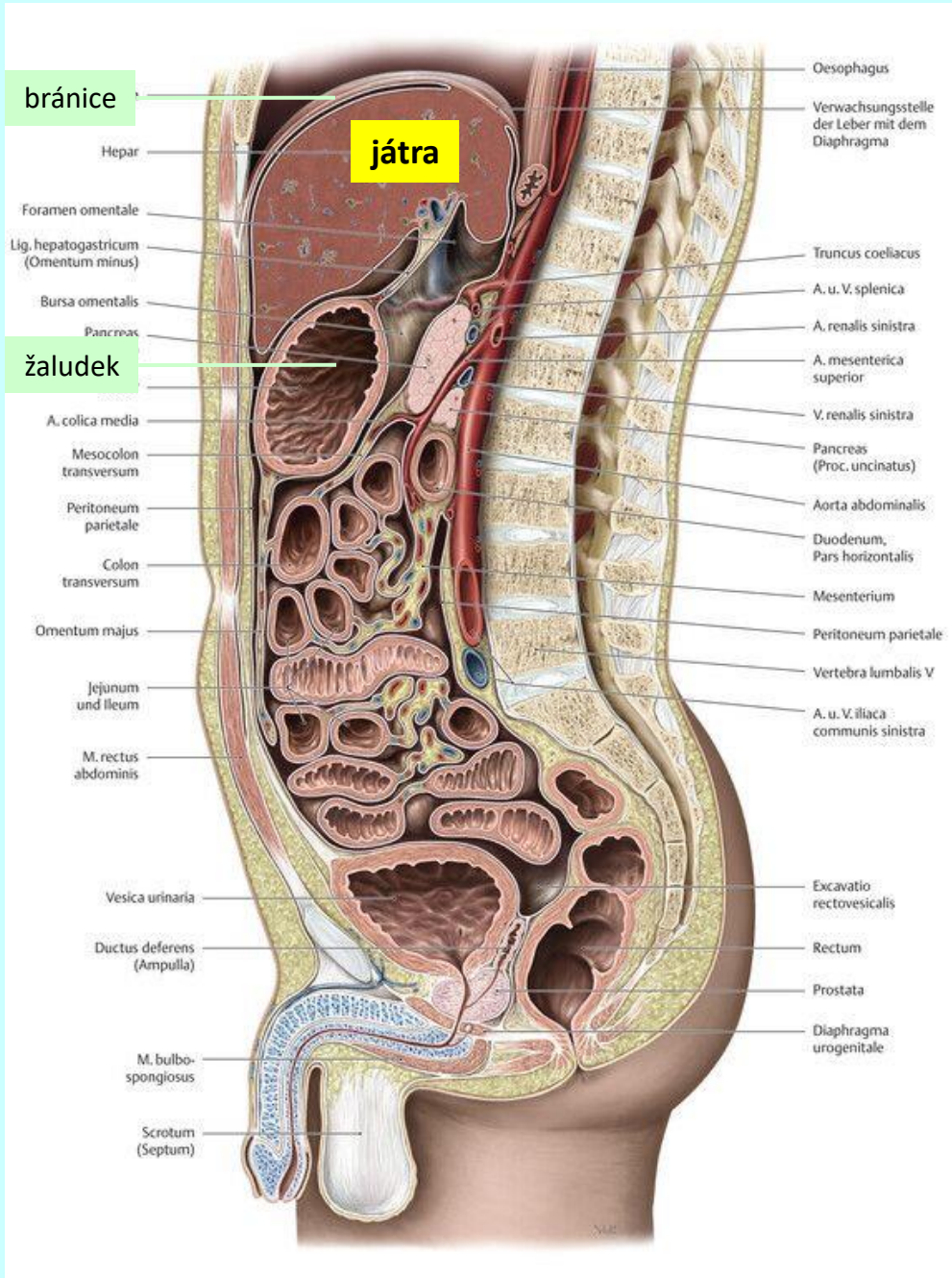
velké žlázy

játra (hepar)

topografie

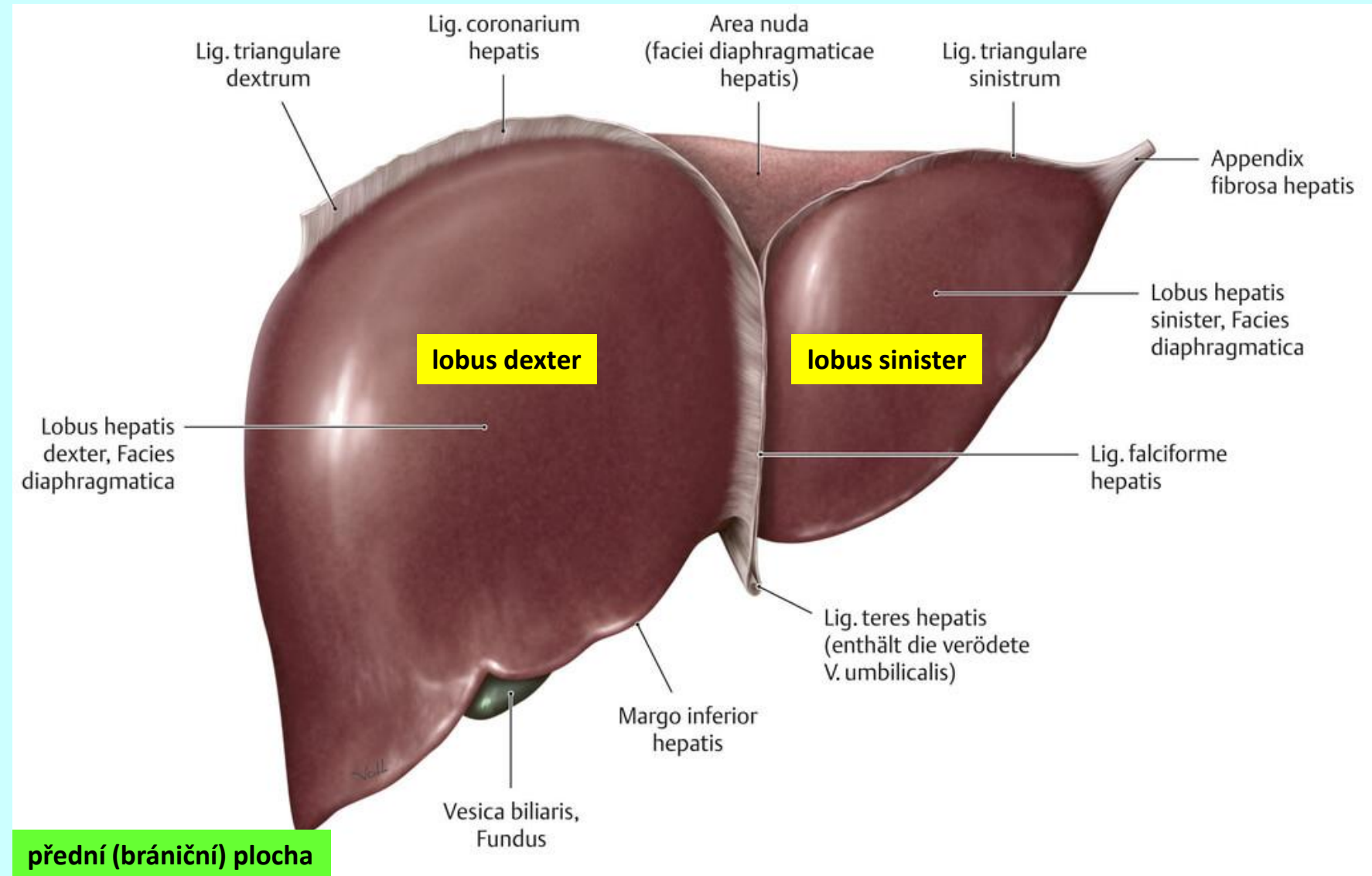


pohled zespodu



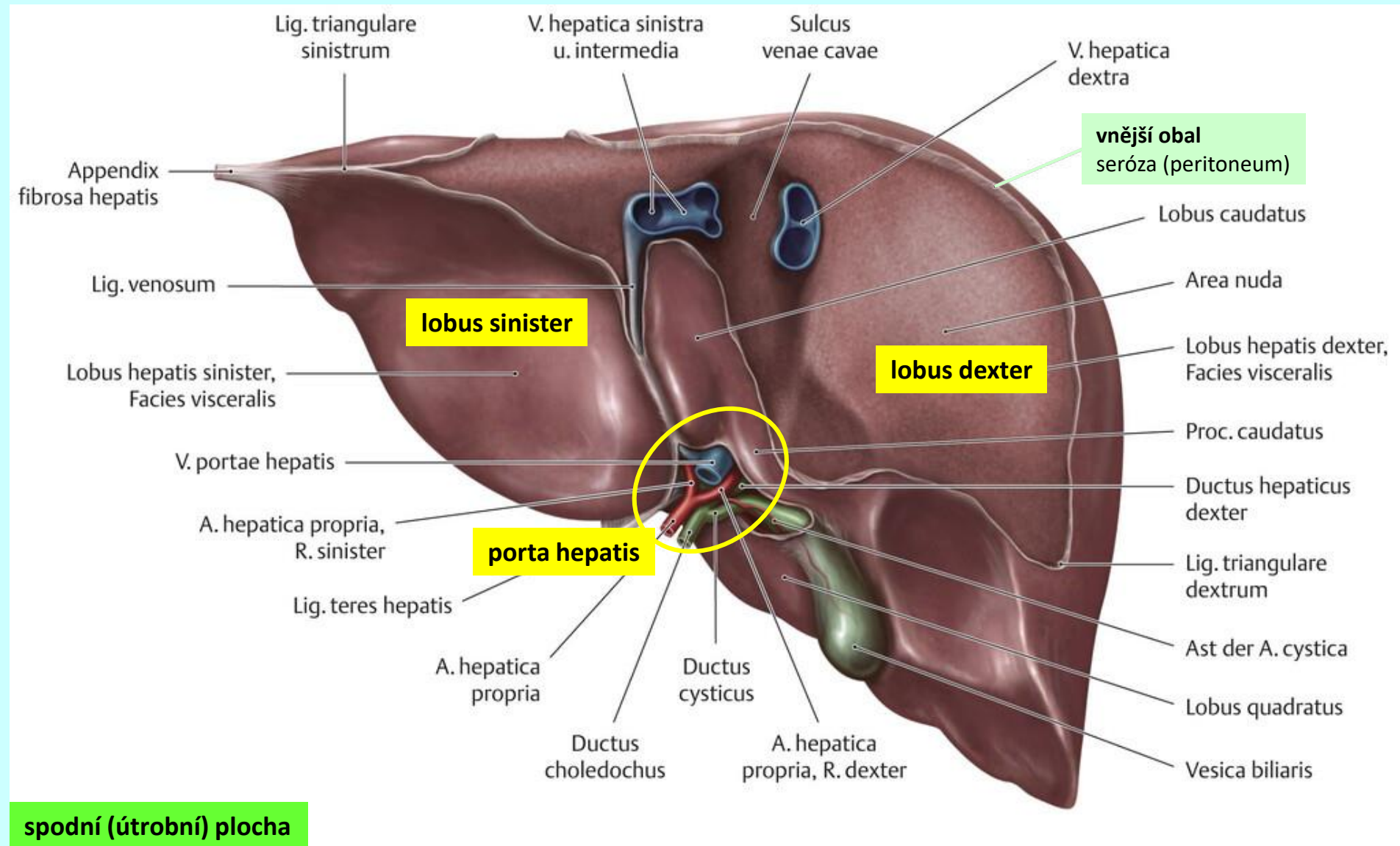
játra (*hepar*)

makroskopická stavba



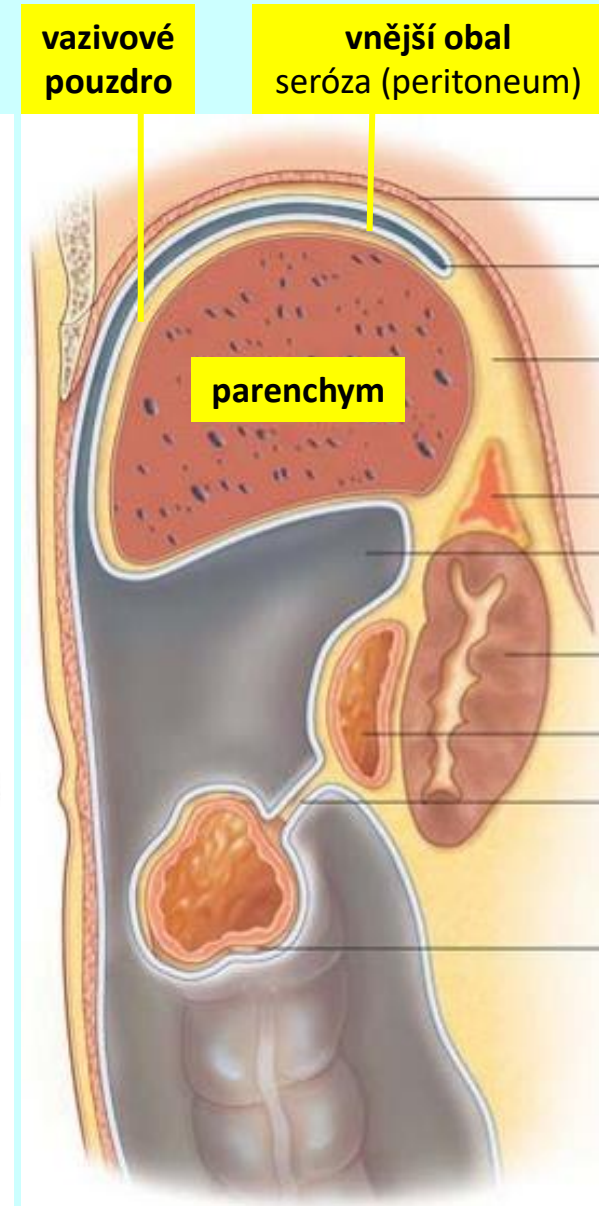
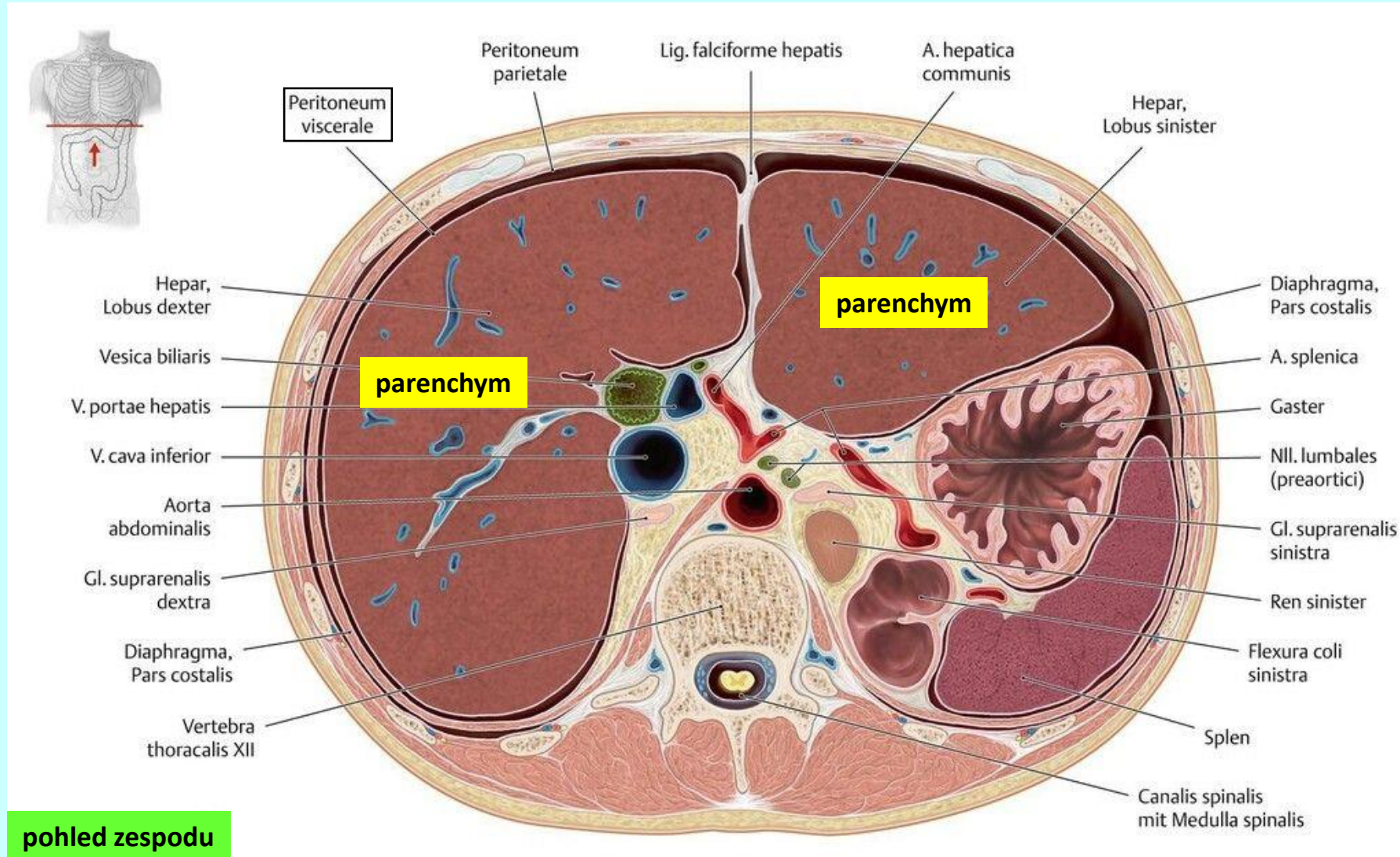
játra (*hepar*)

makroskopická stavba



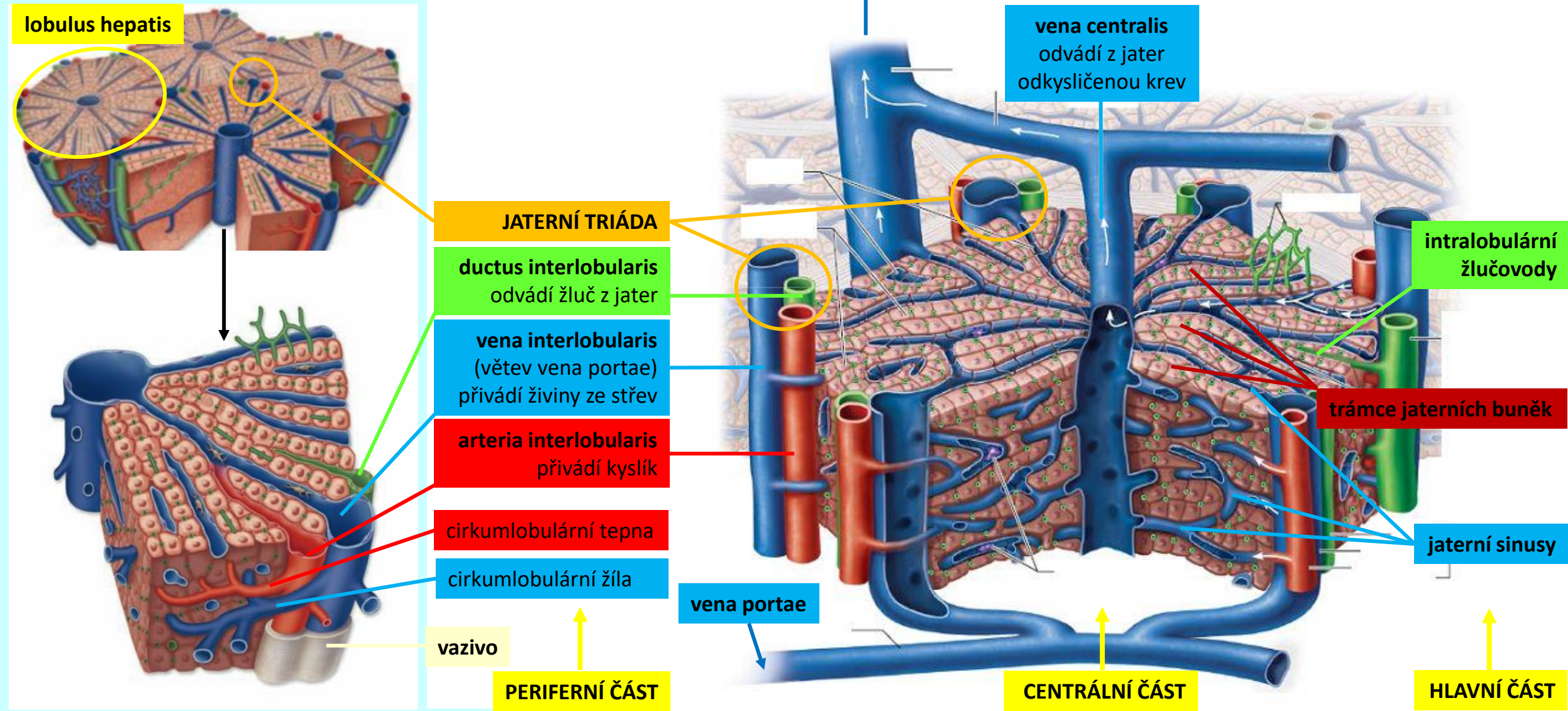
játra (*hepar*)

histologická stavba



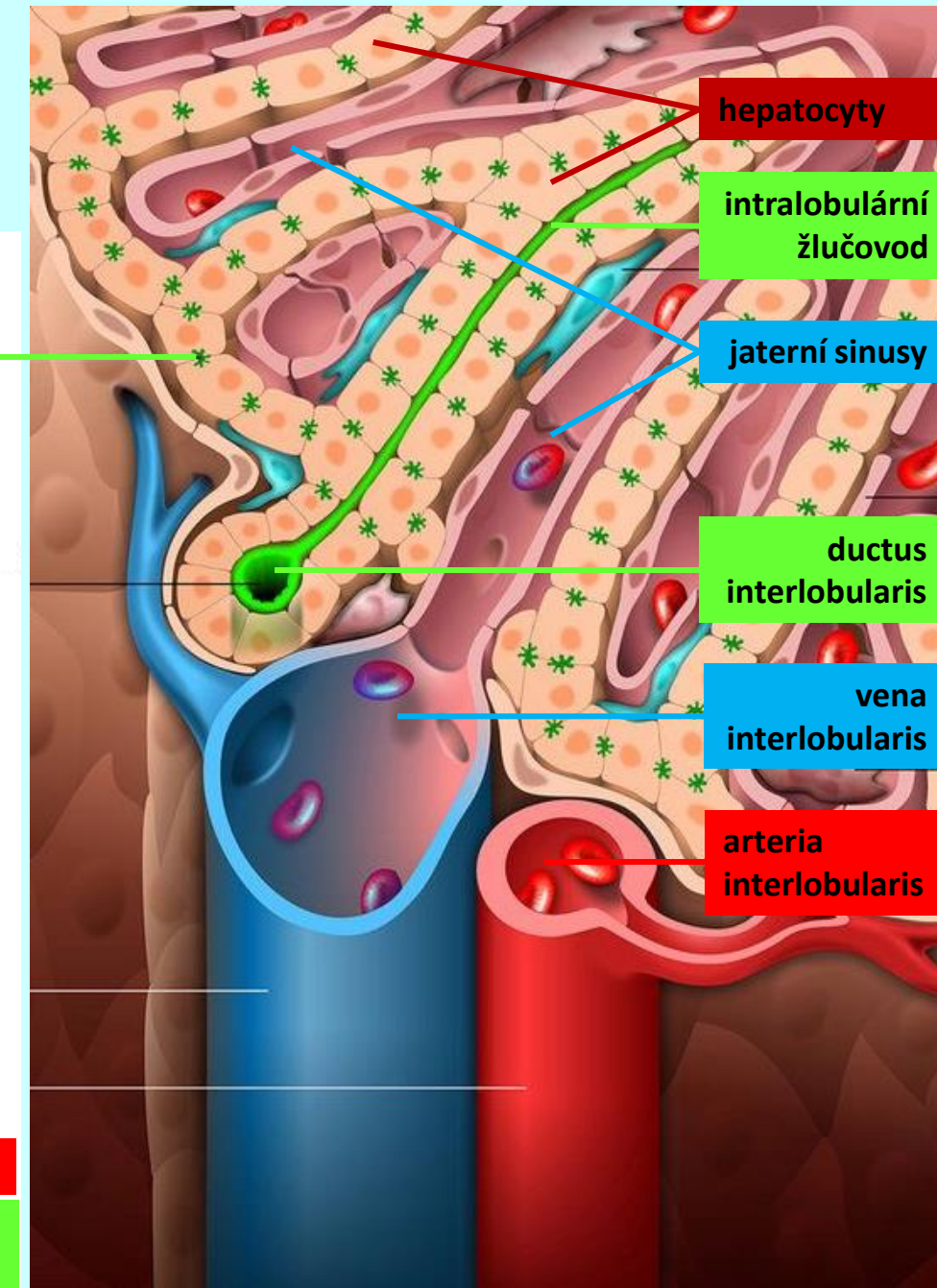
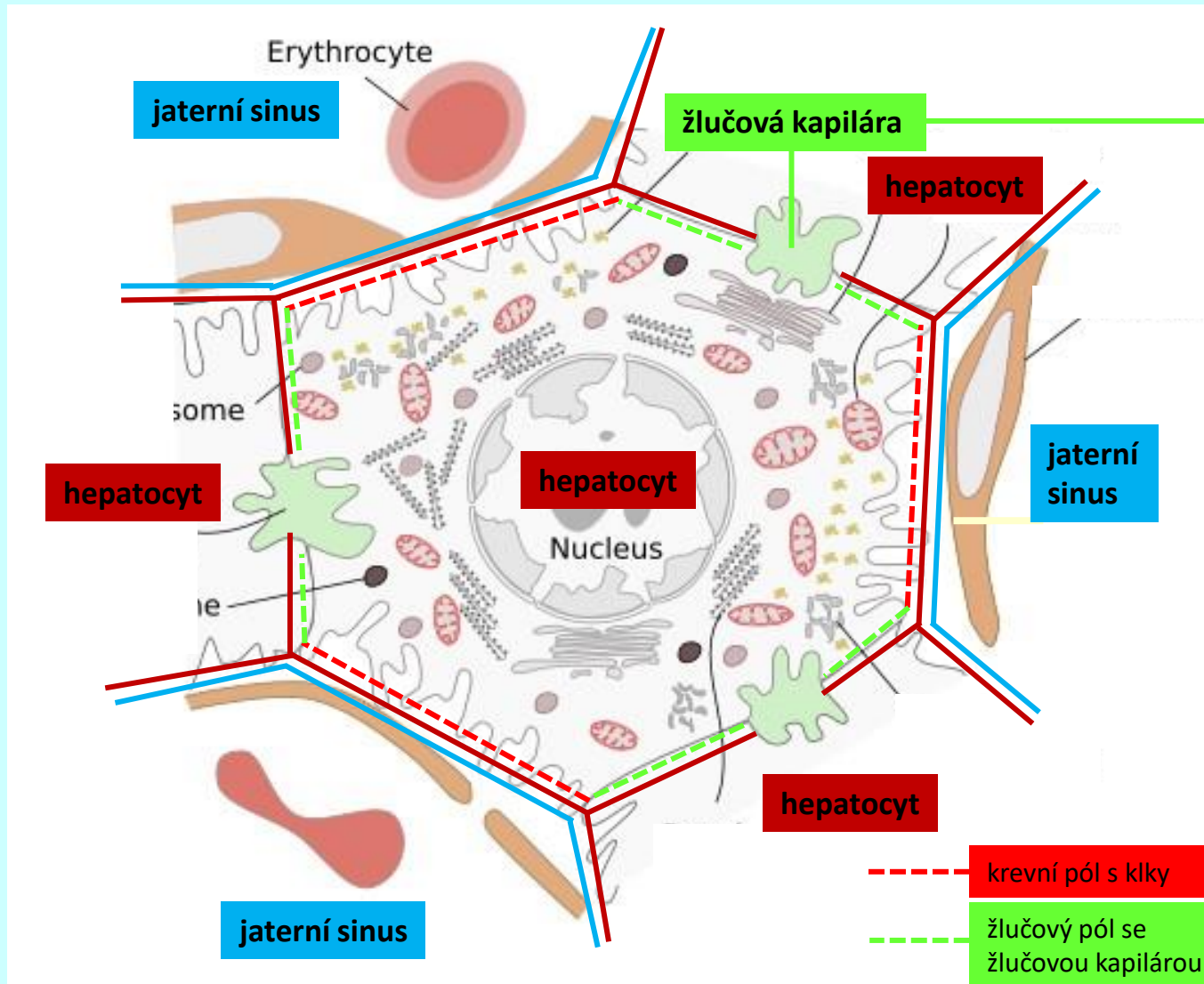
játra (*hepar*)

histologická stavba



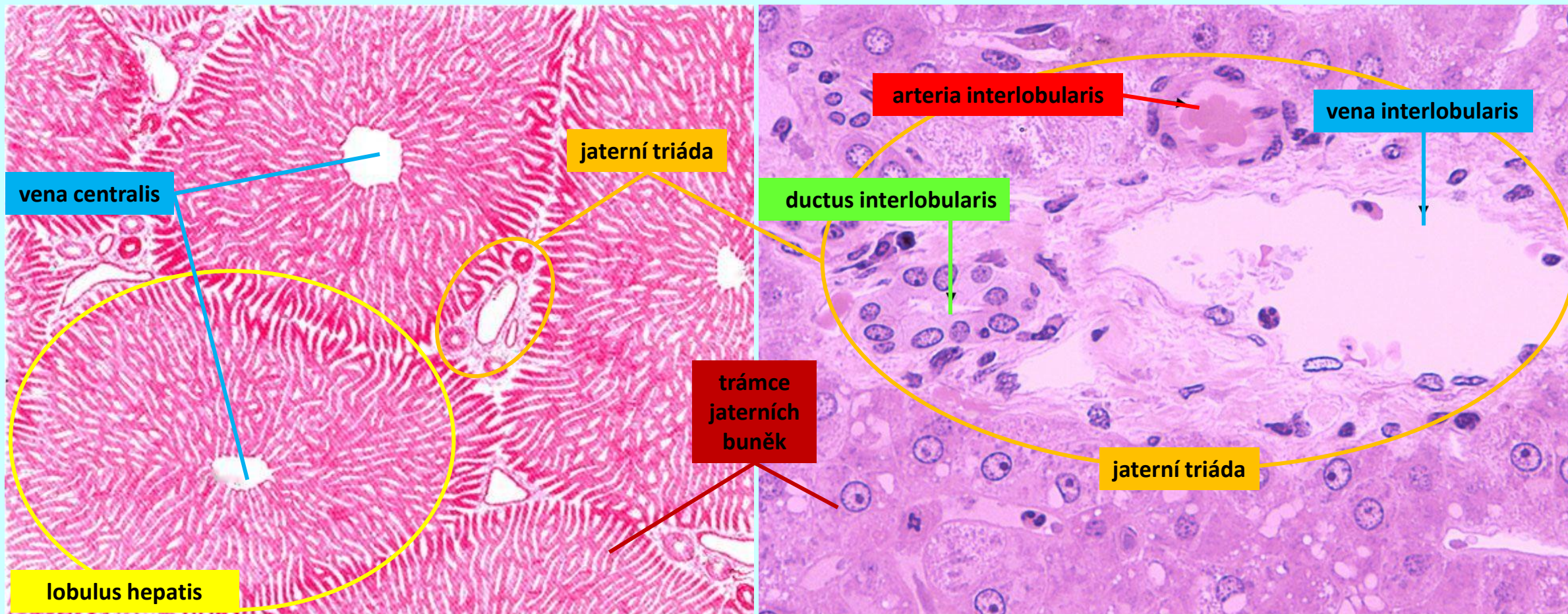
játra (*hepar*)

histologická stavba



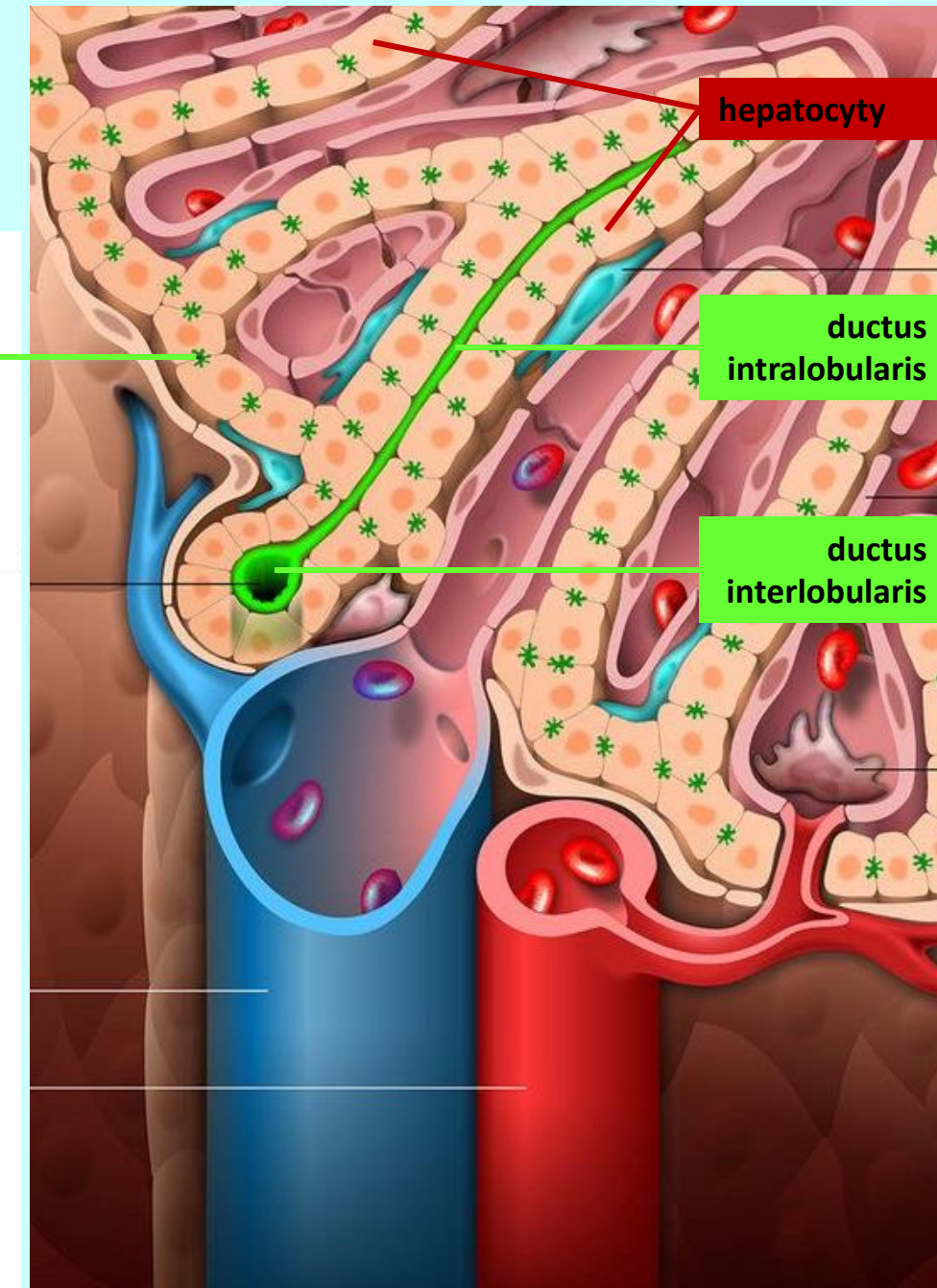
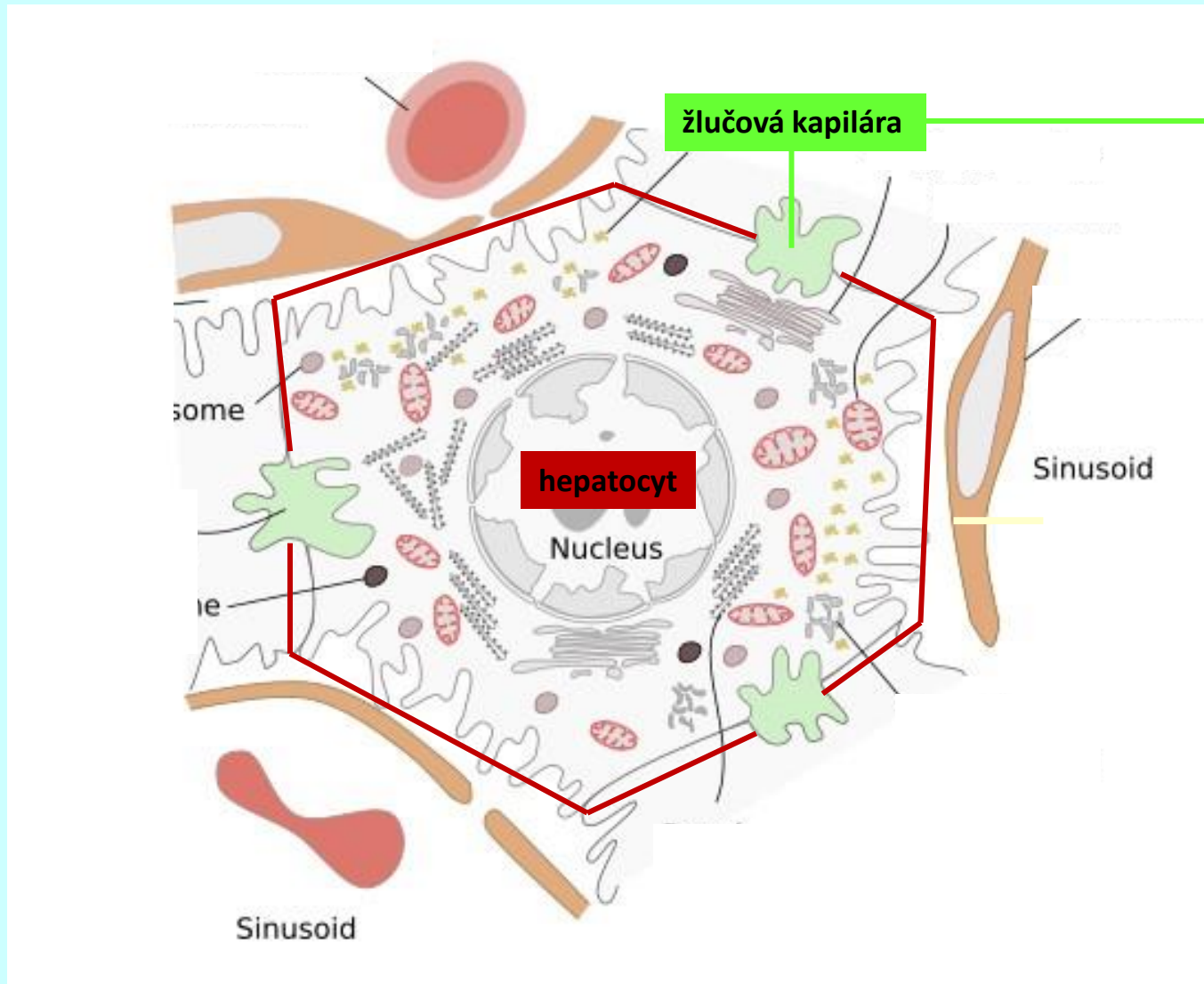
játra (*hepar*)

histologická stavba



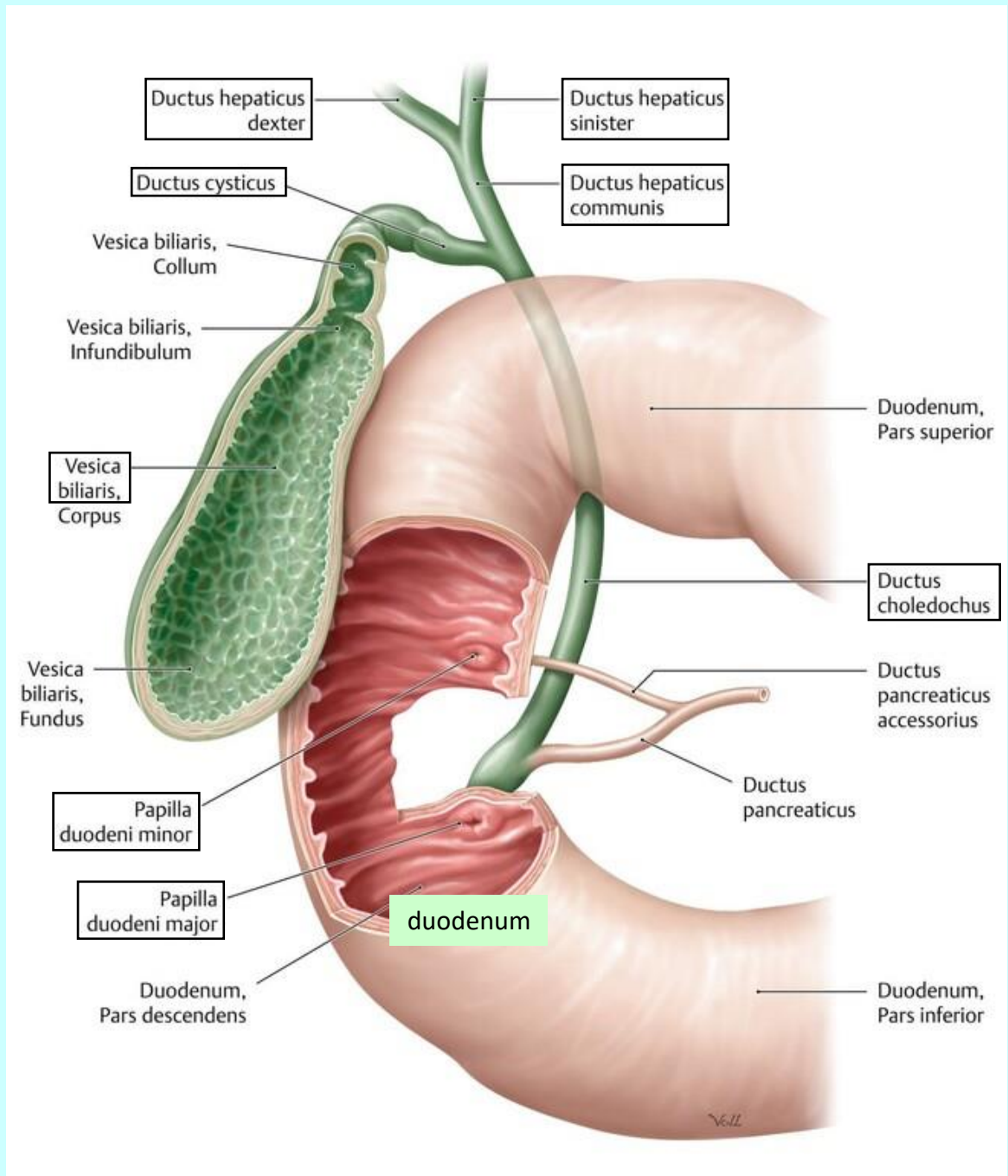
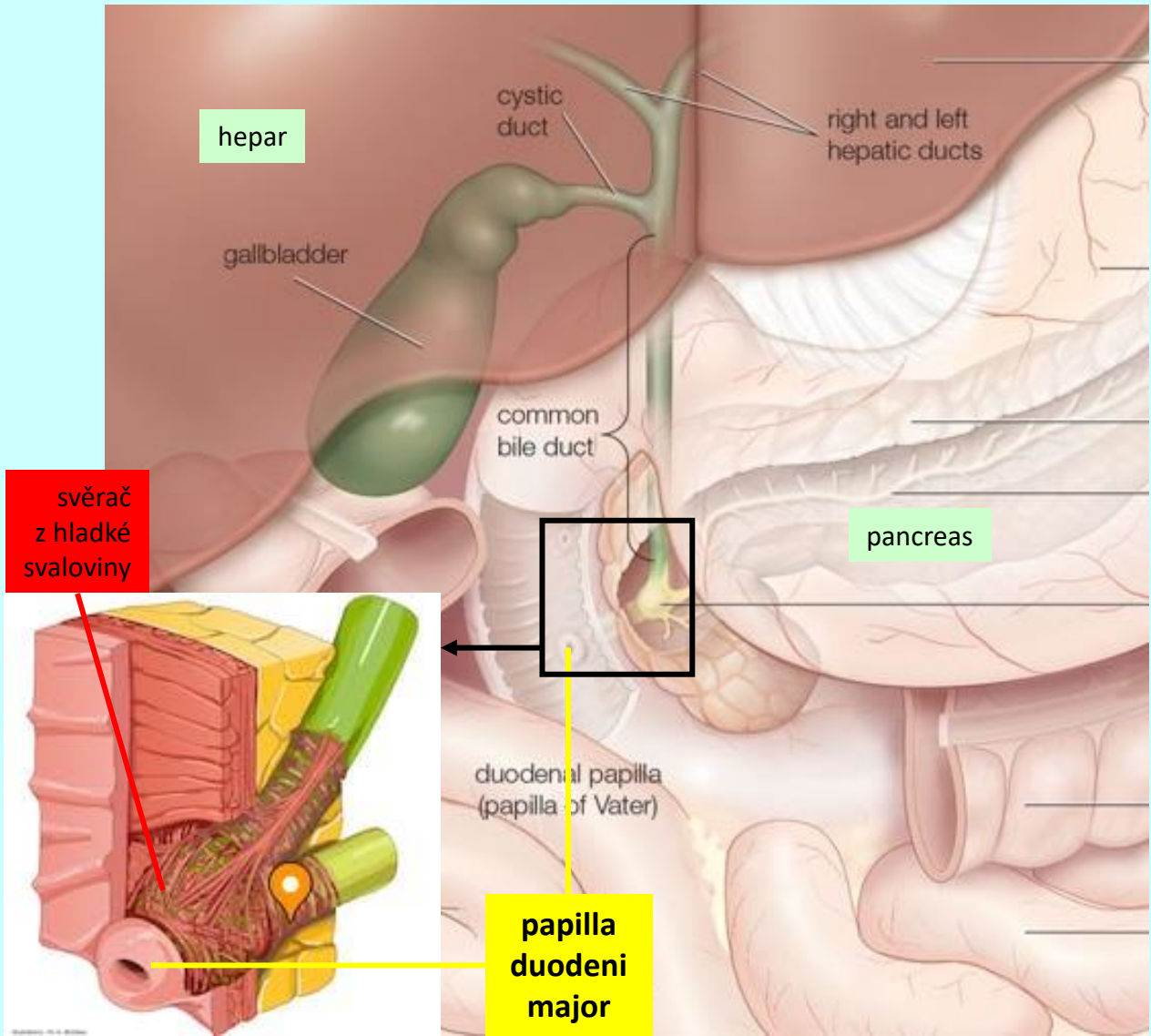
žlučové cesty (*ductus biliares*)

nitrojátrní vývody

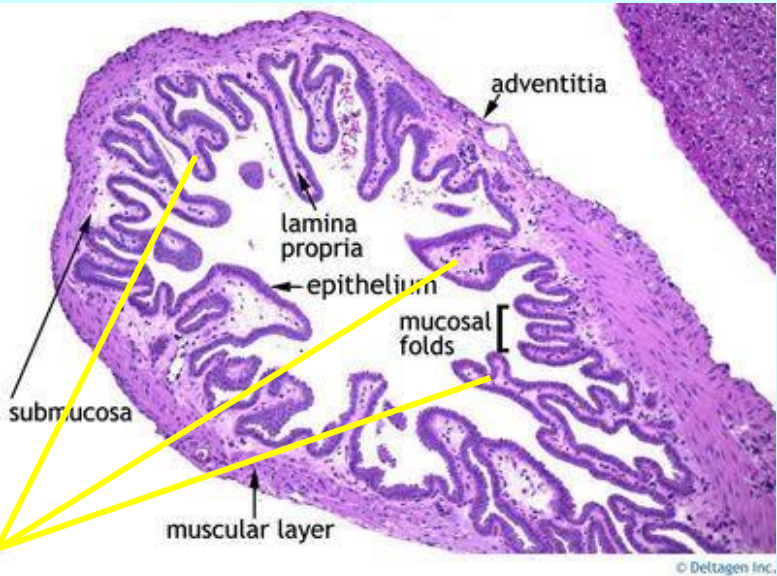


žlučové cesty (*ductus biliares*)

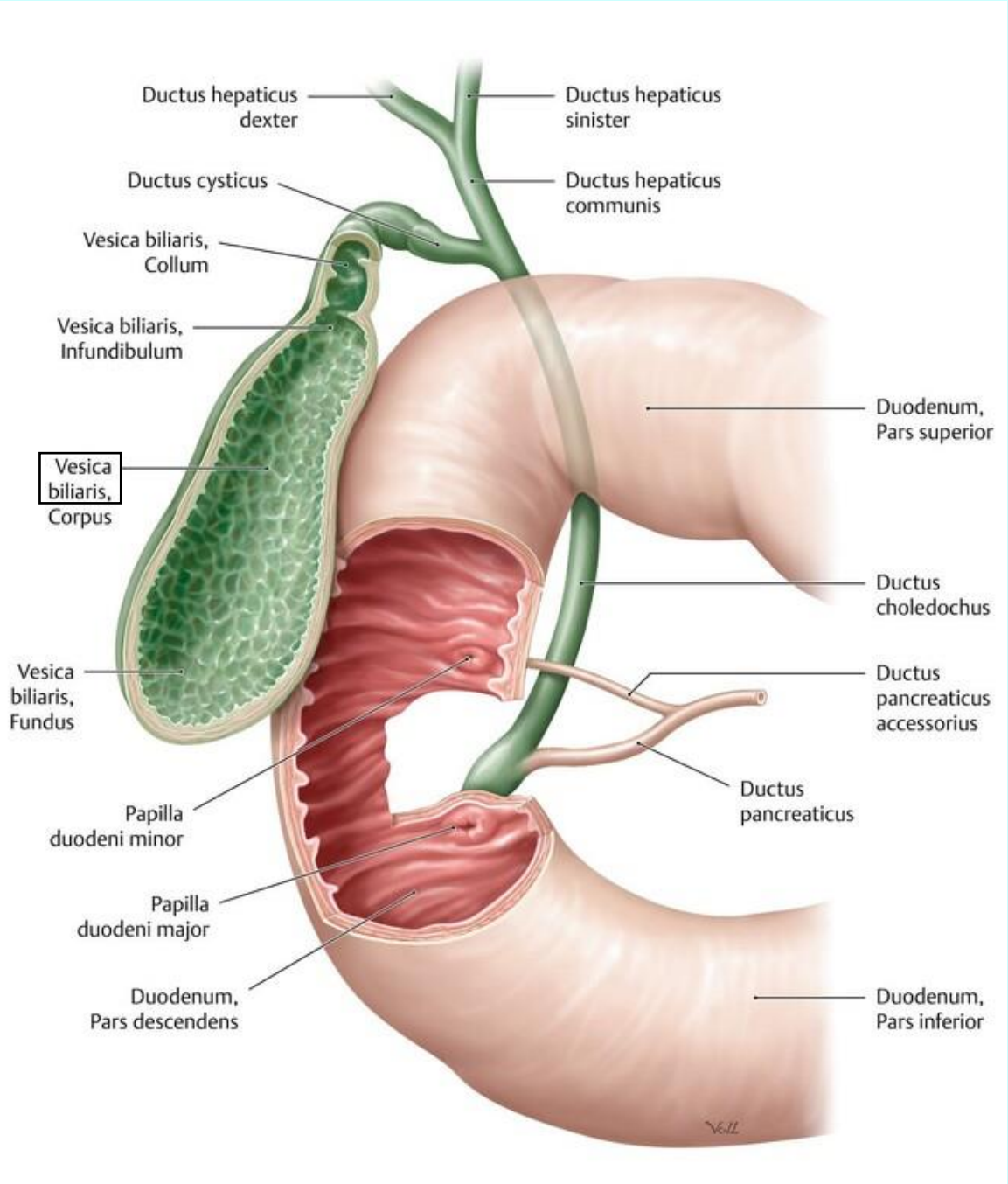
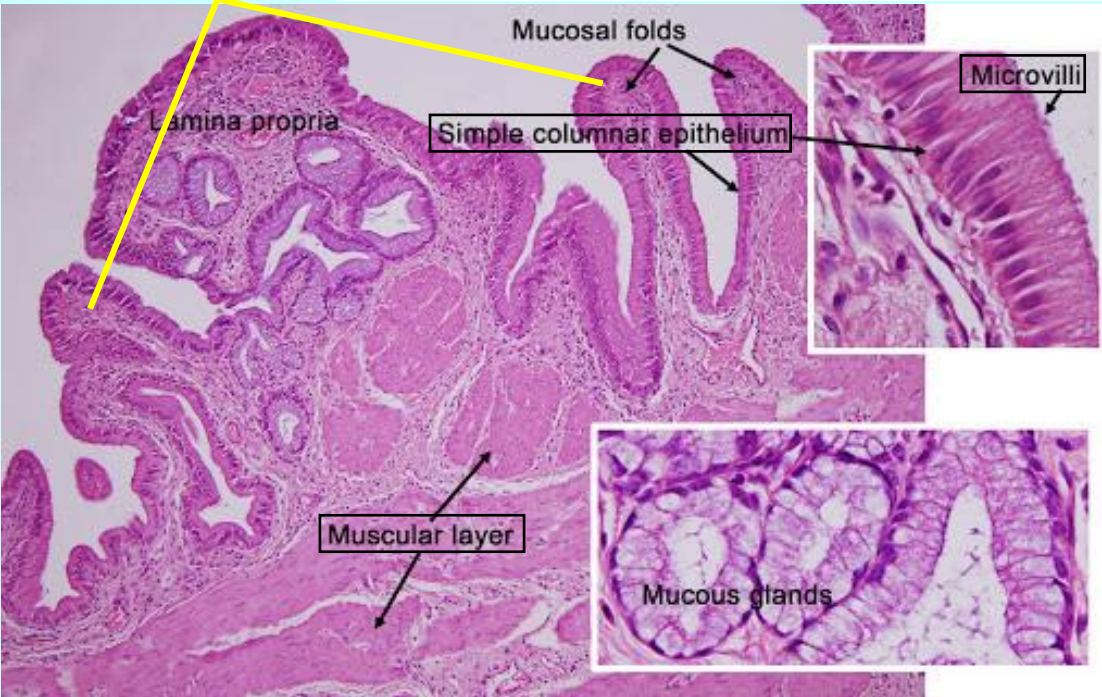
vnějaterní vývody



žlučník (*vesica biliaris*)

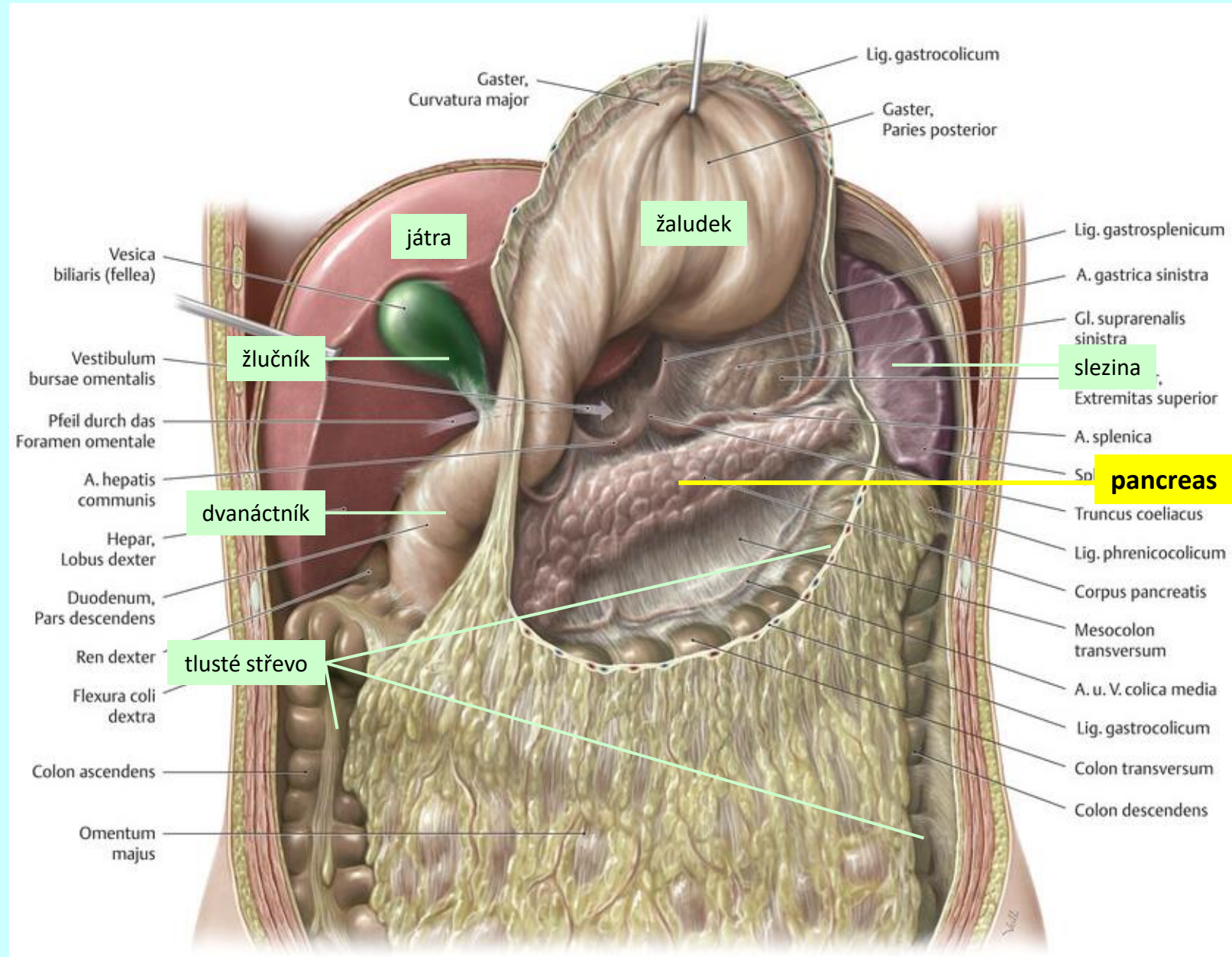


slizniční řasy



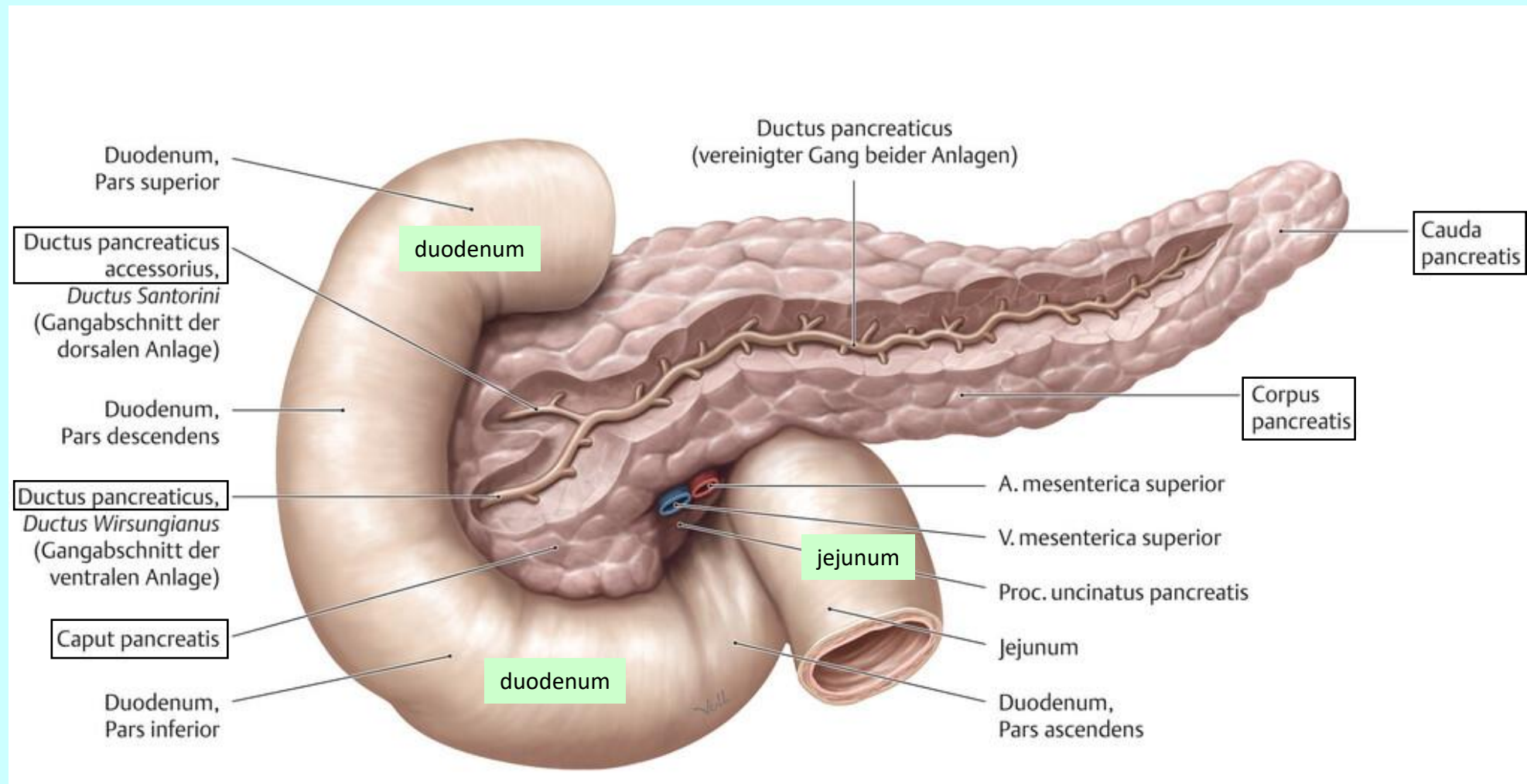
slinivka (*pancreas*)

topografie



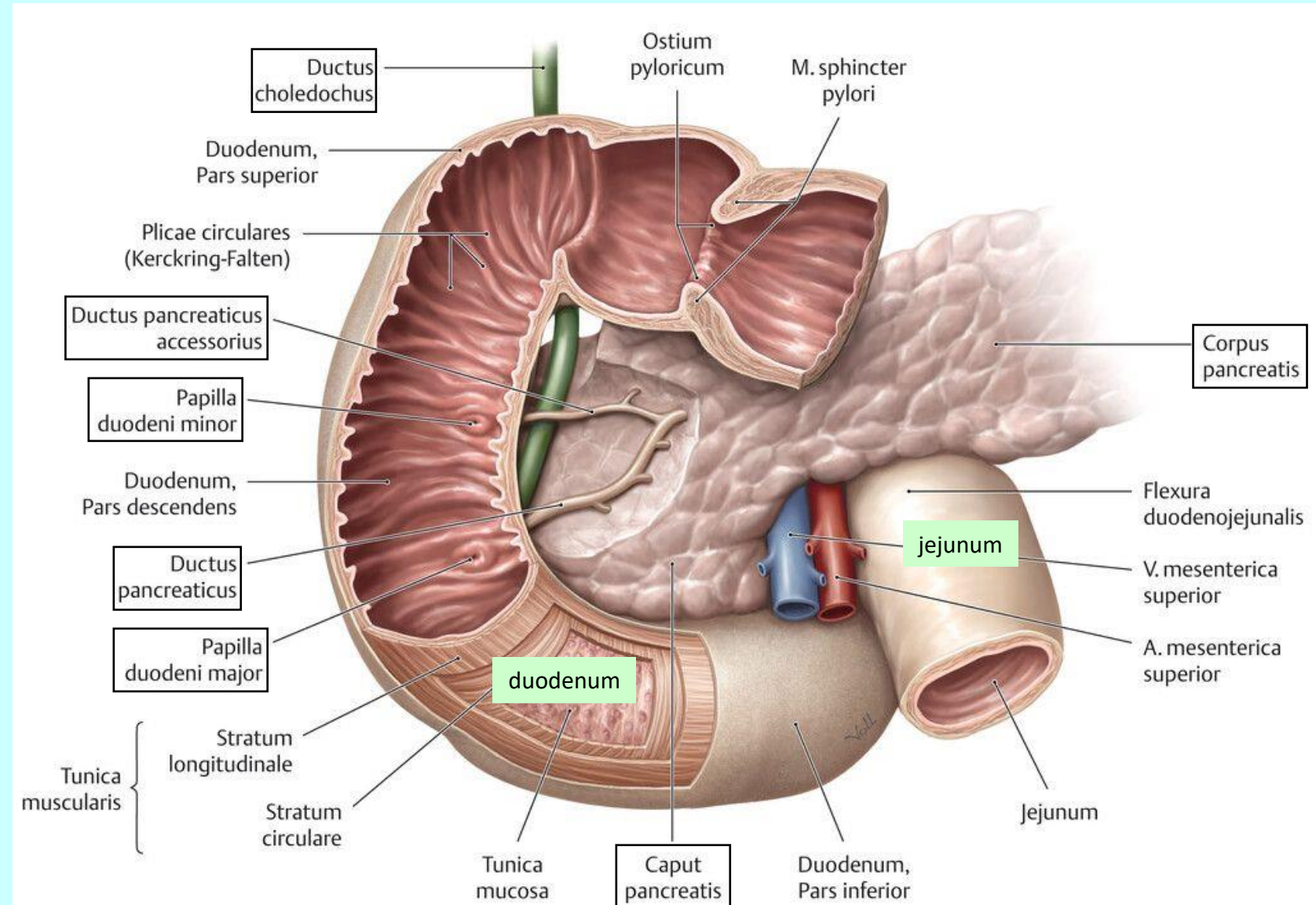
slinivka (*pancreas*)

makroskopická stavba



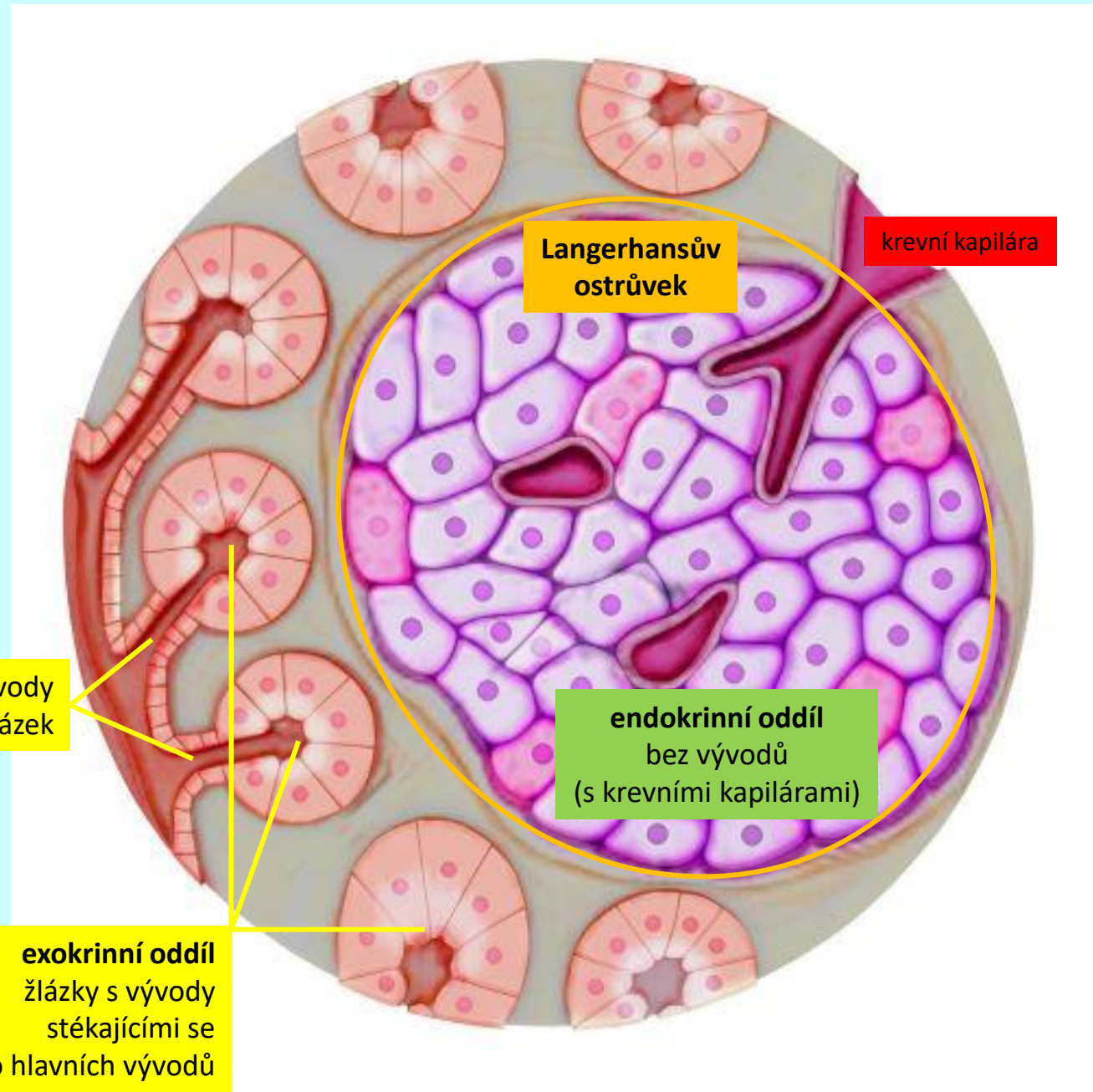
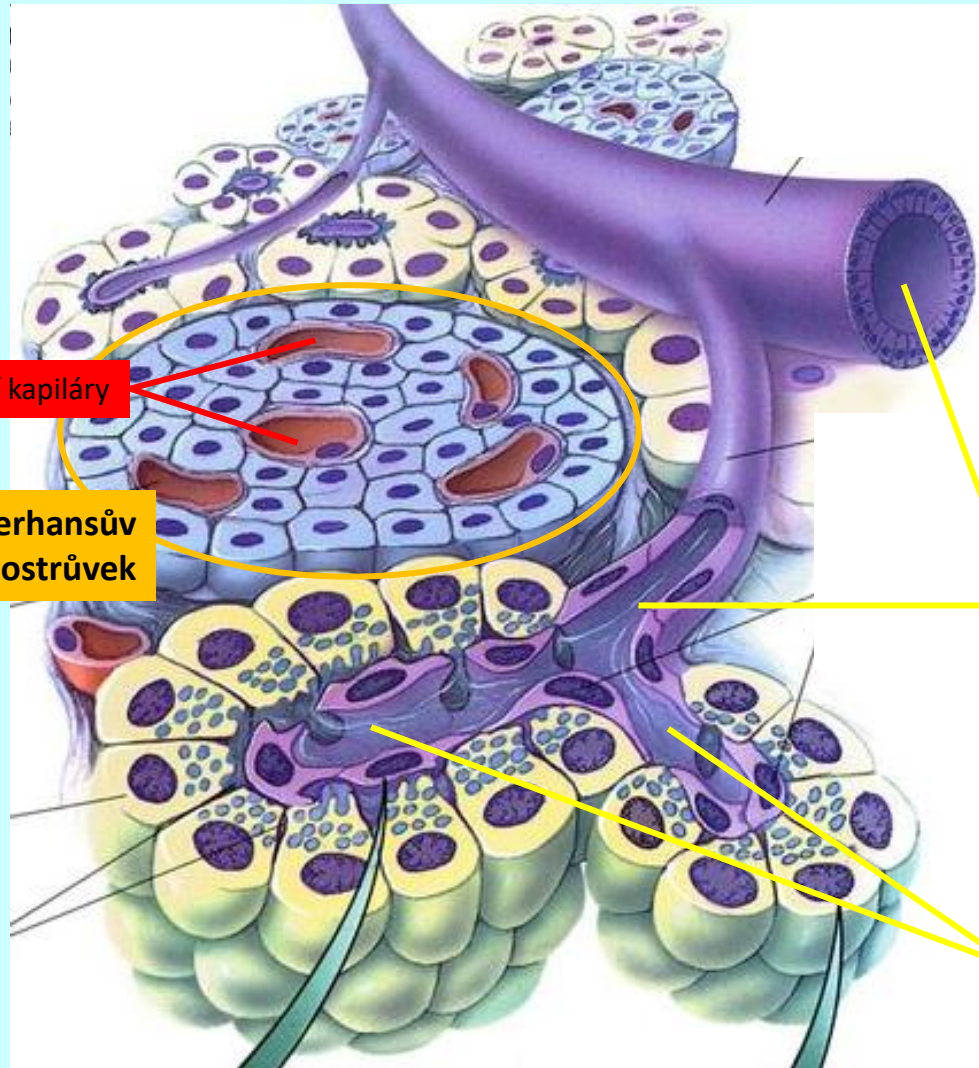
slivivka (*pancreas*)

makroskopická stavba



slinivka (*pancreas*)

histologická stavba



slinivka (*pancreas*)

histologická stavba

