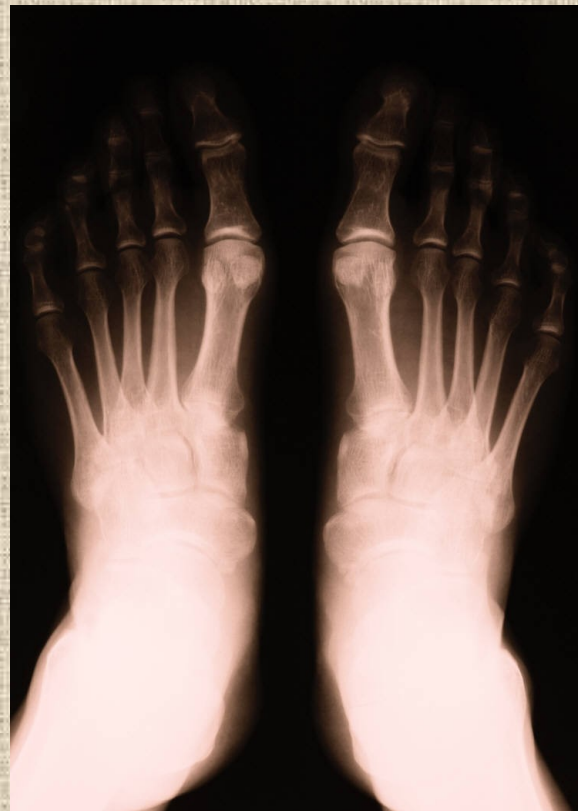

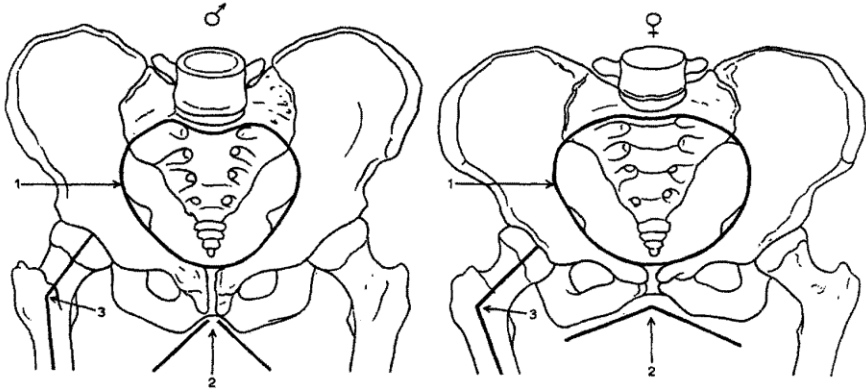
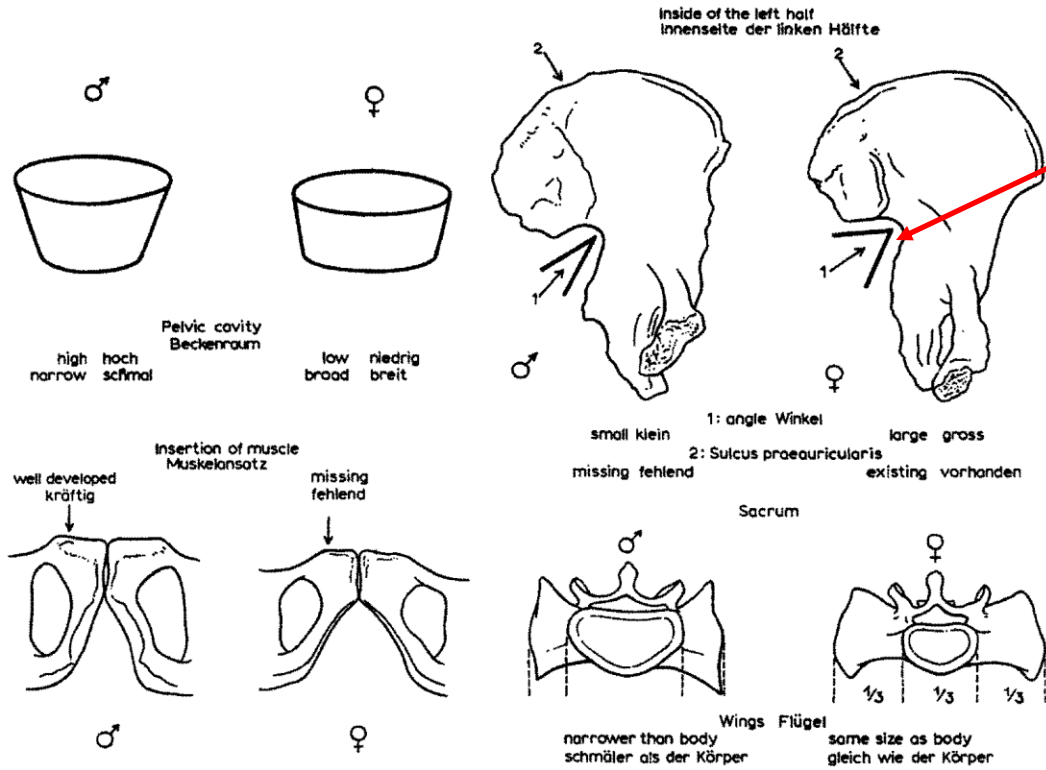
# Základy osteologie

Pánev a kosti zadní končetiny



*Incisura ischiadica major*

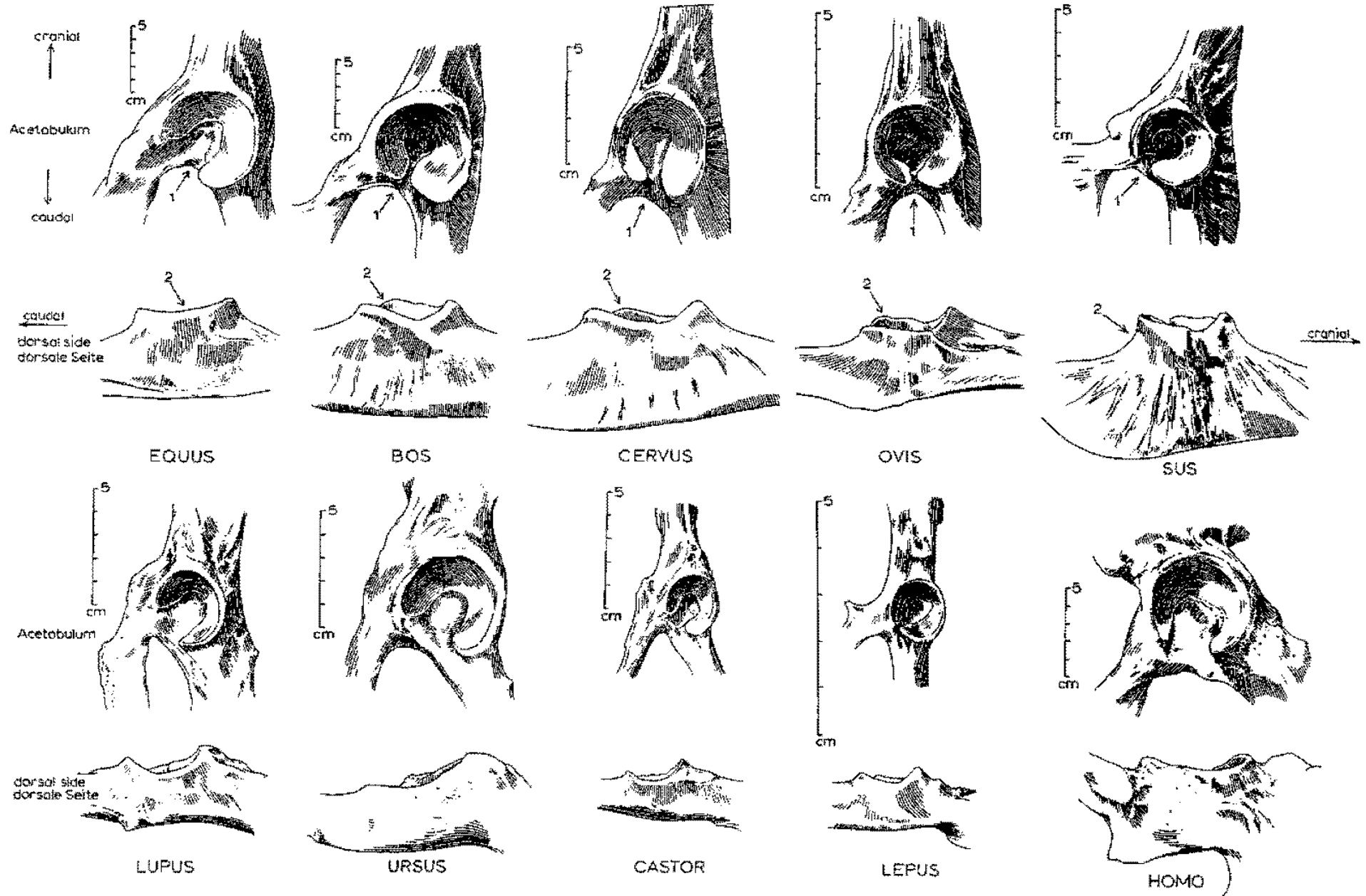
**Pohlavní rozdíly na pánvi člověka**



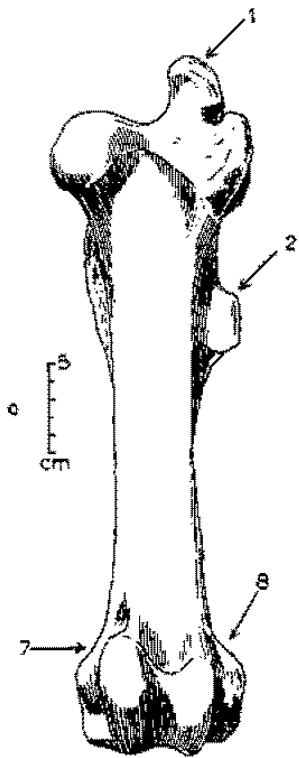
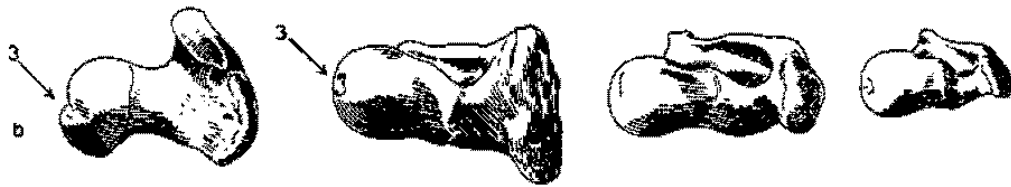
- |                 |              |                |              |
|-----------------|--------------|----------------|--------------|
| 1. heart-shaped | herzförmig   | 1. broad oval  | breit oval   |
| 2. small angle  | Winkel klein | 2. large angle | Winkel gross |
| 3. large angle  | Winkel gross | 3. small angle | Winkel klein |



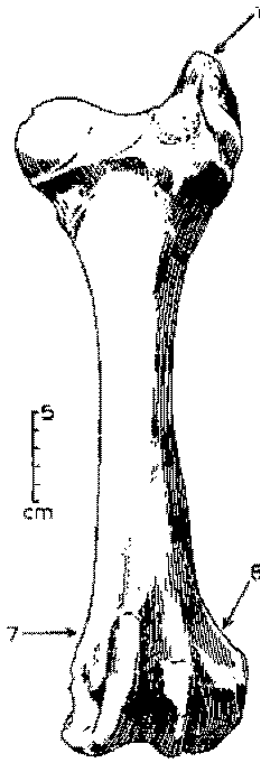
# Pánve



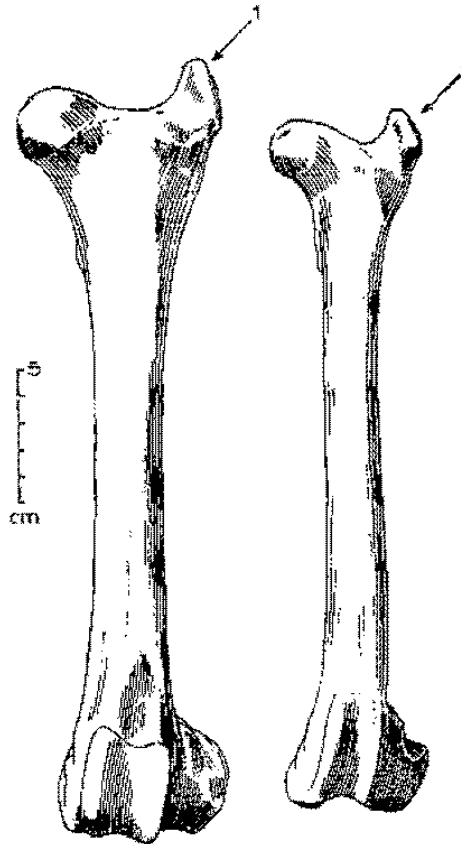
# Stehenní kosti (*femur*)




EQUUS



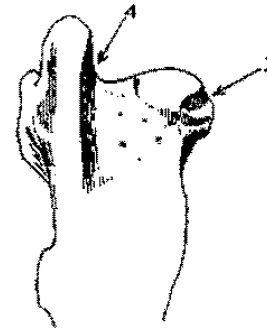
BOS



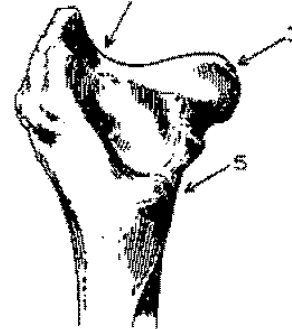
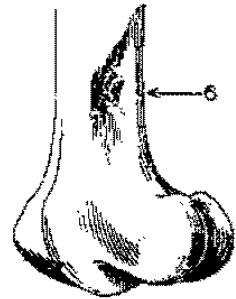
CERVUS



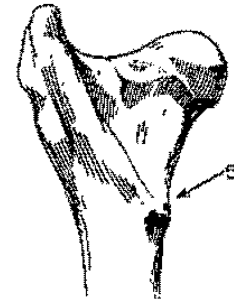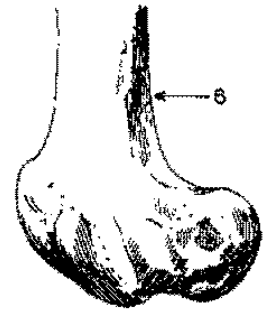
OVIS



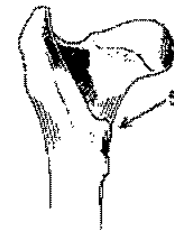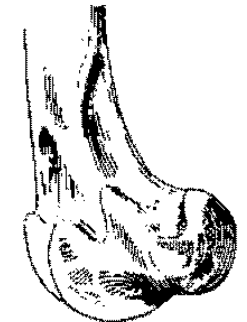
EQUUS



BOS

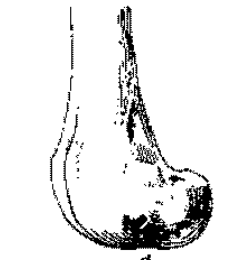


CERVUS



cm

OVIS

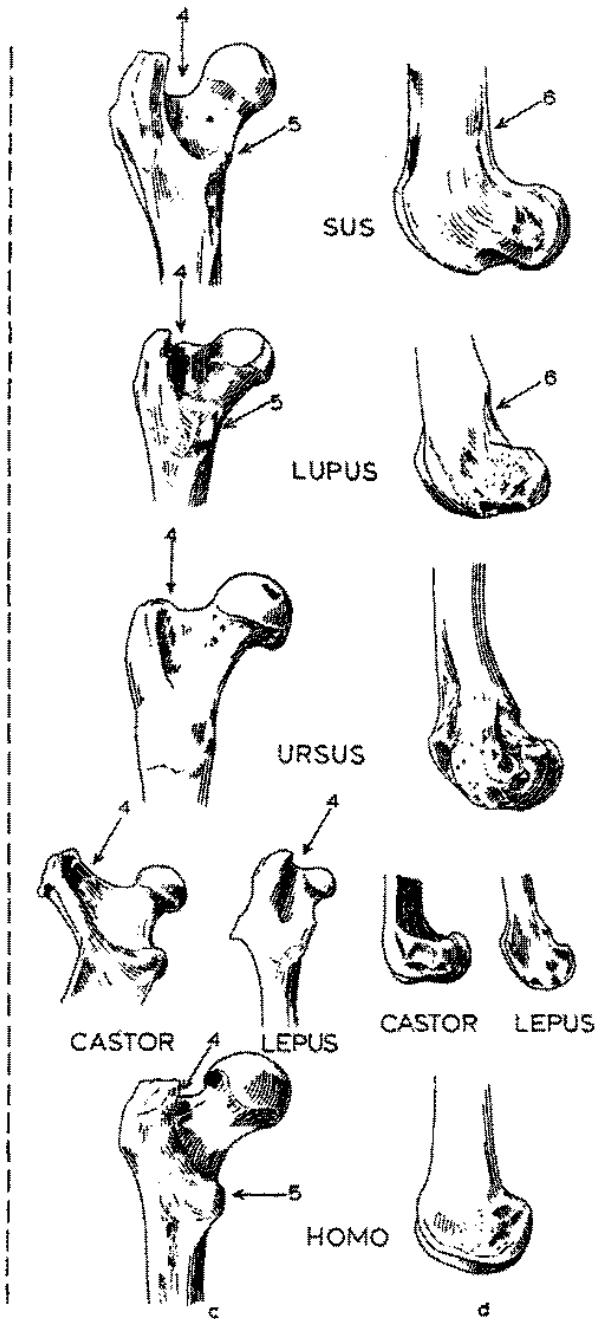
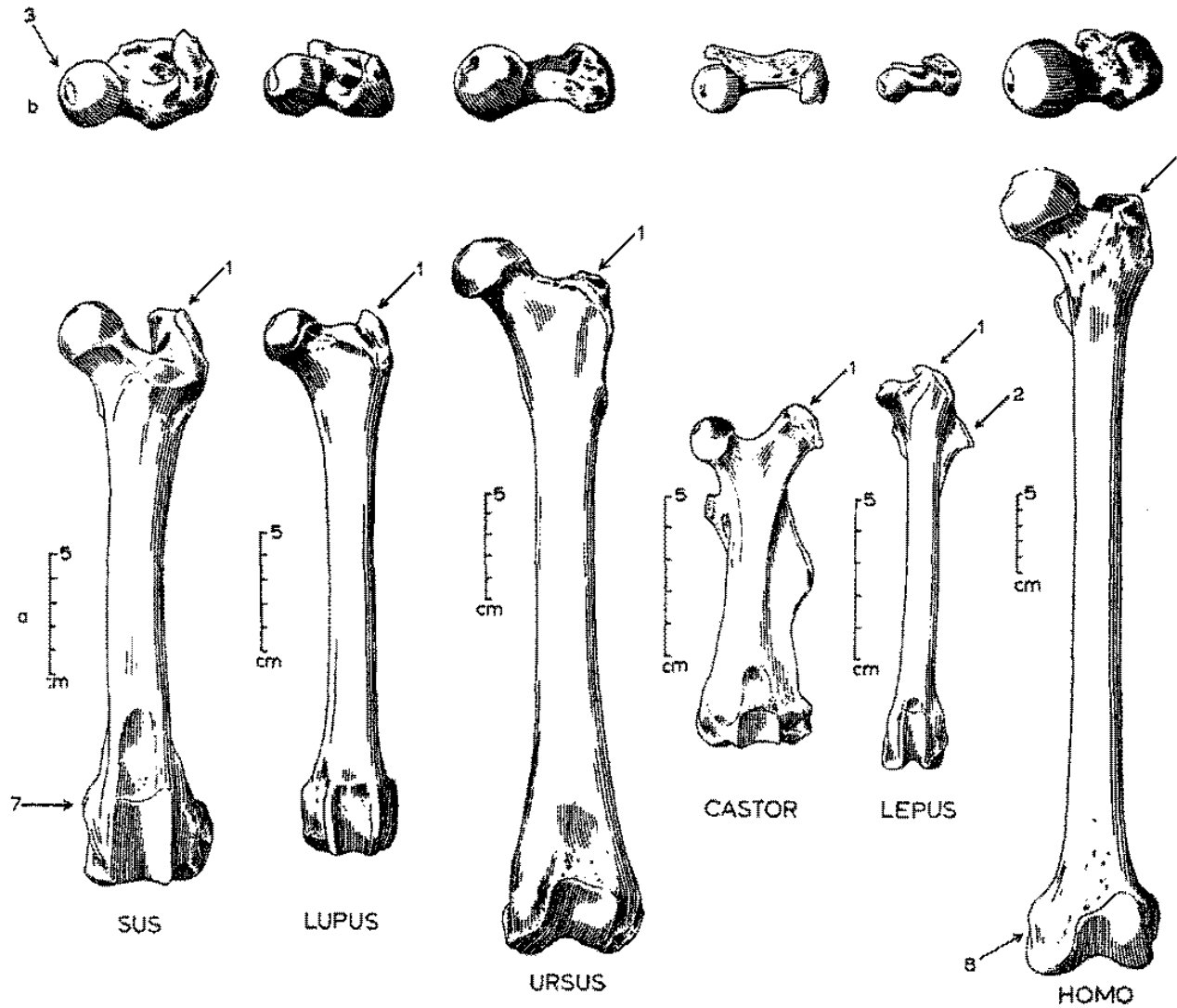


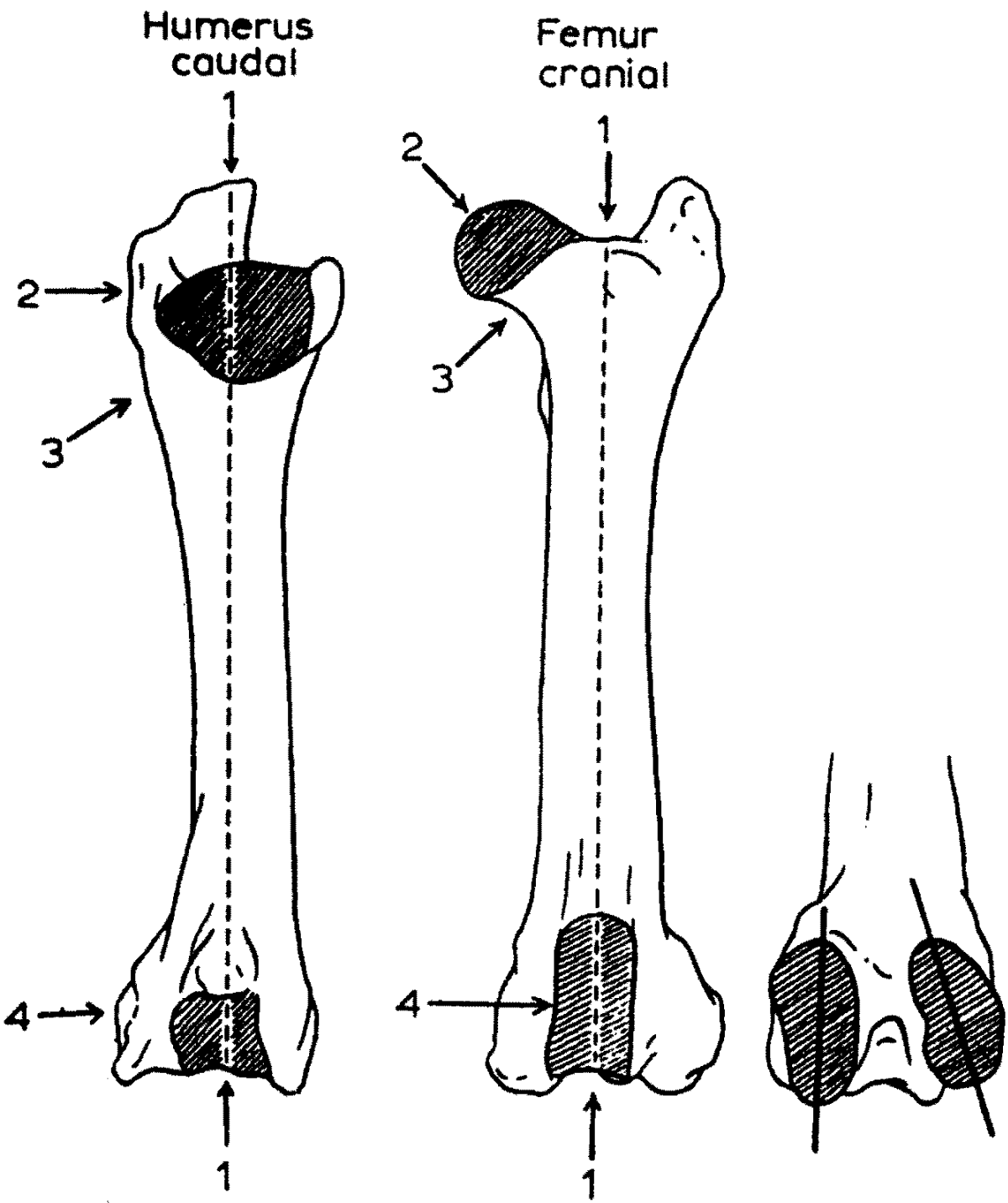
c

d



# Stehenní kosti (femur)

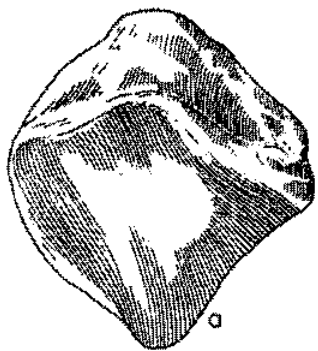




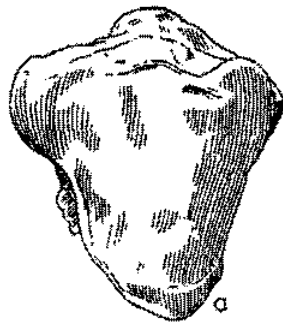
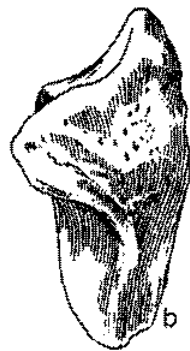
**Jak rozeznat stehenní**  
**a pažní kost**



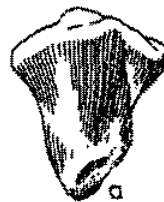

# Češka (*patella*)



EQUUS



BOS



CERVUS



OVIS



SUS




LUPUS



URSUS



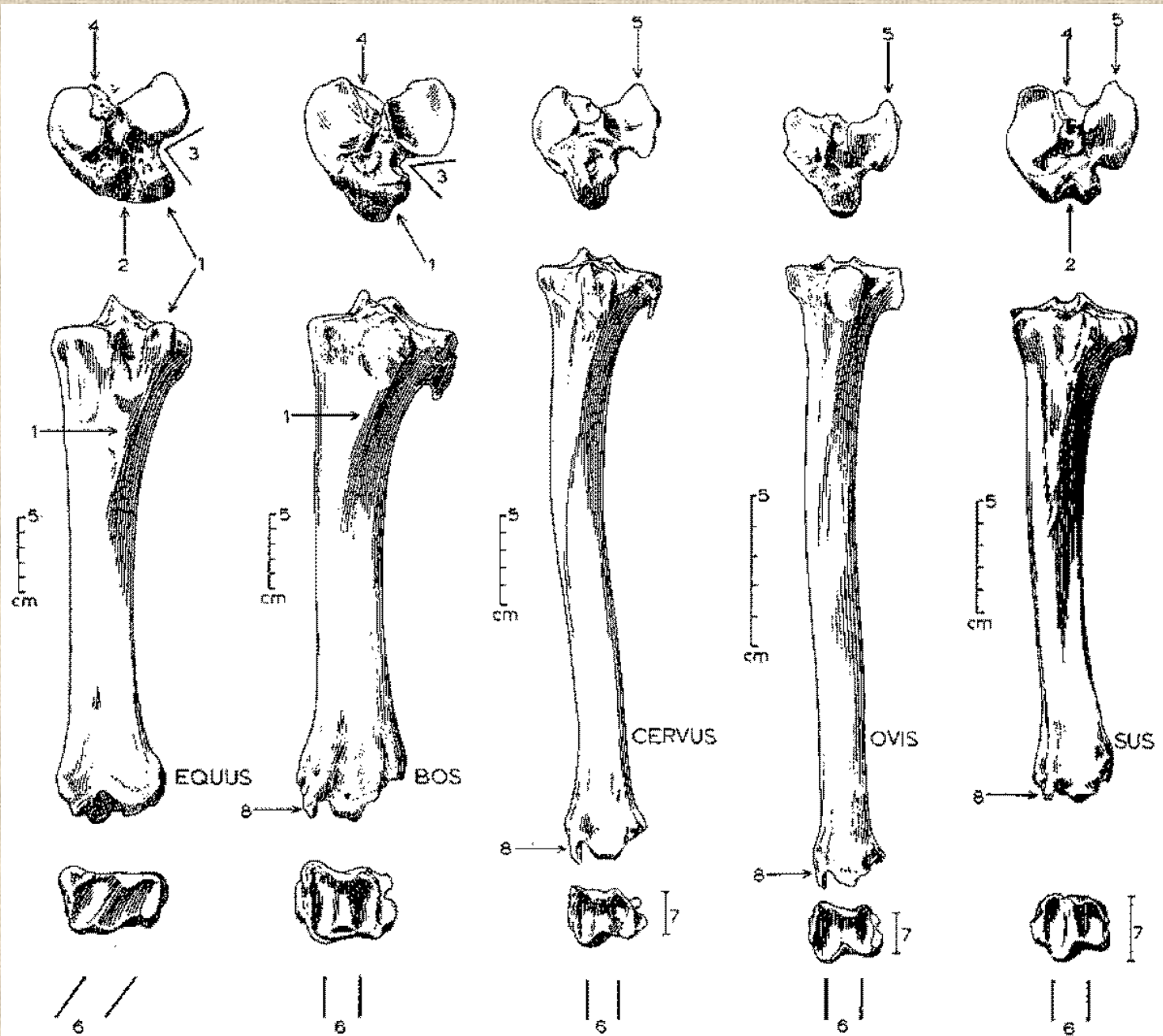
CASTOR



HOMO

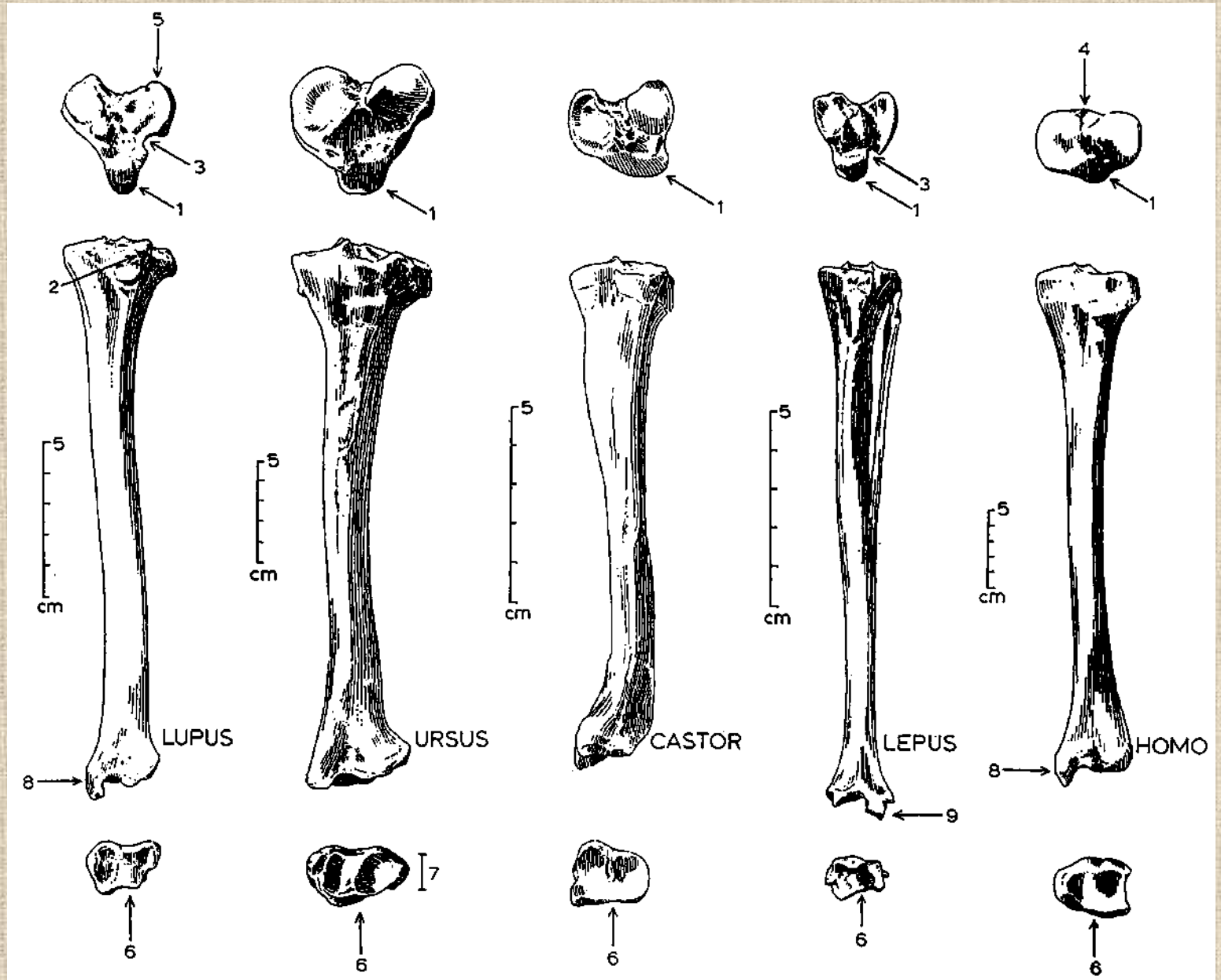


# Holenní kosti (*tibiae*)

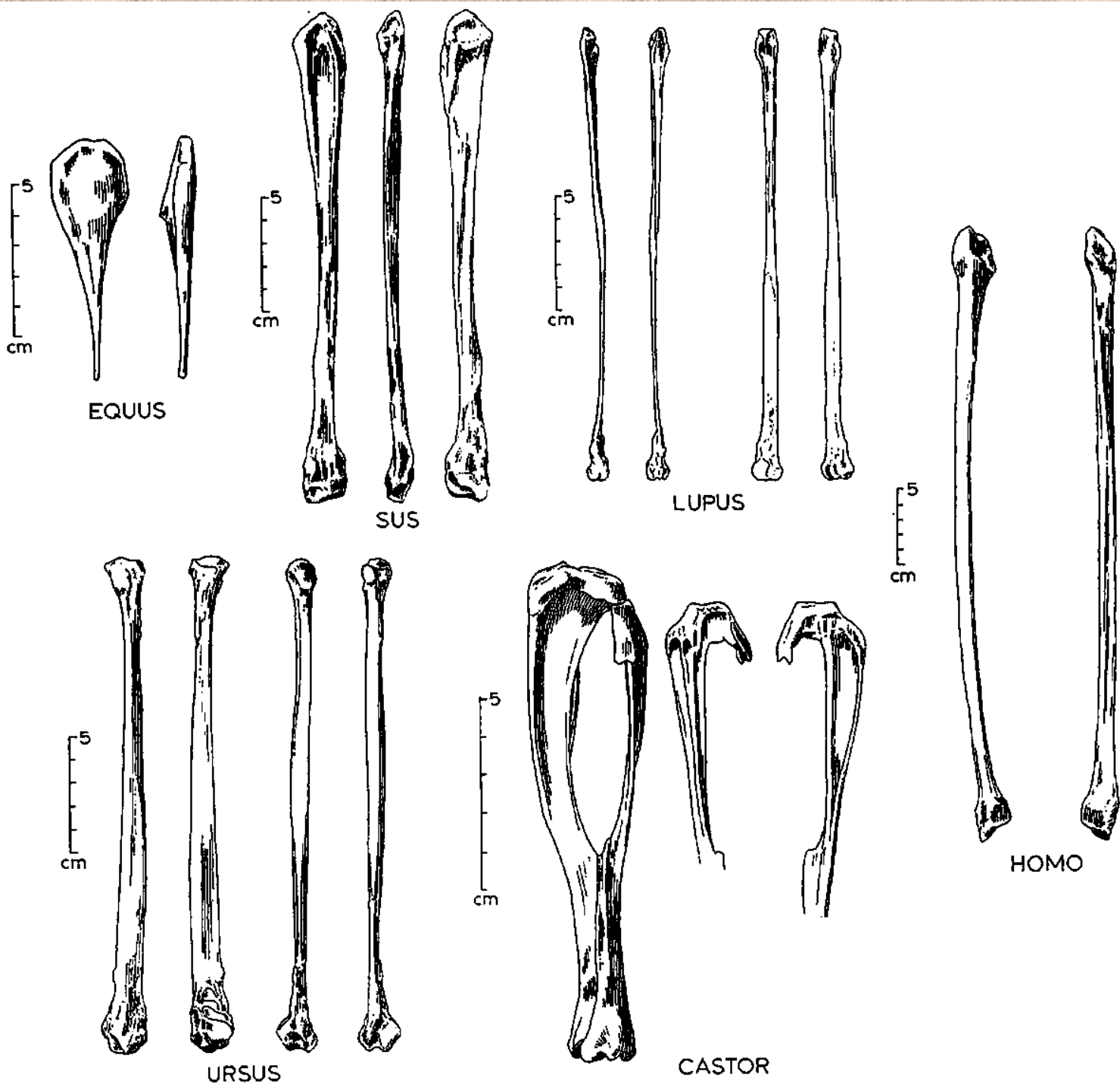




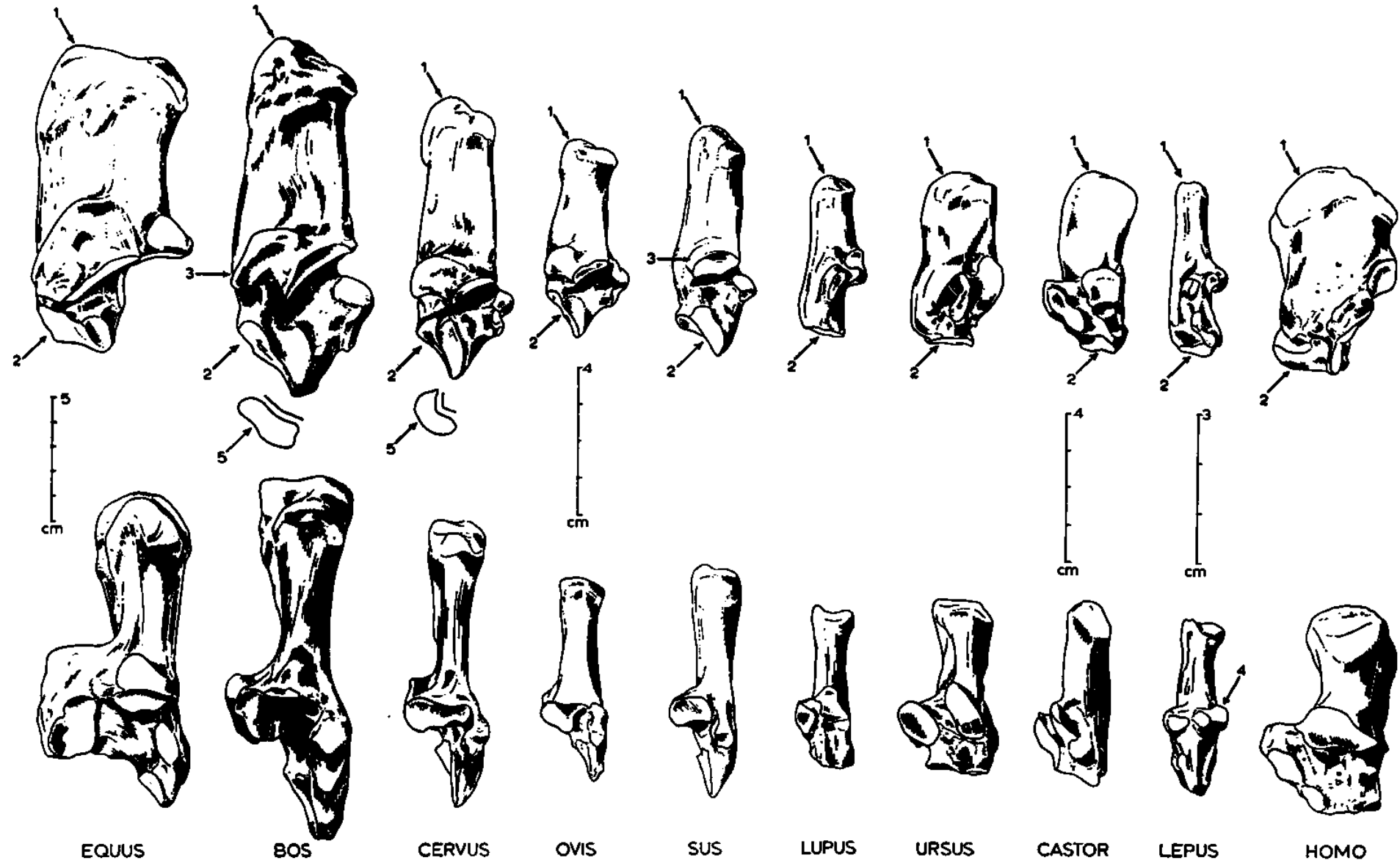
# Holenní kosti (*tibie*)

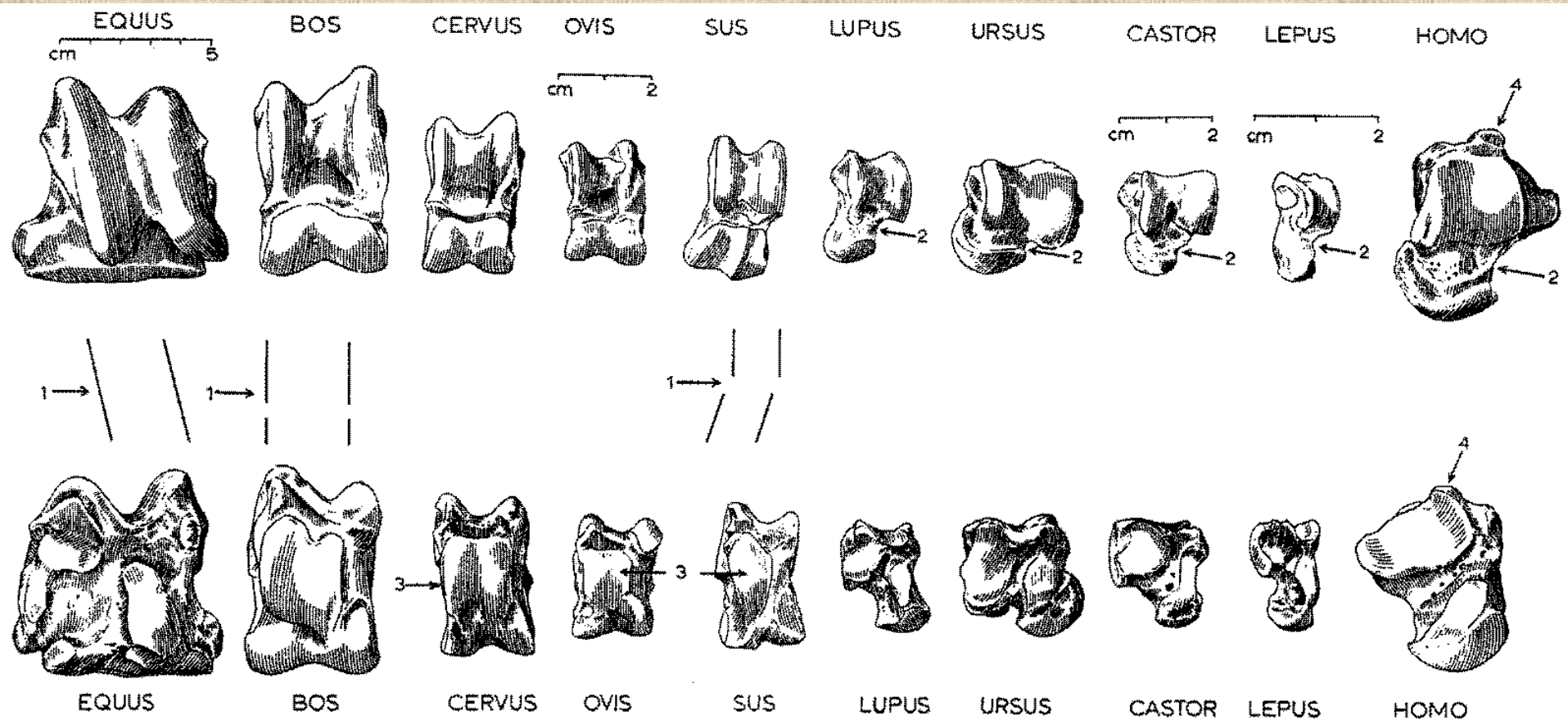


Lýtkové  
kosti  
(fibula)



# Kost patní (*calcaneus*)

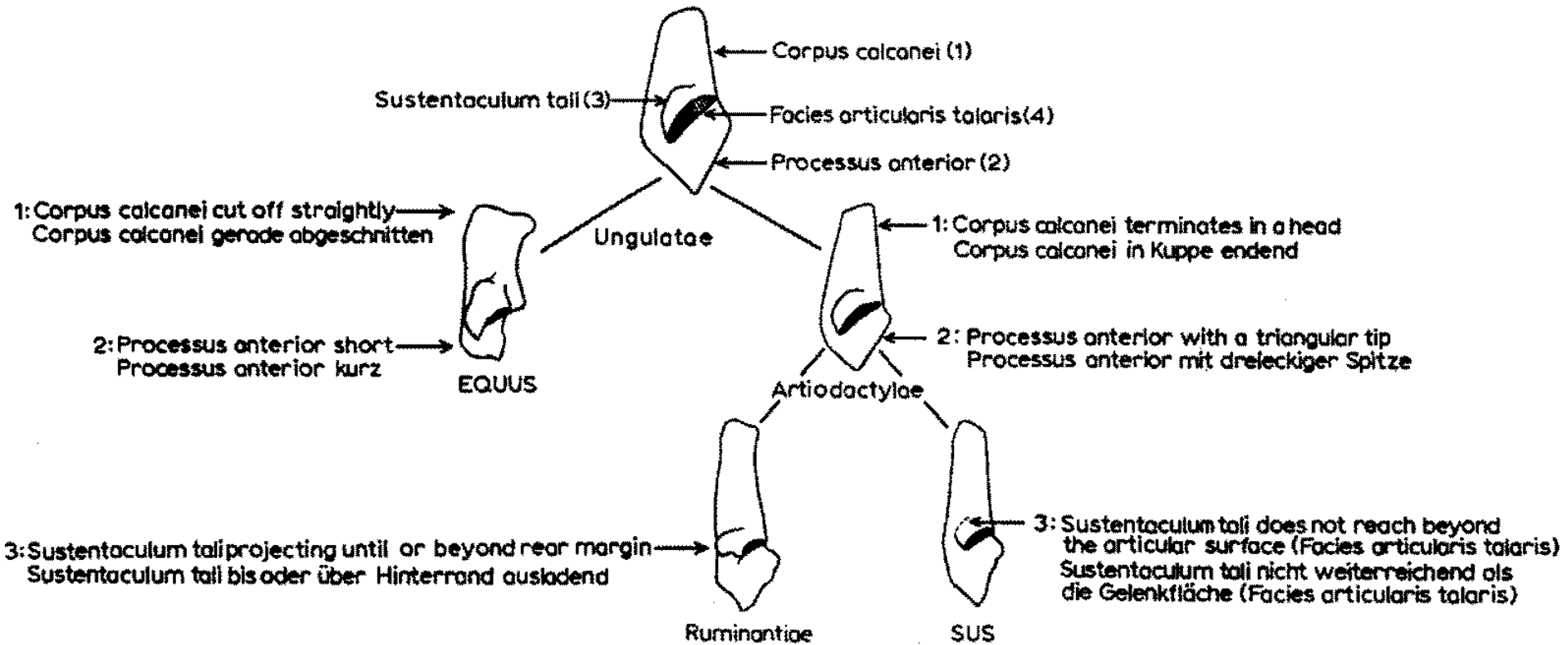




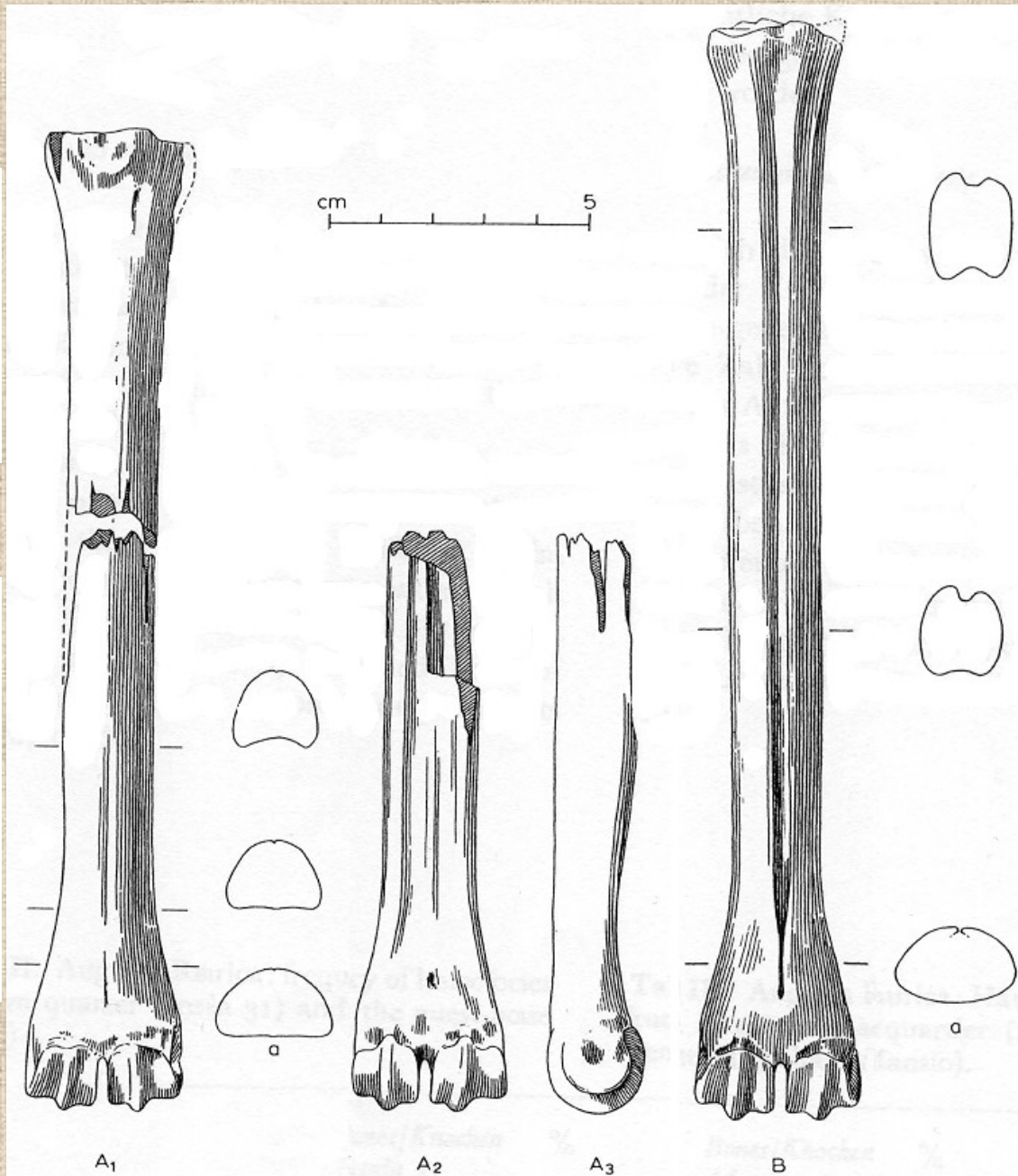
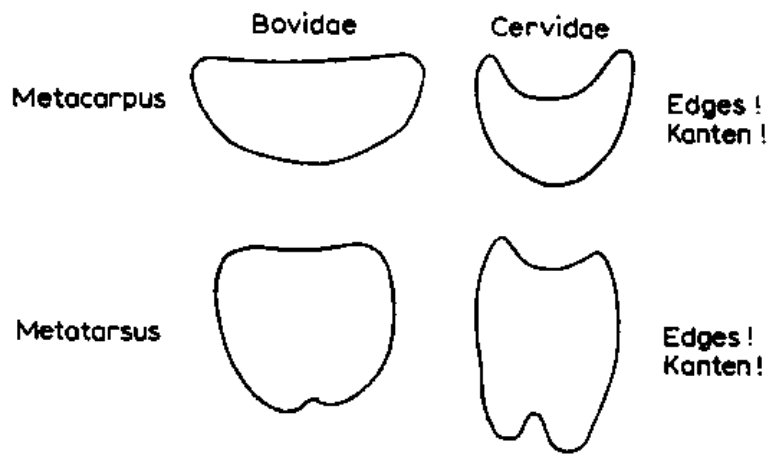
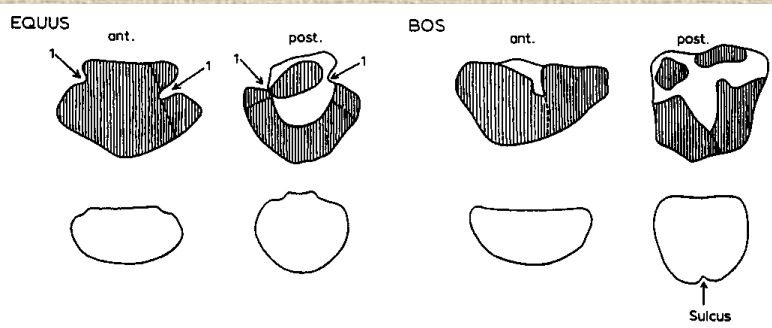
## Kost hlezenní (*astragalus*)



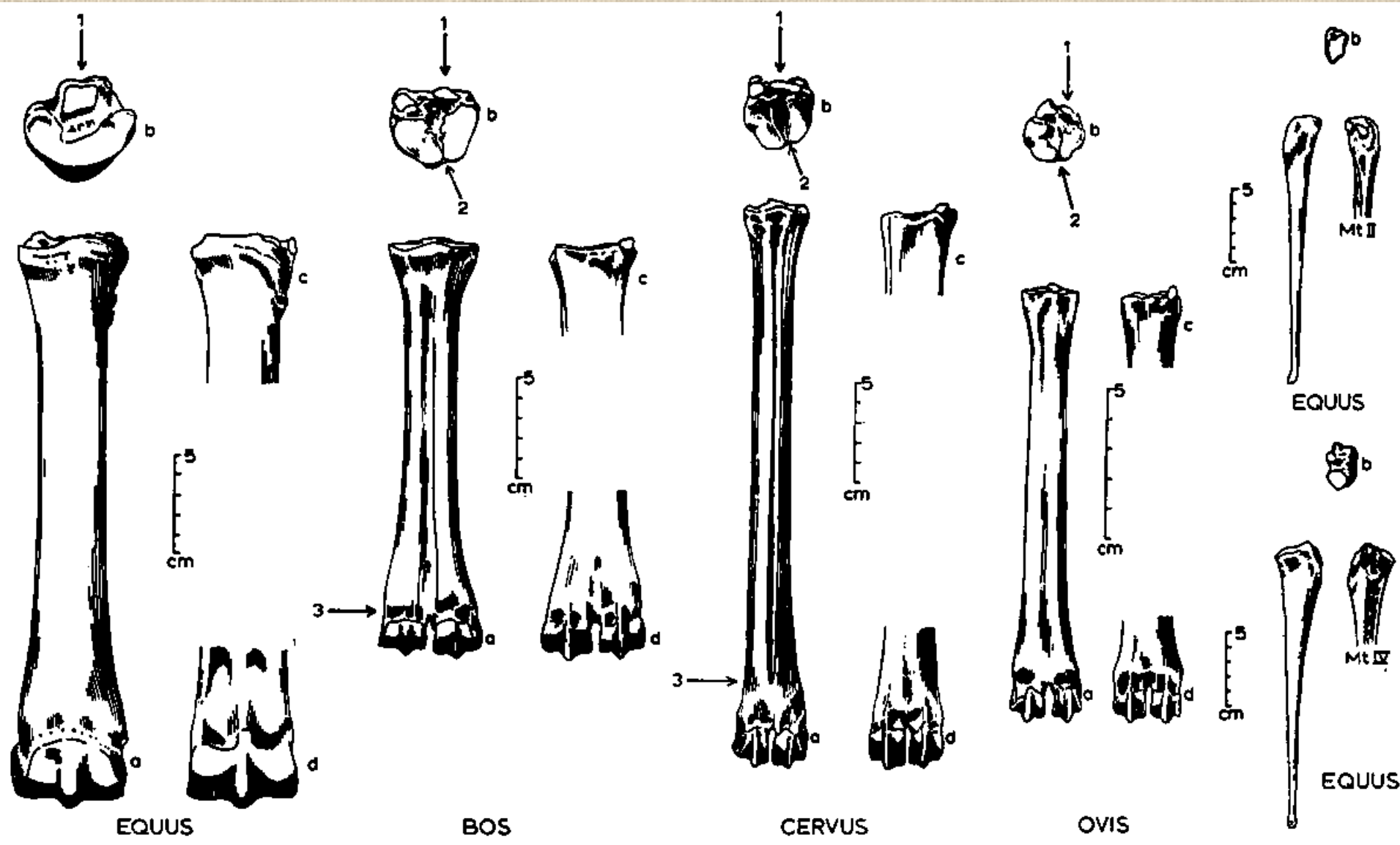
# Rozdíly mezi kostmi patními býložravců a masožravců



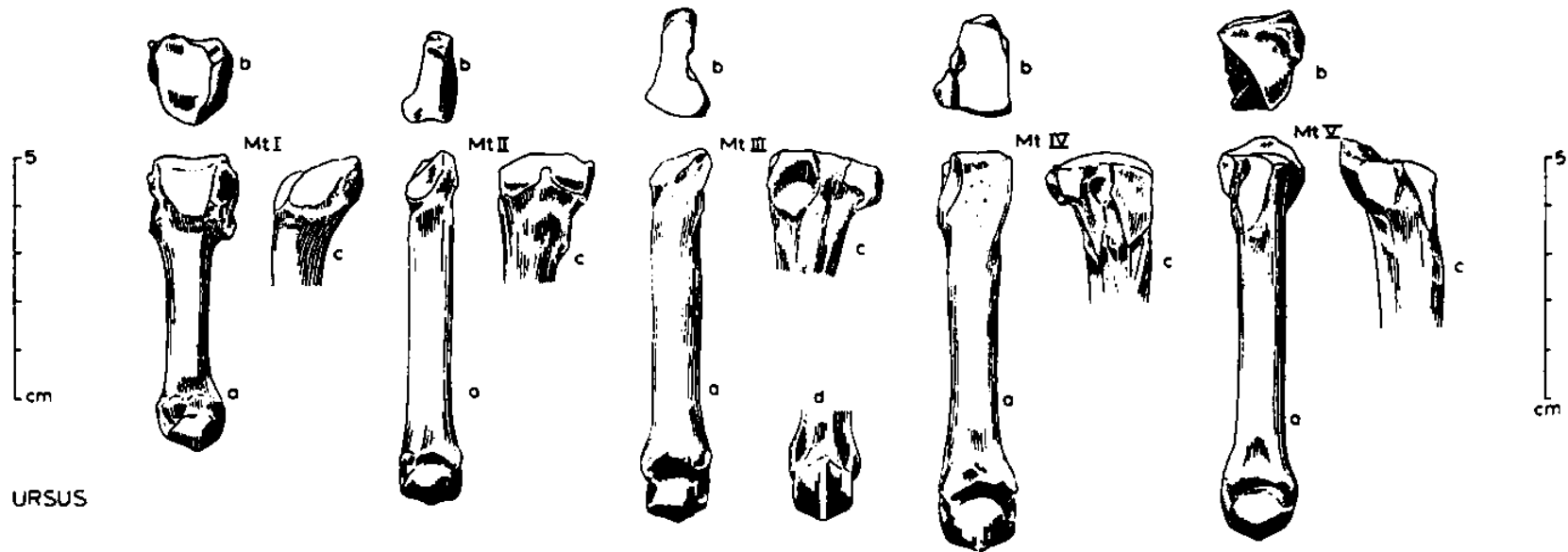
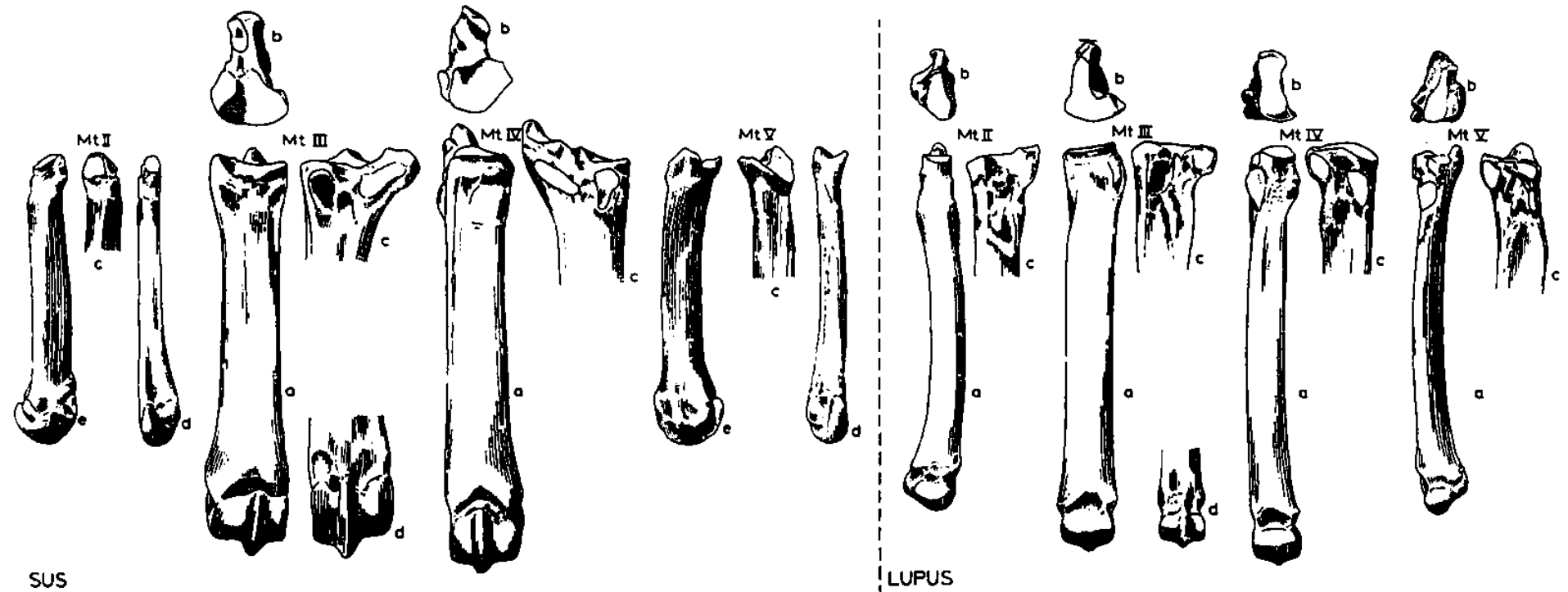
# Rozdíl mezi záprstními a nártními kostmi



# Nártní kost (*metatarsus*)

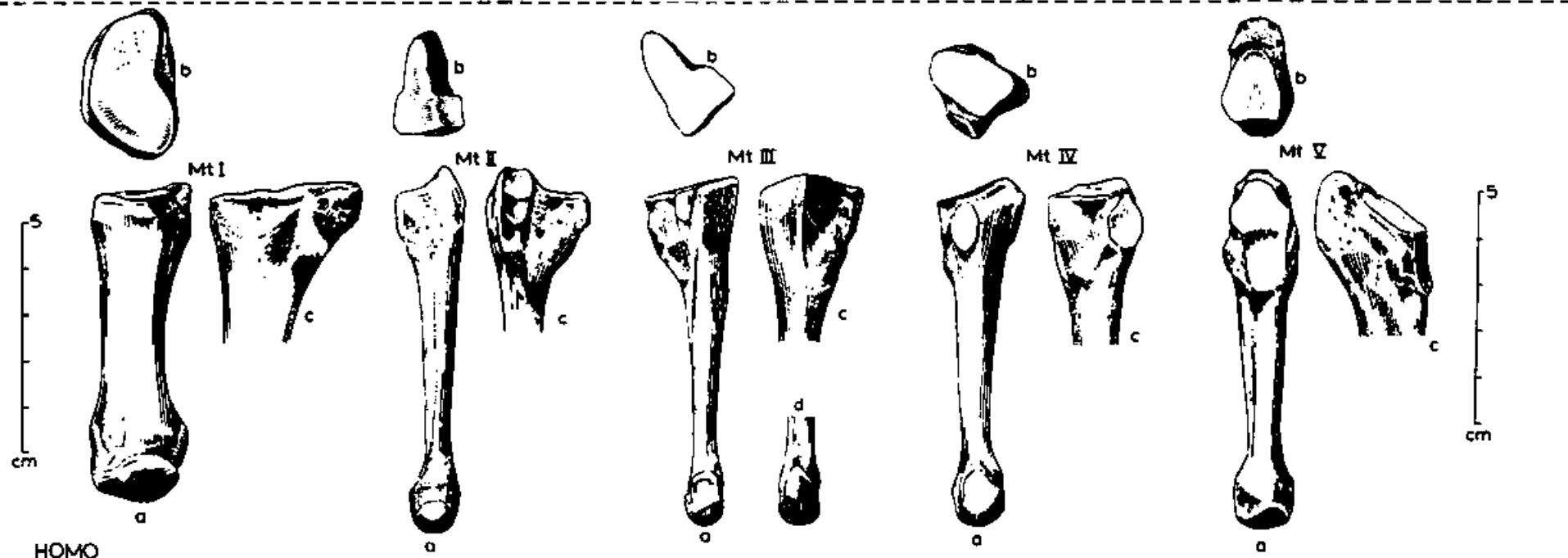
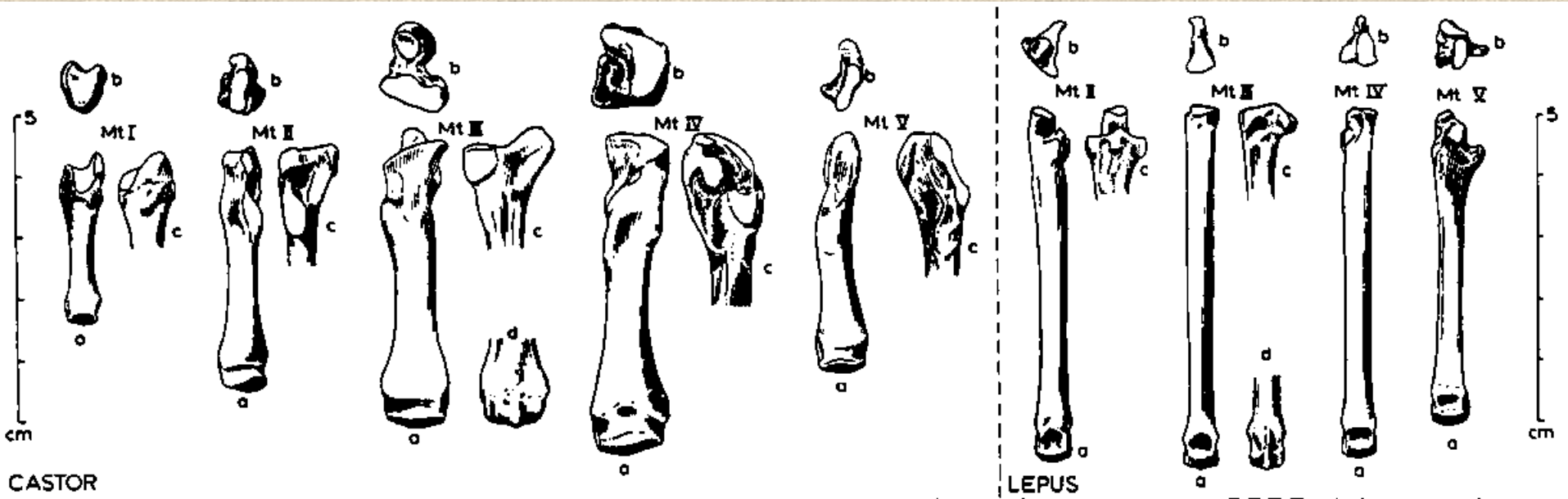


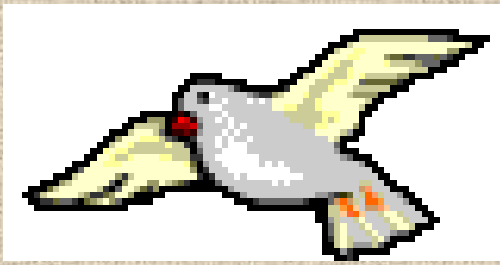
# Nártní kost (*metatarsus*)



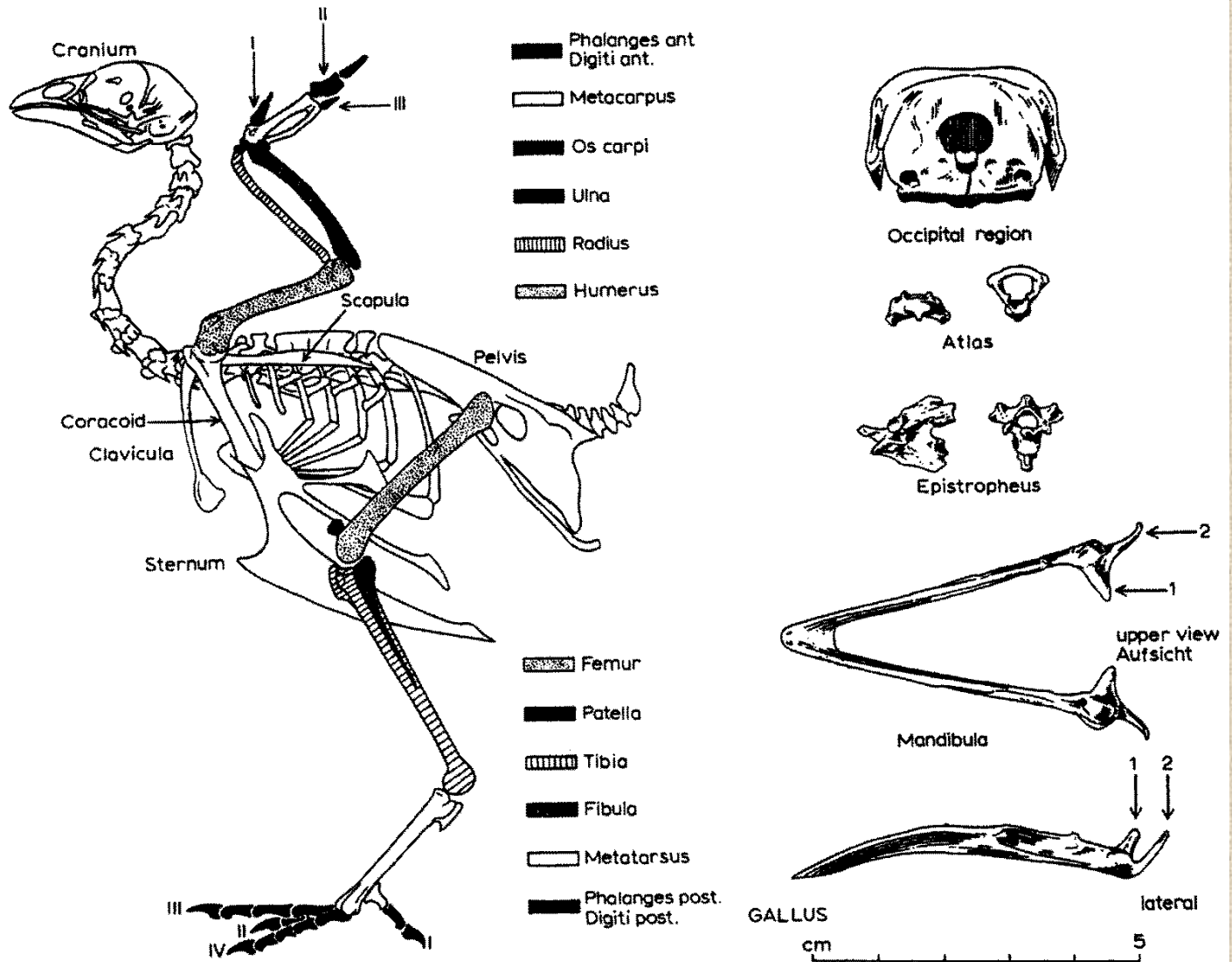


# Nártní kost (*metatarsus*)



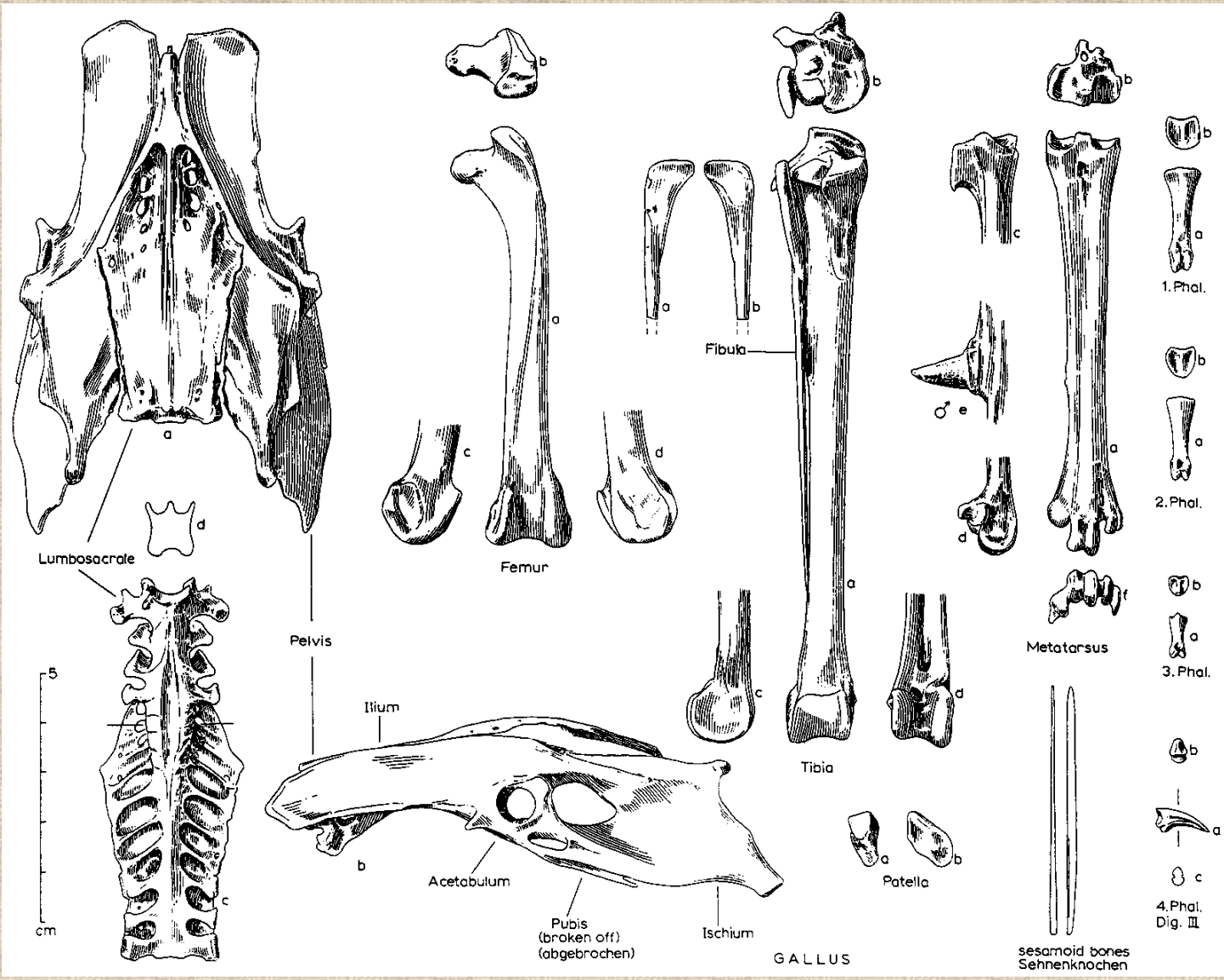


# Ptačí kostra



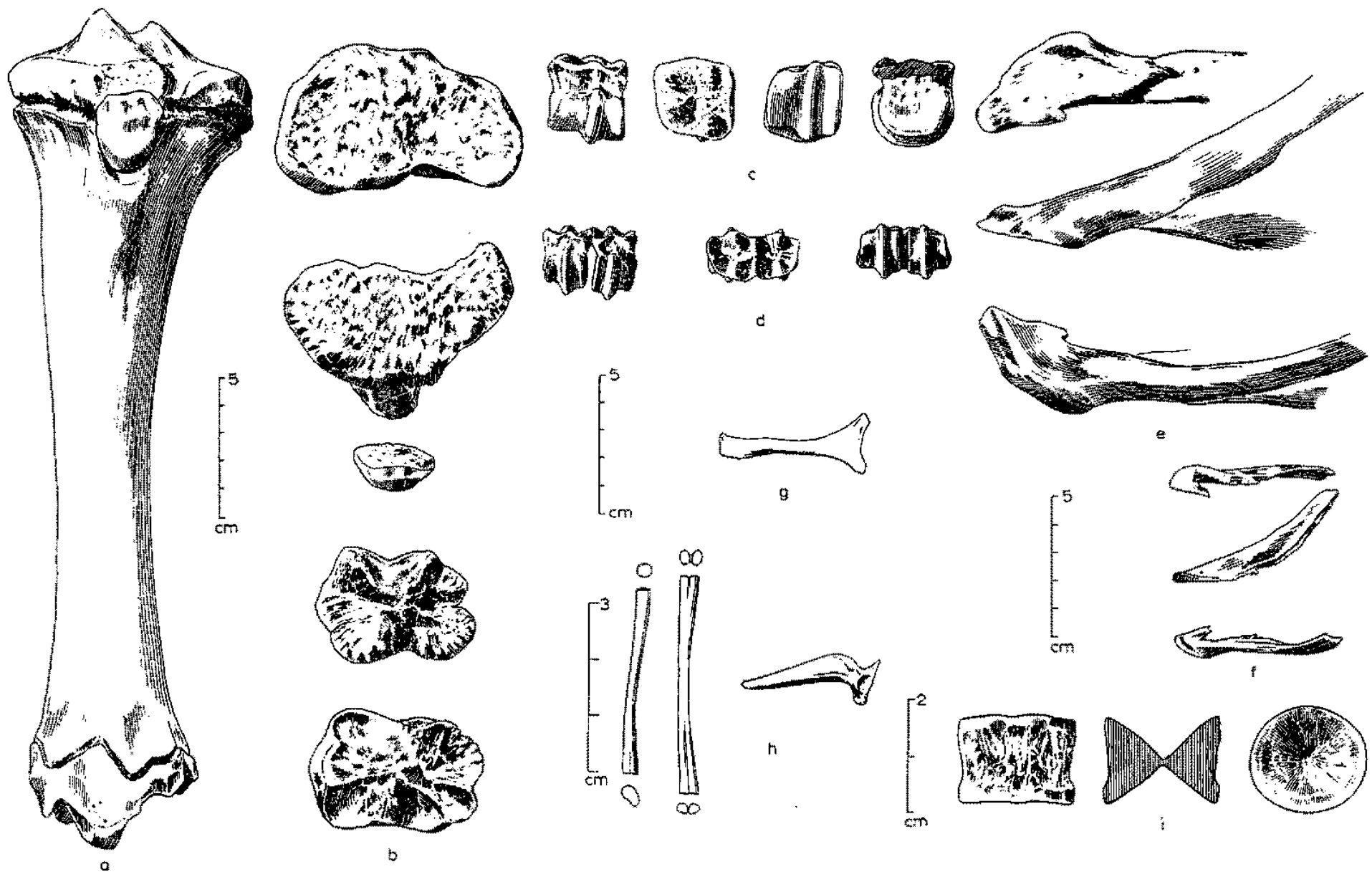


# Kostra zadní končetiny ptáka





# Rozdílná morfologie kostí různých druhů zvířat





**Děkuji za pozornost!**